This is a digital copy of a book that was preserved for generations on library shelves before it was carefully scanned by Google as part of a project to make the world's books discoverable online.

It has survived long enough for the copyright to expire and the book to enter the public domain. A public domain book is one that was never subject to copyright or whose legal copyright term has expired. Whether a book is in the public domain may vary country to country. Public domain books are our gateways to the past, representing a wealth of history, culture and knowledge that's often difficult to discover.

Marks, notations and other marginalia present in the original volume will appear in this file - a reminder of this book's long journey from the publisher to a library and finally to you.

Usage guidelines

Google is proud to partner with libraries to digitize public domain materials and make them widely accessible. Public domain books belong to the public and we are merely their custodians. Nevertheless, this work is expensive, so in order to keep providing this resource, we have taken steps to prevent abuse by commercial parties, including placing technical restrictions on automated querying.

We also ask that you:

+ *Make non-commercial use of the files* We designed Google Book Search for use by individuals, and we request that you use these files for personal, non-commercial purposes.

+ *Refrain from automated querying* Do not send automated queries of any sort to Google's system: If you are conducting research on machine translation, optical character recognition or other areas where access to a large amount of text is helpful, please contact us. We encourage the use of public domain materials for these purposes and may be able to help.

+ *Maintain attribution* The Google "watermark" you see on each file is essential for informing people about this project and helping them find additional materials through Google Book Search. Please do not remove it.

+ *Keep it legal* Whatever your use, remember that you are responsible for ensuring that what you are doing is legal. Do not assume that just because we believe a book is in the public domain for users in the United States, that the work is also in the public domain for users in other countries. Whether a book is still in copyright varies from country to country, and we can't offer guidance on whether any specific use of any specific book is allowed. Please do not assume that a book's appearance in Google Book Search means it can be used in any manner anywhere in the world. Copyright infringement liability can be quite severe.

About Google Book Search

Google's mission is to organize the world's information and to make it universally accessible and useful. Google Book Search helps readers discover the world's books while helping authors and publishers reach new audiences. You can search through the full text of this book on the web at `http://books.google.com/`

B 3 9015 00212 239 1
University of Michigan - BUHR

Digitized by Google



Digitized by Google

Med. Period
610.5
P3
S7
L8t

Digitized by Google

Digitized by Google

TRANSACTIONS

L1263-4

OF THE

PATHOLOGICAL SOCIETY OF LONDON.

VOLUME THE FORTIETH.

COMPRISING THE REPORT OF THE PROCEEDINGS FOR THE SESSION 1888-89.

LONDON:
SMITH, ELDER & CO., 15, WATERLOO PLACE.
1889.

Digitized by Google

THE present publication, being the Fortieth Volume of Transactions, constitutes the Forty-third published Annual Report of the Pathological Society's Proceedings.

The COUNCIL think it right to repeat that the exhibitors are alone responsible for the descriptions given of the Specimens exhibited by them, the only change made in the Reports furnished by the authors being such verbal alterations as were absolutely necessary.

20, HANOVER SQUARE, W.
October, 1889.

Digitized by Google

TABLE OF CONTENTS

OF VOLUME XL.

	PAGE
List of Presidents of the Society	IV
List of Officers and Members for 1889	V—XXXVII
Annual Report of Council for 1888-89	XXXIX
List of Specimens Exhibited during the Session 1888-89	XLIII
List of Specimens Reported on by the Committee on Morbid Growths	LV
List of Plates	LVII
List of Woodcuts	LIX
Address by the President	1
Diseases, etc., of the Nervous System	9
Diseases, etc., of the Organs of Respiration	34
Diseases, etc., of the Organs of Circulation	57
Diseases, etc., of the Organs of Digestion	76
Diseases, etc., of the Genito-Urinary Organs	144
Diseases, etc., of the Osseous System	229
Morbid Growths and Tumours	275
Diseases, etc., of the Ductless Glands	299
Diseases of the Skin	303
Special Communications	310
Miscellaneous Specimens	385
Diseases, etc., of the Lower Animals	449
Index	465

Digitized by Google

Presidents of the Society.

ELECTED	
1846	CHARLES J. B. WILLIAMS, M.D., F.R.S.
1848	CHARLES ASTON KEY.
1850	PETER MERE LATHAM, M.D.
1852	CÆSAR H. HAWKINS, F.R.S.
1853	BENJAMIN GUY BABINGTON, M.D., F.R.S.
1855	JAMES MONCRIEFF ARNOTT, F.R.S.
1857	Sir THOMAS WATSON, Bart., M.D., F.R.S.
1859	Sir WILLIAM FERGUSSON, Bart., F.R.S.
1861	JAMES COPLAND, M.D., F.R.S.
1863	Sir PRESCOTT G. HEWETT, Bart., F.R.S.
1865	THOMAS BEVILL PEACOCK, M.D.
1867	Sir JOHN SIMON, K.C.B., D.C.L., F.R.S.
1869	RICHARD QUAIN, M.D., F.R.S.
1871	JOHN HILTON, F.R.S.
1873	Sir WILLIAM JENNER, Bart., M.D., K.C.B., D.C.L., F.R.S.
1875	GEORGE D. POLLOCK.
1877	CHARLES MURCHISON, M.D., LL.D., F.R.S.
1879	JONATHAN HUTCHINSON, F.R.S.
1881	SAMUEL WILKS, M.D., F.R.S.
1883	JOHN WHITAKER HULKE, F.R.S.
1885	JOHN SYER BRISTOWE, M.D., F.R.S.
1887	Sir JAMES PAGET, Bart., D.C.L., LL.D., F.R.S.
1889	WILLIAM HOWSHIP DICKINSON, M.D.

Digitized by Google

OFFICERS AND COUNCIL

OF THE

Pathological Society of London,

ELECTED AT

THE GENERAL MEETING, JANUARY 15TH, 1889.

President.

W. H. DICKINSON, M.D.

Vice-Presidents.

JAMES ANDREW, M.D.
J. HUGHLINGS JACKSON, M.D., F.R.S.
JOSEPH FRANK PAYNE, M.D.
HENRY G. SUTTON, M.D.
RICHARD BARWELL.
MARCUS BECK, M.S.
F. HOWARD MARSH.
HENRY MORRIS, M.B.

Treasurer.

WILLIAM CAYLEY, M.D.

Council.

CHARLES EDWARD BEEVOR, M.B.
HENRY RADCLIFFE CROCKER, M.D.
SIDNEY COUPLAND, M.D.
WILLIAM EWART, M.D.
PERCY KIDD, M.D.
GEORGE THIN, M.D.
EDWARD EMANUEL KLEIN, M.D., F.R.S.
STEPHEN MACKENZIE, M.D.
JOSEPH ARDERNE ORMEROD, M.D.
WILLIAM HALE WHITE, M.D.
WILLIAM ANDERSON.
JONATHAN HUTCHINSON, JUN.
HENRY TRENTHAM BUTLIN.
VICTOR HORSLEY, B.S., F.R.S
GEORGE HENRY MAKINS.
HERBERT WILLIAM PAGE.
BERNARD PITTS, M.B.
A. QUARRY SILCOCK, M.D.
JOHN BLAND SUTTON.
FREDERICK TREVES.

Honorary Secretaries.

SAMUEL WEST, M.D.
RICKMAN JOHN GODLEE, M.S.

Trustees.

RICHARD QUAIN, M.D., F.R.S.
GEORGE D. POLLOCK
SAMUEL WILKS, M.D., F.R.S.

Digitized by Google

Members of the Morbid Growths Committee.

NORMAN MOORE, M.D.
GEORGE NEWTON PITT, M.D.
F. CHARLEWOOD TURNER, M.D.
SEYMOUR J. SHARKEY, M.D.
ANTHONY A. BOWLBY.
HENRY HUGH CLUTTON.
FREDERICK S. EVE.
ROBERT WILLIAM PARKER.
S. G. SHATTOCK.

Digitized by Google

*** *Members are requested to indicate to the Secretaries corrections when necessary.*

LIST OF MEMBERS OF THE SOCIETY.

Honorary Members.

BILLROTH, THEODOR, M.D., Professor of Surgery in the University of Vienna.
BRUECKE, ERNST, M.D., Professor of Physiology in the University of Vienna.
CHARCOT, J. M., M.D., Physician to the "Hôpital de la Salpêtrière," and Professor at the Faculty of Medicine of Paris.
CHAUVEAU, A., M.D., Professor of Physiology at the Medical School of Lyons.
VON HELMHOLTZ, H., M.D., Professor of Physiology in the University of Heidelberg.
LUDWIG, C., M.D., Professor of Physiology in the University of Leipzig.
PASTEUR, PROFESSOR L., Member of the Institute, Paris.
RINDFLEISCH, EDOUARD, M.D., Professor of Pathological Anatomy in the University of Bonn.
SIMON, SIR JOHN, K.C.B., D.C.L., F.R.S., Consulting Surgeon to St. Thomas's Hospital; 40, Kensington-square, W.
THIERSCH, CARL, M.D., Professor of Surgery in the University of Leipzig.
VIRCHOW, RUDOLF, M.D., Professor of Pathological Anatomy in the University of Berlin.

EXPLANATION OF ABBREVIATIONS.

O.M.—Original Member.	V.-P.—Vice-President.
Pres.—President.	S.—Secretary.
T.—Treasurer.	C.—Member of Council.

Those marked thus (L) have paid Composition Fee for Annual Subscription.
Those marked thus (‡) have paid Composition Fee for Transactions.

Digitized by Google

GENERAL LIST OF MEMBERS.

Elected

1879 ABERCROMBIE, JOHN, M.D., Assistant Physician to Charing Cross Hospital, 23, Upper Wimpole-street, Cavendish-square, W.

1885 ABRAHAM, PHINEAS S., M.A., M.D., Lecturer on Physiology and Histology at the Westminster Hospital; 11, Nottingham-place, W.

1858 ACLAND, Sir HENRY WENTWORTH, K.C.B., M.D., F.R.S., Regius Professor of Medicine, University of Oxford; Broad-street, Oxford.

1883 ACLAND, THEODORE DYKE, M.D., Assistant Physician to St. Thomas's Hospital, and to the Hospital for Consumption, Brompton; 7, Brook-street, Hanover-square, W.

‡1866 ADAMS, ARTHUR BAYLEY.

1869 ADAMS, JAMES EDWARD, Grately, Andover, Hants.

O.M. ADAMS, WILLIAM, Consulting Surgeon to the National Orthopædic Hospital; 5, Henrietta-street, Cavendish-square, W. (C. 1851-4. V.-P. 1867-9.)

L1848 AIKIN, CHARLES A., 7, Clifton-place, Sussex-square, Hyde-park, W. (C. 1864-6.)

1872 AIKIN, CHARLES EDMUND, 7, Clifton-place, Sussex-square, Hyde-park, W.

1871 AIR, A. CUMMINGS, 5, Lancaster-road, South Norwood, S.E.

1880 AITKEN, Sir WILLIAM, M.D., LL.D., F.R.S., Professor of Pathology, Army Medical School, Netley, Southampton; Park Villa, Weston-grove-road, Woolston, Southampton.

1869 ALLBUTT, THOMAS CLIFFORD, M.D., F.R.S., Commissioner in Lunacy; 3, Melbury-road, Kensington, W.

1882 ALLCHIN, WILLIAM HENRY, M.B., Physician to, and Lecturer on Medicine at, the Westminster Hospital; 5, Chandos-street, Cavendish-square, W.

1877 ALTHAUS, JULIUS, M.D., Senior Physician to the Hospital for Epilepsy and Paralysis, Regent's Park; 48, Harley-street, Cavendish-square, W.

1884 ANDERSON, ALEXANDER RICHARD, Surgeon to the General Hospital, 5, East Circus-street, Nottingham.

1868 ANDERSON, J. FORD, M.D., 1, Buckland-crescent, Belsize-park, N.W.

1880 ANDERSON, JAMES, M.A., M.D., C.M., 84, Wimpole-street, Cavendish-square, W.

1871 ANDERSON, WILLIAM, Assistant Surgeon to, and Lecturer on Anatomy at, St. Thomas's Hospital; 25, Grosvenor-road, Westminster. (C. 1888.)

1863 ANDREW, JAMES, M.D. (V.-P.), Physician to St. Bartholomew's Hospital; 22, Harley-street, W. (C. 1868-70.)

1887 ARKLE, CHARLES JOSEPH, M.D., University College Hospital.

1883 ASHBY, HENRY, M.D., Physician to the Manchester General Hospital for Children, and Lecturer on Diseases of Children at Owens College; 13, St. John-street, Manchester.

Digitized by Google

Elected

1882 **Axe**, J. Wortley, Professor of Pathological Histology and Morbid Anatomy at the Royal Veterinary College, College House, Great College-street, Camden-town, N.W.

1863 **Bagshawe**, Frederick, M.A., M.D., 16, Warrior-square, Hastings.

1864 **Baker**, William Morrant, Surgeon to St. Bartholomew's Hospital; 26, Wimpole-street, Cavendish-square, W. (C. 1873-6, 1881-3. S. 1878-80. V.-P. 1886-8.)

‡1856 **Balding**, Daniel Barley, Royston, Herts.

1880 **Ball**, Benjamin, Professeur à la Faculté de Médecine de Paris, Médecin en Chef de la Clinique des Maladies Mentales; rue du Faubourg St. Honoré, 3, Paris.

1881 **Ballance**, Charles A., M.S., Senior Assistant Surgeon, West London Hospital, Assistant Surgeon, Hospital for Sick Children, Great Ormond-street, and Assistant Surgeon for Ear Diseases at St. Thomas's Hospital; 56, Harley-street, W.

1875 **Barker**, Arthur E. J., Surgeon and Assistant Teacher of Clinica Surgery, University College Hospital; 87, Harley-street, Cavendish-square, W. (C. 1884-6.)

1885 **Barling**, Gilbert, M.B., 85, Edmund-street, Birmingham.

1874 **Barlow**, Thomas, M.D., B.S., Assistant Physician to University College Hospital and Physician to the Children's Hospital, Great Ormond-street; 10, Wimpole-street, Cavendish-square, W. (C. 1879-81.)

1862 **Barratt**, Joseph Gillman, M.D.

1877 **Barrow**, A. Boyce, Assistant Surgeon to the Westminster Hospital, and to the West London Hospital; 17, Welbeck-street, Cavendish-square, W.

1881 **Barrs**, Alfred George, M.D., Assistant Physician, General Infirmary, Leeds; 22, Park-place, Leeds.

1879 **Bartlett**, Henry, M.D., Defoe-road, Tooting-corner, S.W.

L1853 **Barwell**, Richard (V.-P. 1889), Consulting Surgeon to the Charing Cross Hospital; 55, Wimpole-street, Cavendish-square, W. (C. 1862-4.)

1861 **Bastian**, H. Charlton, M.A., M.D., F.R.S., Professor of Clinical Medicine in University College, and Physician to University College Hospital; 8A, Manchester-square, W. (C. 1869-71. V.-P. 1885-87.)

1877 **Bateman**, Arthur W., B.A., Tenterfield, New South Wales.

L1876 **Batteson**, John, Medical Officer of the Royal Humane Society; 26, Windsor-road, Forest-gate, E.

1882 **Battle**, William Henry, 6, Harley-street, W.

1870 **Bäumler**, Christian G. H., M.D., Professor of Materia Medica in the University of Erlangen.

1874 **Beach**, Fletcher, M.B., Metropolitan District Asylum, Darenth, near Dartford, Kent.

Digitized by Google

Elected

1879 BEALE, EDWIN CLIFFORD, M.B., Physician to Great Northern Hospital; 23, Upper Berkeley-street, Portman-square, W.

1852 BEALE, LIONEL S., M.B., F.R.S., Professor of Medicine at King's College, Physician to King's College Hospital; 61, Grosvenor-street, W. (C. 1858-9. V.-P. 1874-5.)

1856 BEALEY, ADAM, M.D., M.A., Oak-lea, Harrogate.

L1878 BEANEY, JAMES GEORGE, Senior Surgeon to the Melbourne Hospital, Melbourne, Victoria.

1870 BECK, MARCUS, M.S. (V.-P.), Professor of Surgery in University College, London, and Surgeon to University College Hospital; 80, Wimpole-street, Cavendish-square, W. (C. 1875-7. V.-P. 1888.)

1865 BEEBY, WALTER, M.D., Bromley, Kent.

L1880 BEEVOR, CHARLES EDWARD, M.B., 33, Harley-street, Cavendish-square. (C. 1888.)

1865 BELLAMY, EDWARD, Senior Surgeon to, and Lecturer on Surgery at, the Charing Cross Hospital; 17, Wimpole street, Cavendish-square, W. (C. 1876-8.)

1883 BENHAM, ROBERT FITZROY, Abercorn House, Baron's-court, West Kensington, S.W.

1847 BENNET, JAMES HENRY, M.D., Mentone, Alpes Maritimes, France.

1886 BENNETT, FREDERICK JOSEPH, 28, George-street, Hanover-square, W.

1877 BENNETT, WILLIAM HENRY, Surgeon to St. George's Hospital; 1, Chesterfield-street, Mayfair, W.

1878 BERNARD, FRANCIS R., M.D., 25, Tentercroft-street, Lincoln.

1882 BERRIDGE, WILLIAM ALFRED, Redhill, Surrey.

1886 BERRY, JAMES, 60, Welbeck-street, Cavendish-square, W.

‡1856 BICKERSTETH, EDWARD R., Surgeon to the Liverpool Royal Infirmary; 2, Rodney-street, Liverpool.

1889 BIDWELL, LEONARD ARTHUR, 34, Lee-terrace, Blackheath, S.E.

1882 BINDLEY, PHILIP HENRY, M.B., Fairholme, Hastings.

1878 BINDON, WILLIAM JOHN VEREKER, M.D., 18, St. Ann's-street, Manchester.

L1850 BIRKETT, EDMUND LLOYD, M.D., Consulting Physician to the City of London Hospital for Diseases of the Chest; 48, Russell-square, W.C. (C. 1856-7.)

1881 BISS, CECIL YATES, M.D., Physician to, and Lecturer on Materia Medica at, the Middlesex Hospital, and Assistant Physician to the Hospital for Consumption, Brompton; 135, Harley-street, Cavendish-square, W.

1865 BISSHOPP, JAMES, Bedford-place, Tunbridge Wells.

1877 BLACK, JAMES, Assistant Surgeon to the North-West London Hospital, Lecturer on Anatomy at Westminster Hospital; 16, Wimpole-street, Cavendish-square, W.

1850 BLAGDEN, ROBERT, Stroud, Gloucestershire.

1863 BLANCHET, JEAN B., M.D., M.S., Montreal, Quebec, Canada.

1876 BLASSON, WILLIAM, Edgeware, Middlesex.

1879 BOILEAU, J. P. H., M.D., Surgeon-Major, Army Medical Department. [India.]

Digitized by Google

Elected

1876 BOND, THOMAS, M.B., Assistant Surgeon and Lecturer on Forensic Medicine to Westminster Hospital; 7, Broad Sanctuary, Westminster, S.W.

1869 BOURNE, WALTER, M.D., Archacho, France.

1861 BOWER, RICHARD NORRIS, Ivel Lodge, Sandy, Bedfordshire.

1881 BOWLBY, ANTHONY A., Surgical Registrar, St. Bartholomew's Hospital; 75, Warrington-crescent, Maida Vale, W. (C. 1886–8.)

1851 BOWMAN, Sir WILLIAM, Bart., F.R.S., Consulting Surgeon to the Royal Ophthalmic Hospital; 5, Clifford-street, Bond-street, W. (C. 1855-6. V.P. 1882-4.)

1882 BOYD, STANLEY, M.B., Assistant Surgeon to Charing Cross Hospital; 27, Gower-street, W.C.

1883 BRADSHAW, JAMES DIXON, M.B., 30, George-street, Hanover-square, W.

1879 BRAILEY, WM. ARTHUR, M.D., Lecturer on Comparative Anatomy at, and Assistant Ophthalmic Surgeon to, Guy's Hospital; 11, Old Burlington-street, W.

1880 BRAMWELL, BYROM, M.D., 23, Drumsheugh-gardens West, Edinburgh.

1889 BREDIN, J. NOBLE, 1, Norton Folgate, E.

1886 BRENCHLEY, ALGERNON DUTTON, M.B., 124, Denmark-hill, S.E.

1877 BRIDGES, ROBERT, M.B., M.A., Manor House, Yattendon, Berks.

‡1867 BRIDGEWATER, THOMAS, LL.D. Glas., M.B. Lond., Harrow-on-the-hill, Middlesex.

1873 BRIGGS, JACOB MYERS, M.D., Coeymans, New York, U.S.

1868 BRIGHT, G. C., M.B., Cannes, France.

1857 BRISCOE, JOHN, 12, Broad-street, Oxford.

1885 BRISCOE, JOHN F., The Lammas, Esher, Surrey.

L1851 BRISTOWE, JOHN S., M.D., F.R.S., Physician to, and Lecturer on the Theory and Practice of Medicine at, St. Thomas's Hospital; 13, Old Burlington-street, W. (C. 1854-8. S. 1861-4. C. 1865-7. V.-P. 1868-76, 1887. P. 1885-86.)

1860 BROADBENT, WILLIAM HENRY, M.D., Physician to St. Mary's Hospital, and Consulting Physician to the London Fever Hospital; 34, Seymour-street, Portman-square, W. (C. 1871-3. V.P. 1882-4.)

1886 BROCKATT, ANDREW ALEXANDER, St. Thomas's Hospital, S.E.

BROCKMAN, see DRAKE-BROCKMAN.

L1852 BRODHURST, BERNARD E., Surgeon to the Royal Orthopædic Hospital; 20, Grosvenor-street, W. (C. 1862-4.)

1884 BRODIE, CHARLES GORDON, Middlesex Hospital [Fernhill, Wootton Bridge, Isle of Wight].

1863 BRODIE, GEORGE BERNARD, M.D., Consulting Physician-Accoucheur to Queen Charlotte's Hospital; 3, Chesterfield-street, Mayfair, W.

1865 BROWN, AUGUSTUS, M.D., 10, Chichester-place, Kemp Town, Brighton.

1871 BROWN, FREDERICK GORDON, 17, Finsbury-circus, E.C.

1875 BROWNE, GEORGE BUCKSTON, 80, Wimpole-street, Cavendish-square, W.

L1866 BROWNE, LENNOX, Surgeon to the Central Throat and Ear Hospital, and to the Royal Society of Musicians; 36, Weymouth-street, Portland-place, W.

Digitized by Google

Elected

1877 BRUCE, J. MITCHELL, M.D., Physician to the Charing Cross Hospital, and Assistant Physician to the Hospital for Consumption, Brompton; 70, Harley-street, Cavendish-square, W.

L1855 BRYANT, THOMAS, Consulting Surgeon to Guy's Hospital; 65, Grosvenor-street, Grosvenor-square, W. (C. 1863-6. V.-P. 1877-79.)

1854 BUCHANAN, GEORGE, M.D., F.R.S., Medical Officer of the Local Government Board, 24, Nottingham-place, Marylebone-road, W. (C. 1864-6. V.-P. 1880-82.)

1887 BULL, WILLIAM CHARLES, M.B., 35, Clarges-street, Piccadilly.

1878 BURNET, ROBERT WILLIAM, M.D., 6, Upper Wimpole-street, Cavendish-square, W.

1880 BURTON, SAMUEL HERBERT, M.B., Norfolk and Norwich Hospital, Norwich.

1887 BUTLER-SMYTHE, ALBERT CHARLES, Senior Surgeon to the Grosvenor Hospital for Women and Children; 35, Brook-street, Grosvenor-square, W.

1872 BUTLIN, HENRY TRENTHAM (C.), Assistant Surgeon to, and Demonstrator of Practical Surgery and of Disease of the Larynx at, St. Bartholomew's Hospital; 82, Harley-street, Cavendish-square, W. (C. 1876-8, 1887. S. 1884-6.)

1866 BUTT, WILLIAM FREDERICK, 48, Park-street, Park-lane, W.

1883 BUXTON, DUDLEY W., M.D., Administrator and Teacher of the use of Anæsthetics in University College Hospital; Anæsthetist to the Hospital for Women, Soho-square, and to the Dental Hospital; 82, Mortimer-street, Cavendish-square, W.

1856 BUZZARD, THOMAS, M.D., Physician to the National Hospital for the Epileptic and Paralysed; 74, Grosvenor-street, W. (C. 1869-70. V.-P. 1881-3.)

1885 CAHILL, JOHN, 12, Seville-street, Lowndes-square, S.W.

LO.M. CAMPS, WILLIAM, M.D. (C. 1856-9.)

‡1855 CARPENTER, ALFRED, M.D., Duppas House, Croydon.

1855 CARTER, H. VANDYKE, M.D., Late Principal of, and Professor of Anatomy and Physiology at, Grant Medical College, Bombay.

1876 CARTER, ROBERT BRUDENELL, Ophthalmic Surgeon to, and Lecturer on Ophthalmic Surgery at, St. George's Hospital; 27, Queen Anne-street, Cavendish-square, W.

1879 CASSIDY, JOSEPH LAMONT, M.D., 44, Harley-street, Cavendish-square, W.

1877 CASSON, JOHN HORNSEY.

L1868 CAVAFY, JOHN, M.D., Physician to St. George's Hospital; 2, Upper Berkeley-street, Portman-square, W. (C. 1881-3.)

1864 CAY, CHARLES VIDLER, Deputy Surgeon-General, Army.

1863 CAYLEY, WILLIAM, M.D. (TREASURER), Physician to, and Lecturer on the Principles and Practice of Medicine at, the Middlesex Hospital; 27, Wimpole-street, Cavendish-square, W. (C. 1870-1, 1875-8. S. 1872-4. V.-P. 1884-6. T. 1888.)

Digitized by Google

Elected

1869 CHAFFERS, EDWARD, Keighley, Yorkshire.

1884 CHAFFEY, WAYLAND CHARLES, M.B., Assistant Physician to the Royal Alexandra Hospital for Sick Children; 8, North-street, Brighton.

1876 CHARLES, T. CRANSTOUN, M.D., M.C., Lecturer on Practical Physiology at St. Thomas's Hospital; Albert Mansions, 106, Victoria-street, Westminster.

1884 CHAVASSE, THOMAS FREDERICK, M.D., C.M., Surgeon to the Birmingham General Hospital; 24, Temple-row, Birmingham.

1879 CHEYNE, WILLIAM WATSON, M.B., C.M., Assistant Surgeon to King's College Hospital; 59, Welbeck-street, Cavendish-square, W. (C. 1885-7.)

1858 CHILD, GILBERT W.

1873 CHISHOLM, EDWIN, M.D., Abergeldie, Ashfield, near Sydney, New South Wales [care of Messrs. Dawson, 121, Cannon-street, E.C.].

1871 CHRISTIE, THOMAS BEATH, M.D., Superintendent of the Royal India Asylum, Ealing, Middlesex.

1865 CHURCH, WILLIAM SELBY, M.D., Physician to St. Bartholomew's Hospital; 130, Harley-street, Cavendish-square, W. (C. 1871-3.)

‖1868 CHURCHILL, FREDERICK, M.B., Surgeon to the Victoria Hospital for Children; 4, Cranley-gardens, Queen's-gate, S.W.

1861 CLAPTON, EDWARD, M.D., 10A, St. Thomas's-street, Southwark, S.E.

1854 CLARK, Sir ANDREW, Bart., M.D., LL.D., F.R.S., Physician to, and Emeritus Professor of Clinical Medicine at, the London Hospital; 16, Cavendish-square, W. (C. 1862-5. V.-P. 1881-3.)

1872 CLARK, ANDREW, Surgeon to the Middlesex Hospital; 71, Harley-street, Cavendish-square, W.

1886 CLARK, FRANCIS WILLIAM, Darenth Imbecile Schools, near Dartford, Kent.

1883 CLARKE, ERNEST, M.D., B.S., 21, Lee-terrace, Blackheath, S.E.

1885 CLARKE, JOHN MICHELL, M.B., 2, York Buildings, Clifton, Bristol.

1881 CLARKE, W. BRUCE, M.B., Assistant Surgeon and Lecturer on Anatomy, St. Bartholomew's Hospital; 46, Harley-street, Cavendish-square, W.

‖1875 CLUTTON, HENRY HUGH, M.A., Assistant Surgeon to St. Thomas's Hospital; 2, Portland-place, W. (C. 1884-6.)

‡1865 COATES, CHARLES, M.D., Physician to the Bath General and Royal United Hospitals; 10, Circus, Bath.

1885 COATS, JOSEPH, M.D., 31, Lynedoch-street, Glasgow.

1856 COCKLE, JOHN, M.D., M.A., Consulting Physician to the Royal Free Hospital; 8, Suffolk-street, Pall Mall, S.W.

1886 COLLIER, WILLIAM, M.D., 62, High-street, Oxford.

1888 COLLINS, WILLIAM JOB, M.D., M.S., 1, Albert-terrace, Regent's-park, N.W.

1879 COLLINS, WM. MAUNSELL, M.D., 10, Cadogan-place, S.W.

1878 COLLYNS, R. T. POOLE, 20, Lingfield-road, Wimbledon.

1888 COLMAN, WALTER STACY, M.B., West London Hospital, Hammersmith-road, W.

Digitized by Google

Elected

1882 COLQUHOUN, DANIEL, M.D., Dunedin, New Zealand.

1882 COMPTON, FRANCIS CHARLES, 72, High-street, Poole, Dorset.

1858 COOKE, R. T. E. BARRINGTON, Consulting Surgeon to the Scarborough Dispensary, Consulting Surgeon to the Royal Northern Sea-Bathing Infirmary; 15, St. Nicholas-cliff, Scarborough, Yorkshire.

1871 COOKE, THOMAS, Assistant Surgeon to the Westminster Hospital; 40, Brunswick-square, W.C.

1866 COOMBS, ROWLAND HILL, Mill-street, Bedford.

1879 COOPER, ARTHUR, 20, Old Burlington-street, W.

1889 COPEMAN, SYDNEY ARTHUR MONCKTON, M.A., M.B., St. Thomas's Hospital, Albert Embankment, S.E.

1853 CORNISH, WILLIAM ROBERT, C.I.E., late Surgeon-General, Madras Army, Hon. Physician to H.M. the Queen; 8, Cresswell Gardens, Kensington, S.W.

1875 CORY, ROBERT, M.D., Assistant Obstetric Physician to St. Thomas's Hospital; 73, Lambeth Palace-road, S.E.

1876 COTTLE, WYNDHAM, M.D., Assistant Surgeon to the Hospital for Diseases of the Skin, Blackfriars; 3, Savile-row, W.

L1861 COUPER, JOHN, Surgeon to the Royal London Ophthalmic Hospital; 80, Grosvenor-street, Grosvenor-square, W. (C. 1870-2.)

1873 COUPLAND, SIDNEY, M.D., Physician to, and Lecturer on Practical Medicine at, the Middlesex Hospital; 16, Queen Anne-street, W. (C. 1878-81, 1889. S. 1886-8.)

1884 CRICHTON, GEORGE, M.B., 3, Cambridge-villas, Twickenham.

1873 CRIPPS, WILLIAM HARRISON, Assistant Surgeon to St. Bartholomew's Hospital; 2, Stratford-place, Oxford-street, W. (C. 1883-5.)

1877 CROCKER, HENRY RADCLIFFE, M.D., Physician to the Skin Department, University College Hospital; Physician to the East London Hospital for Children; 121, Harley-street, Cavendish-square, W. (C. 1887-8.)

1856 CROFT, JOHN, Surgeon to St. Thomas's Hospital; 48, Brook-street, Grosvenor-square, W. (C. 1870-2. V.-P. 1882–4)

1879 CROOKE, GEORGE FREDERICK, M.D., Physician to Out-Patients at the Queen's Hospital, Birmingham.

1886 CROOKSHANK, EDGAR, M.B., Professor of Bacteriology at King's College, London; 24, Manchester-square, W.

1861 CROSBY, THOMAS BOOR, M.D., 21, Gordon-square, W.C.

1875 CROSS, FRANCIS RICHARDSON, 5, The Mall, Clifton, Bristol.

1885 CULLINGWORTH, CHARLES JAMES, M.D., Obstetric Physician to, and Lecturer on Midwifery at, St. Thomas's Hospital; 46, Brook-street, Grosvenor-square, W.

1871 CUMBERBATCH, ELKIN, Aural Surgeon at St. Bartholomew's Hospital 17, Queen Anne-street, W.

Digitized by Google

Elected

1873 CURNOW, JOHN, M.D., Professor of Anatomy at King's College, Physician to King's College Hospital, and Senior Visiting Physician to the Seamen's Hospital; 3, George-street, Hanover-square, W. (C. 1882-4.)

‡1865 CURRAN, WILLIAM, M.D. [33, Auriol-road, West Kensington, W.], care of Mr. Lewis, Gower-street.

1884 DAKIN, W. RADFORD, M.D., B.S., 57, Welbeck-street, Cavendish-square, W.

1884 DALLAWAY, DENNIS, 5, Duchess-street, Portland Place, W.

1883 DALTON, NORMAN, M.D., Assistant Physician to King's College Hospital; 14, Clement's-inn, Strand, W.C.

1873 DAVIDSON, ALEXANDER, M.D., Physician to the Liverpool Royal Infirmary, Lecturer on Pathology at the Liverpool Medical School; 2, Gambier-terrace, Liverpool.

1885 DAVIES, ARTHUR, M.B., 23, Finsbury-square, E.C.

L1869 DAVIES-COLLEY, J. NEVILLE C., M.B. Surgeon to Guy's Hospital; 36, Harley-street, Cavendish-square, W. (C. 1880-82.)

1883 DAVIS, EDWIN HARRY, West Hartlepool.

‡1859 DAVIS, FRANCIS WILLIAM, R.N., Surgeon to the Naval Medical Establishment, Lisbon. [Agents: Messrs. Hallett and Co., 7, St. Martin's-place, Trafalgar-square, W.C.]

1879 DAVY, HENRY, M.D., Physician to the Devon and Exeter Hospital; 29, Southernhay, Exeter.

1866 DAY, WILLIAM HENRY, M.D., Physician to the Samaritan Free Hospital for Women and Children; 10, Manchester-square, W.

1887 DELÉPINE, SHERIDAN, M.B., 6, Chapel-place, Cavendish-square, W.

1880 DENT, CLINTON T., Assistant Surgeon to St. George's Hospital; 61, Brook-street, Grosvenor-square W.

1863 DEVEREUX, DANIEL, Tewkesbury, Gloucestershire.

1856 DICK, H., M.D.

1871 DICKINSON, EDWARD HARRIMAN, M.A., M.D., Physician to the Liverpool Northern Hospital, and Lecturer on Comparative Anatomy at the Liverpool School of Medicine; 162, Bedford-street, Liverpool.

L1858 DICKINSON, WILLIAM HOWSHIP, M.D. (PRESIDENT), Physician to the Hospital for Sick Children, Physician and Lecturer on Medicine to St. George's Hospital; Honorary Fellow of Caius College, Cambridge; 9, Chesterfield-street, Mayfair, W. (C. 1866-8. S. 1869-71. V.-P. 1872-4. P. 1889.)

1872 DIVER, EBENEZER, M.D., Kenley, Caterham-valley, Surrey.

1872 DORAN, ALBAN HENRY GRIFFITHS, Surgeon to the Samaritan Free Hospital; 9, Granville-place, W. (C. 1882-84.)

1888 DOVE, AUGUSTUS CHARLES, M.B., B.S., Parkside, Crescent-road, Crouch End, N.

L1866 DOWN, JOHN LANGDON H., M.D., Physician to, and Lecturer on Clinical Medicine at, the London Hospital; 81, Harley-street, Cavendish-square, W. (C. 1872-4.)

1872 DOWSE, THOMAS STRETCH, M.D., 14, Welbeck-street, Cavendish-square, W.

Digitized by Google

Elected

1877 DRAKE-BROCKMAN, E. F., Madras Medical Service [care of Mr. Lewis, Gower-street, W.C.]

1880 DREschfeld, JULIUS, M.D., Physician to the Manchester Infirmary; 325, Oxford-road, Manchester.

1879 DREWITT, F. G. DAWTREY, M.D., 52, Brook-street, Grosvenor-square, W.

1865 DUCKWORTH, Sir DYCE, M.D., Physician to St. Bartholomew's Hospital; 11, Grafton-street, Bond-street, W. (C. 1877.)

L1847 DUDGEON, ROBERT E., M.D., 53, Montagu-square, W.

1865 DUFFIN, ALFRED BAYNARD, M.D., Physician to King's College Hospital; 18, Devonshire-street, Portland-place, W. (C. 1872-4.)

1868 DUKE, OLIVER THOMAS, M.B., India.

1871 DUKES, CLEMENT, M.D., B.S. Lond., Physician to Rugby School; Sunnyside, Rugby.

1877 DUNBAR, J. J. MACWHIRTER, M.D., Assistant House-Physician to St. George's Hospital; Hedingham House, Clapham-common, S.W.

1877 DUNCAN, ANDREW, M.D., 8, Henrietta-street, Covent-garden, W.C.

1880 DUNCAN, JAS. MATTHEWS, M.D., LL.D., F.R.S., Obstetric Physician to St. Bartholomew's Hospital; 71, Brook-street, Grosvenor-square, W.

1884 DUNN, LOUIS ALBERT, M.B., B.S., Demonstrator of Anatomy, Guy's Hospital; and Assistant Surgeon to the East London Hospital for Children; 15, St. Thomas's-street, S.E.

1858 DURHAM, ARTHUR EDWARD, Surgeon to Guy's Hospital; 82, Brook-street, Grosvenor-square, W. (C. 1869-71. V.P. 1883-5.)

1879 DURHAM, FREDERIC, M.B., 82, Brook-street, Grosvenor-square, W.

L1880 EDMUNDS, WALTER, M.D., 75, Lambeth Palace-road, S.E.

1882 EDWARDES, EDWARD JOSHUA, M.D., 16, Acacia-road, St. John's Wood, N.W.

1882 EDWARDS, F. SWINFORD, Surgeon to the West London Hospital, and to St. Peter's Hospital for Stone; 93, Wimpole-street, Cavendish-square, W.

1889 ELAM, WILLIAM HENRY, New Barnet, Herts.

1883 ELDER, GEORGE, M.D., Surgeon to the Hospital for Women; 17, Regent-street, Nottingham.

1867 ELLIS, JAMES, M.D., California.

1873 ENGELMANN, GEORGE JULIUS, M.D., A.M., 3003, Locust-street, St. Louis, Miss., U.S.

L1846 ERICHSEN, JOHN ERIC, LL.D., F.R.S., Surgeon Extraordinary to Her Majesty the Queen, Emeritus Professor of Surgery at University College, and Consulting Surgeon to University College Hospital; 6, Cavendish-place, Cavendish-square, W. (C. 1849-51. V.-P. 1863-4.)

1853 EVANS, CONWAY, M.D., 5, Tavistock-street, W.C. (C. 1867-8.)

1875 EVANS, JULIAN, A.M., M.D., Physician to the Victoria Hospital for Children; 123, Finboro'-road, Redcliffe-square, West Brompton, S.W.

Digitized by Google

Elected

1879 **Eve**, Frederic S., Pathological Curator of the Museum, Royal College of Surgeons of England, and Assistant Surgeon to the London Hospital; 125, Harley-street, Cavendish-square, W. (C. 1885-7.)

1876 **Ewart**, James Cossar, M.B., C.M., School of Medicine, Edinburgh.

1881 **Ewart**, Joseph, M.D., late Professor of Medicine at Calcutta Medical College; Montpellier Terrace, Brighton.

1877 **Ewart**, William, M.B., Assistant Physician to, and Lecturer on Physiology at, St. George's Hospital; 33, Curzon-street, Mayfair, W. (C. 1889.)

‡1859 **Ewens**, John, 14, Whiteladies-road, Clifton, Bristol.

1887 **Eyles**, Charles Henry, Gold Coast Colony.

1872 **Fayrer**, Sir Joseph, K.C.S.I., M.D. F.R.S. Hon. Physician to the Queen, Surgeon-Major, Bengal Army, Examining Medical Officer to the Secretary of State for India in Council; 53, Wimpole-street, Cavendish-square, W. (C. 1880-2.)

1872 **Fenn**, Edward L., M.B., The Old Palace, Richmond, Surrey.

1883 **Fenwick**, E. Hurry, Assistant Surgeon to the London Hospital, Surgeon and Pathologist to St. Peter's Hospital for Stone; 5, Old Burlington-street, W.

1872 **Fenwick**, John C. J., M.D., Physician to the Durham County Hospital; 25, North-road, Durham.

1863 **Fenwick**, Samuel, M.D., Physician to the London Hospital; 29, Harley-street, W.

1885 **Fére**, Charles, M.D., Médecin de Bicêtre; Boulevard St. Michel, 37, Paris.

1846 **Fincham**, George T., M.D., Consulting Physician to the Westminster Hospital; 13, Belgrave-road, S.W. (C. 1855.)

1876 **Finlay**, David W., M.D., Physician to the Middlesex Hospital; 9, Lower Berkeley-street, Portman-square, W. (C. 1886-8.)

1859 **Fisher**, Alexander, M.D., Assistant Surgeon R.N., Her Majesty's Ship "Endymion."

1882 **Fleming**, George, C.B., LL.D., F.R.C.V.S., Principal Veterinary Surgeon to the Army, Cathcart Lodge, Tyrwhitt-road, St. John's, S.E.

1872 **Forbes**, Daniel Mackay, Shoreditch Infirmary, 204, Hoxton-street, N.

‡1866 **Foster**, Sir Balthazar Walter, M.D., M.P., Physician to the General Hospital, Birmingham; 16, Temple-row, Birmingham.

1873 **Fotherby**, Henry J., M.D., Physician to the Metropolitan Free Hospital; Woodthorpe Cotes, Reigate.

1880 **Fowler**, James Kingston, M.A., M.D., Assistant Physician to, and Lecturer on Pathological Anatomy at, the Middlesex Hospital, and Assistant Physician to the Hospital for Consumption, Brompton; 35, Clarges-street, Piccadilly, W. (C. 1887-8.)

Digitized by Google

Elected

1878 Fox, Thomas Colcott, M.B., B.A., Physician to the Skin Department of the Westminster Hospital, and to the Paddington Green Hospital; 14, Harley-street, Cavendish-square, W.

1858 Francis, Charles Richard, M.B., Bengal Medical Establishment, Indian Army.

1886 Freeman, Henry William, 24, Circus, Bath.

O.M. Frere, J. C.

1864 Frodsham, John Mill, M.D., Streatham, S.W.

1880 Gabbett, Henry Singer, M.B., 20, Burlington-place, Eastbourne.

‡1858 Gairdner, William Tennant, M.D., LL.D., Professor of Medicine in the University of Glasgow; 225, St. Vincent-street, Glasgow.

1870 Galton, John H., M.D, 39, Anerley-road, Upper Norwood, S.E.

1855 Gamgee, J.

1846 Garrod, Sir Alfred Baring, M.D., F.R.S., Consulting Physician to King's College Hospital; 10, Harley-street, Cavendish-square, W. (C. 1851. V.-P. 1863-5.)

1879 Garstang, Thomas Walter Harropp, Headingley House, Knutsford, Cheshire.

1872 Garton, William, M.D., Hardshaw-street, St. Helen's, Lancashire.

1880 Gibbes, Heneage, M.B., Professor of Pathology, University of Michigan, Ann Arbor, Michigan, U.S.A.

L1853 Gibbon, Septimus, M.D., 39, Oxford-terrace, Hyde-park, W.

1878 Gibbons, R. A., M.D., Physician to the Grosvenor Hospital for Women and Children; 29, Cadogan-place, S.W.

1876 Gill, John, M.D., 31, Apsley-road, Clifton, Bristol.

1881 Glynn, Thomas Robinson, M.D., Physician to the Liverpool Royal Infirmary; 62, Rodney-street, Liverpool.

1873 Godlee, Rickman John, M.B., B.S. (Hon. Secretary), Assistant Surgeon to University College Hospital; Teacher of Operative Surgery in University College, London; 81, Wimpole-street, Cavendish-square, W. (C. 1877-80. S. 1887-8.)

1875 Godson, Clement, M.D., Assistant Physician-Accoucheur to St. Bartholomew's Hospital; Consulting Physician to the City of London Lying-in Hospital; 9, Grosvenor-street, W.

1879 Godwin, Charles Henry Young, Surgeon Major, Army; Victoria Hospital, Netley.

1878 Golding-Bird, Cuthbert H., M.B., Assistant Surgeon to, and Lecturer on Physiology at, Guy's Hospital; 13, St. Thomas's-street, S.E. (C. 1885-7.)

1871 Goodhart, James Frederic, M.D., Physician to, and Lecturer on Pathology at, Guy's Hospital; Physician to the Evelina Hospital for Sick Children; 25, Weymouth-street, Portland-place, W. (C. 1876-8, 1886-8. S. 1883-5.)

1875 Gould, Alfred Pearce, M.S., Assistant Surgeon to the Middlesex Hospital,; 16, Queen Anne-street, W. (C. 1883-5.)

Digitized by Google

Elected

1870 GOWERS, WILLIAM RICHARD, M.D., F.R.S., Consulting Physician to University College Hospital; 50, Queen Anne-street, Cavendish-square, W. (C. 1878-9.)

L1858 GOWLLAND, PETER Y., Surgeon to St. Mark's Hospital; 34, Finsbury-square, E.C.

1888 GRANT, J. DUNDAS, M.A., M.D., C.M., 17, Finsbury Square, E.C.

1867 GREEN, T. HENRY, M.D., Physician to Charing Cross Hospital, Assistant Physician to the Hospital for Consumption, Brompton; 74, Wimpole-street, W. (C. 1871-3, 1878-9. S. 1875-6. V.-P. 1886-8.)

1873 GREENFIELD, WILLIAM SMITH, M.D., B.S., Professor of General Pathology in the University of Edinburgh; 7, Heriot-row, Edinburgh. (C. 1877-80.)

‡1855 GREENHILL, WILLIAM ALEXANDER, M.D., 5, The Croft, Hastings.

1886 GREVES, EDWIN HYLA, M.D., Rodney House, Suffolk-road, Bournemouth.

1885 GRIFFITH, WALTER SPENCER ANDERSON, M.B., Physician to the Samaritan Free Hospital for Women and Children; 114, Harley-street, Cavendish-square, W.

1887 GRIFFITHS, JOSEPH, M.B., C.M., Assistant Demonstrator of Pathology, University of Cambridge; 17, Fitzwilliam-street, Cambridge.

1876 GRIFFITHS, THOMAS D., M.D., Hearne Lodge, Swansea.

1882 GROSS, CHARLES, M.D., M.S., Medical Superintendent, St. Saviour's Infirmary; East Dulwich-grove, S.E.

1861 GUENEAU DE MUSSY, HENRI, M.D., 15, Rue du Cirque, Paris.

1863 GULL, SIR WILLIAM WITHEY, Bart., M.D., D.C.L., F.R.S., Physician in Ordinary to H.M. the Queen; Consulting Physician to Guy's Hospital; 74, Brook-street, Grosvenor-square, W.

1881 GULLIVER, GEORGE, M.B., Assistant Physician to, and Lecturer on Comparative Anatomy at, St. Thomas's Hospital; 16, Welbeck-street, Cavendish-square, W.

1880 GUNN, R. MARCUS, M.B., C.M., 54, Queen Anne-street, Cavendish-square, W.

1876 GWYTHER, JAMES, M.B., St. Mary Church, Torquay.

1887 HABERSHON, SAMUEL HERBERT, M.D., Casualty Physician to St. Bartholomew's Hospital; 70, Brook-street, Grosvenor-square, W.

L1851 HACON, E. DENNIS, 269, Mare-street, Hackney, N.E. (C. 1872.)

1879 HADDEN, WALTER BAUGH, M.D., Assistant Physician to, and Demonstrator of Morbid Anatomy at, St. Thomas's Hospital; 21, Welbeck-street, W. (C. 1886-8.)

1882 HAIG, A., M.B., 39, Welbeck-street, Cavendish-square, W.

1877 HALLOWES, FREDERICK BLACKWOOD, Redhill, Surrey.

1886 HAMILTON, DAVID JAMES, M.B., Professor of Pathology at the University of Aberdeen, 1, Albyn-place, Aberdeen.

1886 HANDFORD, HENRY, M.D., Physician to Nottingham General Hospital; 14, Regent-street, Nottingham.

Digitized by Google

Elected

1882 HARBINSON, ALEXANDER, M.D., County Lunatic Asylum, Lancaster.

L1848 HARE, CHARLES JOHN, M.D., Consulting Physician to University College Hospital; Berkeley House, 15, Manchester Square, W. (C. 1852-4. V.-P.1874-7.)

L1856 HARLEY, GEORGE, M.D., F.R.S., 25, Harley-street, Cavendish-square, W. (C. 1862-5. V.-P. 1878-80.)

1872 HARRIS, HENRY, M.D., Trengweath-place, Redruth, Cornwall.

1879 HARRIS, VINCENT DORMER, M.D., Demonstrator of Physiology, St. Bartholomew's Hospital, Senior Assistant Physician, Victoria Park Hospital; 31, Wimpole-street, Cavendish-square, W.

L1858 HART, ERNEST, 38, Wimpole-street, Cavendish-square, W. (C. 1867-8.)

1870 HAWARD, JOHN WARRINGTON, Surgeon to St. George's Hospital; 16, Savile-row, W. (C. 1879-81.)

1886 HAWKINS, FRANCIS HENRY, M.B., Physician to St. George's and St. James's Dispensary, and to the North London Hospital for Consumption; 59, Wimpole-street, Cavendish-square, W.

L1856 HEATH, CHRISTOPHER, Holme Professor of Clinical Surgery in University College, and Surgeon to University College Hospital; 36, Cavendish-square, W. (C. 1866-7. V.-P. 1879-81.)

1881 HEBB, RICHARD G., M.D., Lecturer on Morbid Histology at the Westminster Hospital; 9, Suffolk-street, Pall-mall, S.W.

1884 HEBBERT, CHARLES ALFRED, Westminster Hospital.

1878 HELLIER, JOHN B., M.B., Headingley, Leeds.

1879 HENDERSON, GEORGE COURTENAY, M.D., Kingston, Jamaica, West Indies.

1869 HENSLEY, PHILIP J., M.D., Assistant Physician and Lecturer on Forensic Medicine, St. Bartholomew's Hospital; 4, Henrietta-street, Cavendish-square, W.

1884 HERRINGHAM, WILMOT PARKER, M.B., Assistant Demonstrator of Anatomy at St. Bartholomew's Hospital, and Assistant Physician to the West London Hospital; 13, Upper Wimpole-street, Cavendish-square, W.

O.M. HEWETT, SIR PRESCOTT G., Bart., F.R.S., Consulting Surgeon to St. George's Hospital; Chesnut Lodge, Horsham, Sussex. (C. 1846-52. V.-P. 1854-7. *Pres.* 1863-4. V.-P. 1865-8.)

1855 HEWITT, GRAILY, M.D., Consulting Obstetric Physician to University College Hospital; 36, Berkeley-square, W. (C. 1865-7.)

1864 HICKMAN, WILLIAM, M.B., Surgeon to the Samaritan Free Hospital; 1, Dorset-square, N.W.

1860 HILL, M. BERKELEY, M.B., Surgeon to University College Hospital, and Surgeon for Out-Patients to the Lock Hospital; 66, Wimpole-street, Cavendish-square, W. (C. 1874-5.)

1875 HITCHCOCK, HARRY KNIGHT, M.D., Christowell, Branksome-park, Bournemouth, Hants.

1880 HOBSON, JOHN MORRISON M.D., 65, Lower Addiscombe-road, Croydon.

L1854 HOLMES, TIMOTHY, Consulting Surgeon to St. George's Hospital; 18, Great Cumberland-place, Hyde-park, W. (C. 1862-3. S. 1864-7. C. 1868. V.-P. 1869-71.)

Digitized by Google

Elected

1850 HOLT, BARNARD WIGHT, Consulting Surgeon to the Westminster Hospital; 14, Savile-row, W. (C. 1853.)

O.M. HOLTHOUSE, CARSTEN. (C. 1852-4, V.-P. 1874-5.)

1878 HOOD, DONALD WILLIAM CHARLES, M.D., Physician to the North-West London Hospital, Physician to the West London Hospital; 43, Green-street, Park Lane, W.

1864 HOOD, WHARTON P., M.D., 11, Seymour-street, Portman-square, W.

1870 HOPE, WILLIAM, M.D., 56, Curzon-street, Mayfair, W.

1882 HOPKINS, John, Medical Superintendent, Central London Sick Asylum, Cleveland-street, W.

1879 HORROCKS, PETER, M.D., Assistant Obstetric Physician to Guy's Hospital, 9, St. Thomas's-street, S.E.

1883 HORSLEY, VICTOR, M.B., B.S., F.R.S., Assistant Surgeon to University College Hospital, Professor of Pathology, University College, London, Superintendent of the Brown Institution, Wandsworth-road; 80, Park-street, Grosvenor-square, W. (C. 1888.)

L1880 HOVELL, T. MARK, Aural Surgeon to the London Hospital; 3, Mansfield-street, Portland-place, W.

1875 HOWSE, HENRY GREENWAY, M.S., Surgeon to Guy's Hospital, and to the Evelina Hospital for Sick Children; 59, Brook-street, Grosvenor-square. W. (C. 1878-81.)

1884 HUDSON, CHARLES LEOPOLD, Pathologist and Curator of the Museum, Middlesex Hospital; Warden of the College; The College, Cleveland-st.

L1856 HUDSON, JOHN, M.D., 11, Cork-street, Bond-street, W.

L1854 HULKE, JOHN WHITAKER, F.R.S., Surgeon to the Middlesex Hospital and Surgeon to the Royal London Ophthalmic Hospital; 10, Old Burlington-street, W. (C. 1863-5. S. 1868-72. V.-P. 1873-6, 1885-6. T. 1877-9. P. 1883-4.)

L1858 HUMBY, EDWIN, M.D., 83, Hamilton-terrace, St. John's Wood, N.W.

1874 HUMPHREYS, HENRY, M.D., late Physician to the Children's Hospital at Pendlebury; 16, Warrior Gardens, St. Leonards-on-Sea.

1883 HUMPHRY, GEORGE MURRAY, M.D., F.R.S., Surgeon to Addenbrooke's Hospital; Professor of Surgery in the University of Cambridge.

1888 HUNTER, WILLIAM, M.D., St. John's College, Cambridge.

1852 HUTCHINSON, JONATHAN, F.R.S., Consulting Surgeon to the London Hospital and to the Royal London Ophthalmic Hospital, Moorfields; 15, Cavendish-square, W. (C. 1856-9. V.-P. 1872-3, 1881-3. P. 1879-80.)

1882 HUTCHINSON, JONATHAN, junr., Assistant Surgeon to the London Hospital, 15, Cavendish-square, W. (C. 1889.)

1884 HUTTON, HENRY RICHMOND, M.B., 8A, St. John-street, Manchester.

1889 HYSLOP, THEOPHILUS BULKELEY, M.B., C.M., Bethlem Royal Hospital, S.E.

1880 INGRAM, ERNEST FORTESCUE, Newcastle, Natal, S. Africa.

1886 JACKSON, ARTHUR MOLYNEUX, M.B., Surrey County Asylum, Tooting, S.W.

Digitized by Google

Elected

1865 JACKSON, J. HUGHLINGS, M.D., F.R.S. (V.-P.), Physician to the London Hospital, Physician to the National Hospital for the Paralysed and Epileptic; 3, Manchester-square, W. (C. 1872-3. V.-P. 1888.)

1886 JACKSON, PHILIP J., 216, Great Dover-street, S.E.

1887 JACOB, ERNEST HENRY, M.D., 12, Park-street, Leeds.

1875 JALLAND, WILLIAM HAMERTON, St. Leonard's House, Museum-street, York.

1888 JAMES, J. T., 30, Harley-street, Cavendish-square, W.

‡1853 JARDINE, JOHN LEE, Capel, near Dorking, Surrey.

O.M. JENNER, SIR WILLIAM, Bart., M.D., D.C.L., K.C.B., F.R.S., Consulting Physician to University College Hospital; 63, Brook-street, Grosvenor-square, W. (C. 1850-3. V.-P. 1862-4 1875-6. *Pres.* 1873-4.)

1881 JENNINGS, WILLIAM OSCAR, M.D., 8, Rue Roy, Paris.

1879 JESSOP, CHARLES MOORE, 98, Sutherland-avenue, W.

1866 JESSOP, THOMAS RICHARD, 31, Park-square, Leeds.

1878 JOHNSON, ARTHUR JUKES, Yorkville, Ontario, Canada.

1876 JOHNSON, CHARLES HENRY, late Staff Surgeon, Turkish Contingent; Winton House, Basingstoke, Hants.

O.M. JOHNSON, GEORGE, M.D., F.R.S., Consulting Physician to King's College Hospital; 11, Savile-row, W. (C. 1846-50. V.-P. 1863-4, 1884-6. T. 1880-83.)

1888 JOHNSON, RAYMOND, M.B., B.S., 123, Gower-street, W.C.

1881 JOHNSTON, JOSEPH, M.D., Brigade Surgeon, Army Medical Department; 24, St. John's Wood-park, N.W.

1854 JOHNSTONE, ATHOL A. W., St. Moritz House, 61, Dyke-road, Brighton.

1853 JONES, SYDNEY, M.B., Surgeon to St. Thomas's Hospital; 16, George-street, Hanover-square, W. (C. 1864-6. V.-P. 1886-7.)

1888 JONES, TALFOURD, M.B., Eastbourne.

1862 JONES, THOMAS RIDGE, M.D., Physician to the Victoria Hospital for Children; 4, Chesham-place, S.W. (C. 1882-4.)

1886 JULER, HENRY EDWARD, Assistant Surgeon Royal Westminster Ophthalmic Hospital, Junior Ophthalmic Surgeon to St. Mary's Hospital; 77, Wimpole-street, Cavendish-square, W.

1867 KELLY, CHARLES, M.D., Professor of Hygiene, King's College, Strand; Broadwater-road, Worthing, Sussex. (C. 1874.)

1846 KENT, THOMAS J., 89, Piccadilly, W.

1852 KERSHAW, W. WAYLAND, M.D., Kingston-on-Thames.

1879 KESTEVEN, WILLIAM HENRY, 16, Parkhurst-road, N.

1859 KIALLMARK, HENRY WALTER, 5, Pembridge-gardens, Bayswater, W. (C. 1875-6.)

1882 KIDD, PERCY, M.D., Assistant Physician to the Hospital for Consumption, Brompton; 60, Brook-street, Grosvenor-square, W. (C. 1889.)

1867 KING, EDWIN HOLBOROW, Netley Court, Southampton.

1871 KING, ROBERT, M.B., Bargaly, Newton Stewart, N.B.

Digitized by Google

Elected

1852 KINGDON, J. ABERNETHY, Surgeon to the City Dispensary, and to the City of London Truss Society; 2, New Bank-buildings, Lothbury, E.C.

1878 KLEIN, EDWARD EMANUEL, M.D., F.R.S., Joint Lecturer on Physiology at St. Bartholomew's Hospital; 19, Earl's Court-sq., S.W. (C. 1888.)

1888 KYNSEY, WILLIAM RAYMOND, C.M.G., Inspector-General of Hospitals, Colombo, Ceylon.

1878 LANCEREAUX, ETIENNE, M.D., 44, Rue de la Bienfaisance, Paris.

1882 LANE, WILLIAM ARBUTHNOT, M.B., M.S., Assistant Surgeon to Guy's Hospital, and to the Hospital for Sick Children, Great Ormond-street; 14, St. Thomas's-street, S.E.

1865 LANGTON, JOHN, Surgeon to, and Lecturer on Anatomy at, St. Bartholomew's Hospital, and Surgeon to the City of London Truss Society; 2, Harley-street, Cavendish-square, W. (C. 1882-4.)

1886 LANKESTER, HERBERT, M.D., 1, Elm-park-gardens, South Kensington, S.W.

1869 LARCHER, O., M.D. Par., Laureate of the Institute of France, of the Medical Faculty and Academy of Paris; 97, Rue de Passy, Paris. [M. Kliensieck, Libraire, Rue de Lille, 11, Paris, per Messrs. Longmans.]

1884 LARDER, HERBERT, Medical Superintendent, Whitechapel Infirmary, E.

1873 LATHAM, PETER WALLWORK, M.D., Physician to Addenbrooke's Hospital, and Downing Professor of Medicine, Cambridge University; 17, Trumpington-street, Cambridge.

1876 LAW, WILLIAM THOMAS, M.D., 9, Norfolk-crescent, Hyde-park, W.

1883 LAWFORD, JOHN BOWRING, M.D., C.M., Assistant Ophthalmic Surgeon to St. Thomas's Hospital; 55, Queen Anne-street, W.

1853 LAWRENCE, HENRY JOHN HUGHES, Picton House, Llandowror, St. Clears. (C. 1873-5.)

1887 LAWSON, BERNARD.

1859 LAWSON, GEORGE, Surgeon Oculist to H.M. the Queen, Surgeon to the Middlesex Hospital, and Surgeon to the Royal London Ophthalmic Hospital, Moorfields; 12, Harley-street, Cavendish-square, W. (C. 1870-1. V.-P. 1884-5.)

1879 LAYCOCK, GEORGE LOCKWOOD, M.B., Melbourne, Victoria, Australia.

1875 LEDIARD, HENRY AMBROSE, M.D., Surgeon to the Cumberland Infirmary; 41, Lowther-street, Carlisle.

1852 LEE, HENRY, Consulting Surgeon to St. George's Hospital; 9, Savile-row, W. (C. 1860-2. V.-P. 1875-6.)

1879 LEECH, DANIEL JOHN, M.D., 96, Mosley-street, Manchester.

1877 LEES, DAVID B., M.D., Physician to St. Mary's Hospital, and Assistant Physician to the Hospital for Sick Children; 22, Weymouth-street, Portland-place, W.

1867 LEES, JOSEPH, M.D., 21, Brixton-road, S.W.

1877 LEESON, JOHN RUDD, M.D., C.M., 6, Clifden-road, Twickenham.

1868 LEGG, JOHN WICKHAM, M.D. (C. 1874-5.)

Digitized by Google

Elected

1884 LEONARD, HENRY JAMES, M.B., 279, Camden-road, N.

1861 LICHTENBERG, GEORGE, M.D., 47, Finsbury-square, E.C.

1889 LIGHT, EDWIN MELLOR, M.B., B.C., St. Thomas's Hospital, Albert Embankment, S.E.

1875 LINGARD, ALFRED, 1, St. Ermin's Mansions, Westminster, S.W.

1877 LISTER, Sir JOSEPH, Bart., D.C.L., LLD., F.R.S., Professor of Clinical Surgery at King's College, and Surgeon to King's College Hospital; 12, Park-crescent, Regent's-park, W. (C. 1880-2. V.-P. 1887-8.)

1878 LITTLEJOHN, SALTER G., M.B., C.M., Central London District Schools, Hanwell.

1889 LITTLE, JOHN FLETCHER, M.B., 60, Welbeck-street, Cavendish-square, W.

L1862 LITTLE, LOUIS S., China. [18, Park-street.]

1874 LIVEING, EDWARD, M.D., 52, Queen Anne-street, Cavendish-square, W.

L1863 LIVEING, ROBERT, M.D., Consulting Physician to the Skin Department at the Middlesex Hospital; 11, Manchester-square, W. (C. 1876.)

1882 LOCKWOOD, C. B., Demonstrator of Anatomy at St. Bartholomew's Hospital; 19, Upper Berkeley-street, W.

1876 LONGHURST, ARTHUR EDWIN TEMPLE, M.D., 22, Wilton-street, Grosvenor-place, S.W. (C. 1885-7.)

1881 LUBBOCK, MONTAGU, M.D., Assistant Physician to Charing Cross Hospital, and to the Hospital for Sick Children, Great Ormond-street; 19, Grosvenor-street, W.

1873 LUCAS, R. CLEMENT, M.B., M.S., Surgeon to, and Lecturer on Anatomy at, Guy's Hospital, Senior Surgeon to the Evelina Hospital for Sick Children; 18, Finsbury-square, E.C. (C. 1883-5.)

1880 LUND, EDWARD, Consulting Surgeon to the Royal Infirmary; 22, St. John-street, Manchester.

1879 LUNN, JOHN REUBEN, Resident Medical Officer, New Marylebone Infirmary; Rackham-street, Ladbroke-grove-road, Notting-hill, W.

1887 LYON, THOMAS GLOVER, M.D., 39, King-street, Cheapside, E.C.

1871 MACCARTHY, JEREMIAH, M.A., Surgeon to the London Hospital; 15, Finsbury-square, E.C. (C. 1878-80.)

1873 MCCONNELL, J. F.

1871 MAC CORMAC, Sir WILLIAM, Surgeon to St. Thomas's Hospital; 13, Harley-street, W. (C. 1878-80.)

1873 MACKELLAR, PETER H., M.B. [care of Mr. John Smith, 4, Hargwynne-street, Stockwell, S.W.

1882 MACKENZIE, FREDERIC MORELL, 29, Hans-place, S.W.

1870 MACKENZIE, GEORGE WELLAND, 13, William-street, Lowndes-square, S.W.

1885 MACKENZIE, HECTOR GAVIN, St. Thomas's Hospital, S.E.

1870 MACKENZIE, JOHN T., Bombay, India.

Digitized by Google

Elected

1864 Mackenzie, Sir Morell, M.D., Physician to the Hospital for Diseases of the Throat, and Lecturer on Diseases of the Throat at the London Hospital; 19, Harley-street, Cavendish-square, W.

1878 Mackenzie, Stephen, M.D., Physician to, and Lecturer on Medicine at, the London Hospital; 18, Cavendish-square, W.

1879 Maclagan, Thomas John, M.D., 9, Cadogan-place, Belgrave-square, S.W.

1865 MacLaurin, Henry Normand, M.D., 187, Macquarie-street, Sydney, New South Wales.

1879 MacMahon, James Thomas, 65, Judd-street, Brunswick-square, W.C.

1876 Macnamara, Charles, Surgeon to the Westminster Hospital, and to the Royal Westminster Ophthalmic Hospital; 18, Grosvenor-street, W.

1879 Macready, Jonathan Forster, 51, Queen Anne-street.

1885 Maguire, Robert, M.D., 4, Seymour-street, Portman-square, W.

1877 Makins, George Henry, Assistant Surgeon to the Evelina Hospital for Children; 2, Queen-street, May Fair, W. (C. 1889.)

1887 Malcolm, John David, M.B., C.M., Surgeon in charge of out-patients Samaritan Free Hospital; 24, Bryanston-street, Portman-square, W.

1876 Maples, Reginald, Kingsclere, near Newbury.

1868 Marsh, F. Howard (V.-P. 1889), Assistant Surgeon to St. Bartholomew's Hospital; 30, Bruton-street, Berkeley-square, W. (C. 1876-7.)

1846 Marshall, John, F.R.S., Consulting Surgeon to University College Hospital, 10, Savile-row, W. (C. 1861.)

1856 Martin, Robert, M.D., Consulting Physician to St. Bartholomew's Hospital; 51, Queen Anne-street, Cavendish-square, W. (C. 1871-2.)

1887 Martin, Sidney, M.D., B.S., 10, Mansfield-street, Portland-place, W.

1867 Mason, Philip Brookes, Burton-on-Trent.

1884 Maudsley, Henry Carr, M.D., 11, Spring-street, Melbourne, Victoria.

L1852 May, George, Jun., M.B., Surgeon, Royal Berkshire Hospital, Reading.

1888 May, W. P., M.B., B.S., Goldburn, Eltham Road, Blackheath.

1881 Maylard, Alfred Ernest, M.B., Lecturer on Anatomy, Western Medical School, Glasgow; 4, Berkeley-terrace, Glasgow.

1874 Meredith, William Appleton, M.B., Surgeon to the Samaritan Hospital; 6, Queen Anne-street, Cavendish-square, W.

1859 Messer, John Cockburn, M.D., Assistant Surgeon R.N.

1866 Mickley, George, M.A., M.B., St. Luke's Hospital, Old-street, E.C.

1877 Milner, Edward, Surgeon to the Lock Hospital; 32, New Cavendish-street, Portland-place, W.

1882 Money, Angel, M.D., Assistant Physician to University College Hospital, and to the City of London Hospital for Disease of the Chest, Victoria-park; 24, Harley-street, Cavendish-square, W.

1879 Moore, Norman, M.D., Assistant Physician, Warden of the College, and Lecturer on Pathology at St. Bartholomew's Hospital; The Warden's House, St. Bartholomew's Hospital, E.C. (C. 1885-7.)

1881 Moore, Thomas, 6, Lee-terrace, Blackheath, S.E.

1847 Morgan, John, 3, Sussex-place, Hyde-park-gardens, W. (C. 1856-8.)

Digitized by Google

Elected

1875 MORGAN, JOHN H., Surgeon to the Charing Cross Hospital, and to the Hospital for Sick Children, Great Ormond-street; 68, Grosvenor-street, W. (C. 1886-8.)

1874 MORISON, ALEXANDER, M.D., C.M., Dunnottar, 115, Green-lanes, Highbury, N.

1880 MORISON, BASIL GORDON, M.B., C.M., 70, Marquess-road, Canonbury, N.

1869 MORRIS, HENRY, M.A., M.B. (V.-P.), Surgeon to, and Lecturer on Surgery at, the Middlesex Hospital; 2, Mansfield-street, Portland-place, W. (C. 1877-9, 1884-6. S. 1881-3. V.-P. 1888.)

1879 MORRIS, MALCOLM ALEXANDER, Surgeon to the Skin Department at St. Mary's Hospital; 8, Harley-street, Cavendish-square, W.

1875 MORTON, JOHN, M.B., Guildford.

1884 MOTT, FREDERICK WALKER, M.D., Lecturer on Physiology, Charing Cross Hospital; Meadowlead, Gayton-road, Harrow.

1879 MOULLIN, CHARLES W. MANSELL, M.D., Surgeon to the London Hospital; 69, Wimpole-street, Cavendish-square, W.

1878 MUMFORD, WILLIAM LUGAR, M.D., 1, Bartlett's-passage, Holborn-circus, E.C.

1876 MUNRO, WILLIAM, M.D., C.M., 102, Carl-street, Lower Broughton-road, Manchester.

1885 MURRAY, HUBERT MONTAGUE, M.D., Assistant Physician to, and Lecturer on Pathology and Morbid Anatomy at, Charing Cross Hospital, 27, Savile-row, W.

1864 MYERS, ARTHUR B. R., Brigade-Surgeon, Brigade of Guards; 43, Gloucester-street, Warwick-square, S.W. (C. 1872-3.)

1882 MYERS, A. T., M.D., 9, Lower Berkeley-street, Portman-square, W.

1887 MYERS, W. H., Fort Wayne, Indiana, U.S.A.

1874 NANKIVELL, ARTHUR WOLCOT, St. Bartholomew's Hospital, Chatham.

1887 NASON, EDWARD NOEL, M.B., The General Hospital, Birmingham.

1873 NETTLESHIP, EDWARD, Ophthalmic Surgeon to St. Thomas's Hospital, and Assistant Surgeon to the Royal London Ophthalmic Hospital; 5, Wimpole-street, Cavendish-square, W. (C. 1882-4.)

1875 NEWBY, CHARLES HENRY, 15, Landport-terrace, Southsea, Hants.

1865 NEWMAN, WILLIAM, M.D., Stamford, Lincolnshire.

1868 NICHOLLS, JAMES, M.D., Trenarren, Newquay, Cornwall.

1876 NICHOLSON, JOHN FRANCIS, M.D., Physician to the Hull General Infirmary; 29, Albion-street, Hull.

1878 NOOTT, W. M., 8, Kensington-park-road, W.

L1864 NORTON, ARTHUR T., Surgeon to St. Mary's Hospital; 101, Harley-street, Cavendish-square, W. (C. 1877-9.)

1883 NORVILL, FREDERIC HARVEY, M.B., Summerland, Yeovil, Somersetshire.

1856 NUNN, THOMAS WILLIAM, Consulting Surgeon to the Middlesex Hospital; 8, Stratford-place, Oxford-street, W. (C. 1864-6. V.-P. 1878-80.)

Digitized by Google

Elected

1871 NUNNELEY, Rev. FREDERICK BARHAM, M.D.

1880 O'CONNOR, BERNARD, M.D., Physician to the North London Consumption Hospital, and Physician to the Westminster General Dispensary; Greenhill-park, Harlesden, N.W.

1873 O'FARRELL, GEORGE PLUNKETT, M.B., 19, Fitzwilliam-square, Dublin.

1880 OGILVIE, GEORGE, M.B., Lecturer on Experimental Physics at the Westminster Hospital; 22, Welbeck-street, Cavendish-square, W.

1880 OGILVIE, LESLIE, M.B., Physician to the Children's Hospital, Paddington-green; 46, Welbeck-street, Cavendish-square, W.

1850 OGLE, JOHN W., M.D., Consulting Physician to St. George's Hospital; 30, Cavendish-sq., W. (C. 1855-6. S. 1857-60. C. 1861-3. V.-P. 1865-8.)

1876 OLIVER, JOHN FERENS, M.D., 12, Old Elvet, Durham.

1888 OPENSHAW, THOMAS HORROCKS, M.B., B.S., 21, Gower-street, W.C.

1860 ORANGE, WILLIAM, M.D., 35, Cromwell-road, Brighton.

1875 ORD, WILLIAM MILLER, M.D., Physician to, and Lecturer on Medicine at, St. Thomas's Hospital; 37, Upper Brook-street, Grosvenor-square W. (C. 1880-2.)

1879 ORMEROD, J. A., M.D., Assistant Physician to the National Hospital for the Paralysed and Epileptic, Queen-square, and to the City of London Hospital for Diseases of the Chest, Victoria-park; 25, Upper Wimpole-street, W. (C. 1887-8.)

1881 OWEN, ISAMBARD, M.D., Assistant Physician to St. George's Hospital; 5, Hertford-street, Mayfair, W.

1865 OWLES, JAMES ALLDEN, M.D., Hill View, Woking, Surrey.

1875 PAGE, HERBERT WILLIAM, M.A., M.C. Cantab., Surgeon to, and Joint Lecturer on Surgery at, St. Mary's Hospital; 146, Harley-street, Cavendish-square, W. (C. 1889.)

1870 PAGET, Sir JAMES, Bart., D.C.L., LL.D., F.R.S., Consulting Surgeon to St. Bartholomew's Hospital; 1, Harewood-place, Hanover-square, W. (P. 1887-8.)

1884 PAGET, STEPHEN, 57, Wimpole-street, Cavendish-square, W.

1872 PARKER, ROBERT WILLIAM, Surgeon to the East London Children's Hospital; 8, Old Cavendish-street, W. (C. 1881-3.)

1874 PARKER, RUSHTON, M.B., B.S., Professor of Surgery in University College, Liverpool, and Surgeon to the Royal Infirmary; 59, Rodney-street, Liverpool.

1853 PARKINSON, GEORGE, 50, Brook-street, Grosvenor-square, W.

1882 PASTEUR, WILLIAM, M.D., Medical Registrar to the Middlesex Hospital; 19, Queen-street, Mayfair, W.

1885 PAUL, FRANK THOMAS, 44, Rodney-street, Liverpool.

1865 PAVY, FREDERICK WILLIAM, M.D., F.R.S., Senior Physician to Guy's Hospital; 35, Grosvenor-street, W. (C. 1872-4.)

Digitized by Google

Elected

1868 PAYNE, JOSEPH FRANK, M.D. (V.-P.), Physician to, and Lecturer on Pathological Anatomy at, St. Thomas's Hospital; 78, Wimpole-street, Cavendish-square, W. (C. 1873-5, 1883-5. S. 1880-2. V.-P. 1888.)

1872 PEARCE, JOSEPH CHANING, M.D., C.M., Montague House, St. Lawrence-on-Sea, Kent.

1878 PEARSE, THOMAS FREDERICK, M.D.

1863 PEARSON, DAVID R., M.D., 23, Upper Phillimore-place, Kensington, W.

1884 PEDLEY, F. NEWLAND, 32, Devonshire-place, Portland-place, W.

1879 PEEL, ROBERT, 130, Collins-street East, Melbourne, Victoria.

1887 PENROSE, FRANCIS GEORGE, M.D., Assistant Physician, St. George's Hospital; 24, Clarges-street, Piccadilly, W.

1884 PEPPER, AUGUSTUS JOSEPH, M.B., C.M., Surgeon to St. Mary's Hospital; 13, Wimpole-street, Cavendish-square, W.

1888 PERRY, EDWIN COOPER, M.B., Guy's Hospital S.E.

1878 PHILIPPS, SUTHERLAND REES, M.D., St. Ann's-heath, Virginia-water, Chertsey.

1871 PHILLIPS, CHARLES DOUGLAS F., M.D., 10, Henrietta-street, Cavendish-square, W.

1878 PHILLIPS, JOHN WALTER, Physician to the Benevolent Asylum of Melbourne; 30, Stanley-street, West Melbourne, Victoria.

1863 PICK, THOMAS PICKERING, Surgeon to, and Lecturer on Anatomy at, St. George's Hospital; 18, Portman-street, Portman-square, W. (C. 1870-1. V.-P. 1885-7.)

1867 PITT, EDWARD G., M.D.

1884 PITT, GEORGE NEWTON, M.D., Assistant Physician and Pathologist at Guy's Hospital; 10, St. Thomas's-street, Southwark, S.E.

1876 PITTS, BERNARD, M.A., M.B., Assistant Surgeon to St. Thomas's Hospital; 31, Harley-street, Cavendish-square, W. (C. 1888.)

1887 PITTS, ROBERT ZACCHEUS, Springfield, Chelmsford.

1886 POCOCK, WALTER, 374, Brixton-road, S.W.

1883 POLAND, JOHN, Demonstrator of Anatomy at Guy's Hospital; 16, St. Thomas's-street, Southwark, S.E.

1882 POLLARD, BILTON, Assistant Surgeon and Surgical Registrar, University College Hospital; 24, Harley-street, Cavendish-square, W.

L1846 POLLOCK, GEORGE D. (TRUSTEE), Consulting Surgeon to St. George's Hospital; 36, Grosvenor-street, W. (S. 1850-3. C. 1854-6. V.-P. 1863-5. P. 1875-6.)

1850 POLLOCK, JAMES EDWARD, M.D., Physician to the Hospital for Consumption and Diseases of the Chest, Brompton; 52, Upper Brook-street, W. (C. 1862-4. V.-P. 1879-81.)

1870 POORE, GEORGE VIVIAN, M.D., Physician to University College Hospital; 30, Wimpole-street, W. (C. 1883-5.)

Digitized by Google

Elected

1876 Port, Heinrich, M.D., 48, Finsbury-square, E.C.

L1879 Potter, Henry Percy, St. Mary Abbotts' Infirmary, Marloes-road, Kensington, W.

1881 Powell, Henry Albert, M.A., 1, The Avenue, Beckenham, Kent.

1866 Powell, Richard Douglas, M.D., Physician to, and Lecturer on Practical Medicine at, the Middlesex Hospital; 62, Wimpole-street, Cavendish-square, W. (C. 1873-5, 1881-3. S. 1877-9. V.-P. 1887-8.)

1865 Power, Henry, Ophthalmic Surgeon to St. Bartholomew's Hospital; 37A, Great Cumberland-place, Hyde-park, W. (C. 1876-7.)

1884 Power, D'Arcy, M.A., M.B., Demonstrator of Practical Surgery at St. Bartholomew's Hospital, and Surgeon to Out-patients, Victoria Hospital for Children; 26, Bloomsbury-square, W.C.

1887 Pratt, William Sutton, Weedon, Northamptonshire.

1884 Price, J. A. P., M.D., 41, Castle-street, Reading.

1888 Priestley, R. C., M.B., 65, Upper Berkeley-street, W.

1856 Priestley, William Overend, M.D., Consulting Physician-Accoucheur to King's College Hospital, and to the St. Marylebone Infirmary; 17, Hertford-street, Mayfair, W.

1888 Primrose, Alexander, M.B., C.M. 243, Simcoe-street, Toronto, Canada.

1882 Pringle, J. J., M.B., Assistant Physician to, and Physician in Charge of Skin Department at, the Middlesex Hospital, and Physician to the Royal Hospital for Diseases of the Chest; 35, Bruton-street, Mayfair, W.

L1848 Purnell, John James, Surgeon to the Royal General Dispensary; Woodlands, Streatham-hill, S.W. (C. 1858-61.)

1865 Pye-Smith, Philip Henry, M.D., F.R.S., Physician to, and Lecturer on Medicine at, Guy's Hospital; 54, Harley-street, Cavendish-square, W. (C. 1874-7.)

O.M. Quain, Richard, M.D., LL.D., F.R.S. (Trustee), Physician Extraordinary to H.M. the Queen, Consulting Physician to the Hospital for Consumption and Diseases of the Chest, Brompton; 67, Harley-street, Cavendish-square, W. (C. 1846-51. S. 1852-6. T. 1857-68. *Pres.* 1869-70. V.-P. 1871-3.)

1884 Rake, Beaven Neave, M.D., Government Medical Officer, and Medical Superintendent of the Leper Asylum, Trinidad.

1872 Ralfe, Charles Henry, M.D., M.A., Assistant Physician to the London Hospital; 26, Queen Anne-street, W. (C. 1877-9.)

1857 Ramskill, J. Spence, M.D., Consulting Physician to the London Hospital, Physician to the National Hospital for the Paralysed and Epileptic; 5, St. Helen's-place, Bishopsgate-street, E.C.

L1848 Randall, John, M.D., Medical Officer, St. Marylebone Infirmary; 204, Adelaide-road, N.W. (C. 1864-6.)

1857 Ranke, Henry, M.D., Munich.

Digitized by Google

Elected

1865 Rasch, Adolphus A., M.D., Physician for Diseases of Women to the German Hospital; 7, South-street, Finsbury-square, E.C.

1887 Raven, Thomas Francis, Broadstairs, Kent.

1870 Ray, Edward Reynolds, Dulwich, S.E.

1871 Rayner, Henry, M.D., Lecturer on Mental Diseases at St. Thomas's Hospital, Medical Superintendent, Middlesex County Lunatic Asylum, Hanwell, W.

1858 Reid, Frederick George, M.D., 46, Hertford-street, Mayfair, W.

1866 Reeves, Henry Albert, Assistant Surgeon to the London Hospital; 7, Grosvenor-street, W.

1875 Reid, Robert William, M.D., C.M., Lecturer on Anatomy at St. Thomas's Hospital; 77, Lambeth Palace-road, S.E.

1881 Renner, William, M.R.C.S., Wilberforce-street, Free Town, Sierra Leone.

1854 Reynolds, J. Russell, M.D., F.R.S., Consulting Physician to University College Hospital; 38, Grosvenor-street, W. (C. 1868-9.)

1871 Richards, J. Peeke, Medical Superintendent, Middlesex County Lunatic Asylum, Hanwell, W.

1888 Ricketts, Edwin, M.D.

1866 Rivington, Walter, M.S. Lond., Surgeon to the London Hospital; 22, Finsbury-square, E.C.

‡1865 Roberts, David Lloyd, M.D., Physician to St. Mary's Hospital, Manchester; 11, St. John's-street, Manchester.

1871 Roberts, Frederick Thomas, M.D., Professor of Materia Medica at University College, and Physician to University College Hospital and to the Hospital for Consumption, &c., Brompton; 102, Harley-street, Cavendish-square, W. (C. 1883-5.)

1878 Roberts, William Howland, M.D., Surgeon, Madras Army.

1888 Robertson, Robert, M.D., The Bungalow, Ventnor, Isle of Wight.

1885 Robinson, Arthur Henry, M.D., Mile End Infirmary, Bancroft-road, E.

1887 Robinson, Henry Betham, M.B., Resident Assistant Surgeon, St. Thomas's Hospital, S.E.

1882 Robinson, Tom, M.D., 9, Princes-street, Cavendish-Square, W.

1888 Rolleston, H. D., M.B., 7. Furnival's Inn, E.C.

1858 Rose, Henry Cooper, M.D., Surgeon to the Hampstead Dispensary; Penrose House, Hampstead, N.W. (C. 1873-4.)

1876 Rose, William, M.B., B.S., Professor of Surgery at King's College, Surgeon to King's College Hospital; 17, Harley-st., Cavendish-square, W.

1879 Ross, James, M.D., C.M., 335, Oxford-street, Manchester.

1875 Rossiter, George Frederick, Cairo Lodge, Weston-super-Mare.

1877 Roth, Bernard, 29, Queen Anne-street, Cavendish-square, W., and Rossmore, Preston-road, Brighton.

1888 Roughton, Edmund Wilkinson, 28, Welbeck-street, W.

1858 Rouse, James, Surgeon to St. George's Hospital; 2, Wilton-street, Grosvenor-place, S.W.

Digitized by Google

Elected

1881 Routh, Amand Jules McConnel, M.D., B.S., Assistant Physician Accoucheur to the Charing Cross Hospital, and Physician to the Samaritan Free Hospital; 14a, Manchester-square, W.

1887 Roy, Charles Stuart, M.D., Professor of Pathology, Cambridge.

1869 Rutherford, William, M.D., F.R.S., Professor of Physiology in the University of Edinburgh; 14, Douglas-crescent, Edinburgh.

1882 Sainsbury, Harrington, M.D., Physician to the Royal Free Hospital, and Assistant Physician, City of London Hospital for Diseases of the Chest; 63, Welbeck-street, W.

1853 Salter, S. James A., M.B., F.R.S. Late Dental Surgeon to Guy's Hospital; Basingfield, near Basingstoke, Hants. (C. 1861-3. V.-P. 1880-2.)

L1852 Sanderson, Hugh James, M.D., 26, Upper Berkeley-street, Portman-square, W.

1854 Sanderson, John Burdon, M.D., D.C.L.Durham, F.R.S., Waynflete Professor of Physiology at the University of Oxford; 50, Banbury-road, Oxford. (C. 1864-7. V.-P. 1873-4.)

1875 Sangster, Charles, 148, Lambeth-road, S.E.

1877 Sankey, H. R. O., County Asylum, Prestwich, Manchester.

1886 Saundby, Robert, M.D., Physician to the General Hospital, and Consulting Physician to the Hospital for Women, and to the Eye Hospital, Birmingham; 83a, Edmund-street, Birmingham.

1871 Saunders, Charles Edward, M.D., Sussex County Lunatic Asylum, Hayward's Heath.

1873 Savage, George Henry, M.D., 3, Henrietta-street, Cavendish-square, W. (C. 1881-3.)

1882 Savill, Thomas Dixon, M.D., Paddington Infirmary, 285. Harrow-road, W.

1877 Semon, Felix, M.D., Assistant Physician for Diseases of the Throat to St. Thomas's Hospital; 39, Wimpole-street, Cavendish-square, W. (C. 1885-7.)

L1852 Semple, Robert Hunter, M.D., Physician to the Bloomsbury Dispensary; 8, Torrington-square, W.C. (C. 1859-61.)

1872 Sergeant, Edward, Medical Officer of Health, Town Hall, Bolton, Lancashire.

1876 Sharkey, Seymour J., M.D., Assistant Physician and Demonstrator of Morbid Anatomy to St. Thomas's Hospital; 2, Portland-place, W. (C. 1884-6.)

1880 Shattock, S. G., Lecturer on, and Demonstrator of, Surgical Pathology, and Curator of Museum, St. Thomas's Hospital; 4, Crescent-road, the Downs, Wimbledon. (C. 1885-7.)

1885 Shaw Lauriston Elgie, M.D., Assistant Physician, Medical Registrar and Demonstrator of Practical Medicine, Guy's Hospital; 15, St. Thomas's-street, Southwark, S.E.

1884 Sheild, Arthur Marmaduke, M.B., B.S., Assistant Surgeon to the Charing Cross Hospital; 20, Stratford-place, Oxford-street, W.

1886 Sherrington, C. S., M.B., Gonville and Caius College, Cambridge.

Digitized by Google

Elected

1856 SHILLITOE, BUXTON, Surgeon to the Great Northern Hospital, and to the Lock Hospital; 2, Frederick's-place, Old Jewry, E.C.

L1855 SIBLEY, SEPTIMUS W., 7, Harley-street, Cavendish-square, W. (C. 1863-5. V.-P. 1879-81.)

1887 SIBLEY, WALTER KNOWSLEY, 7, Harley-street, Cavendish-square, W.

1875 SIDDALL, JOSEPH BOWER, M.D., C.M. [care of G. Siddall, Esq., Matlock, Derbyshire].

1880 SILCOCK, A. QUARRY, M.D., B.S., Surgeon in charge of Out-patients, St. Mary's Hospital, and Assistant Surgeon, Royal London Ophthalmic Hospital, Moorfields; 52, Harley-street, Cavendish-square, W. (C. 1888.)

1866 SIMS, FRANCIS MANLEY BOLDERO, 12, Hertford-street, Mayfair, W.

1887 SMALLPEICE, WILLIAM DONALD, 42, Queen Anne's-gate, S.W.

‡1875 SMEE, ALFRED HUTCHINSON, The Grange, Hackbridge, Carshalton, Surrey.

1879 SMITH, E. NOBLE, Senior Surgeon, and Surgeon to the Orthopædic Department of the Farringdon Dispensary, and Orthopædic Surgeon to the British Home for Incurables; 24, Queen Anne-street, Cavendish-square.

1887 SMITH, FREDERICK JOHN, M.B., 7, West-street, Finsbury-circus, E.C.

1875 SMITH, GEORGE JOHN MALCOLM, M.B., Hurstpierpoint, Sussex.

1872 SMITH, GILBART, M.D., Assistant Physician to the London Hospital, Physician to the Royal Hospital for Diseases of the Chest, City-road, Visiting Physician to the Margaret-street Infirmary for Consumption; 68, Harley-street, Cavendish-square, W.

1878 SMITH, HERBERT URMSON, M.B., Cape Colony.

1873 SMITH, RICHARD T., M.D., Physician to the St. Pancras Dispensary; 53, Haverstock-hill, N.W.

1883 SMITH, ROBERT PERCY, M.D., Bethlem Royal Hospital, St George's Road, S.E.

1869 SMITH, ROBERT SHINGLETON, M.D., Lecturer on Physiology, Bristol Medical School; Deepholm, Clifton Park, Bristol.

1856 SMITH, THOMAS, Surgeon to St. Bartholomew's Hospital; 5, Stratford-place, Oxford-street, W. (C. 1867-9. V.-P. 1877-8.)

1866 SMITH, WILLIAM, Melbourne, Australia.

1870 SMITH, WILLIAM JOHNSON, Surgeon, Seamen's Hospital, Greenwich, S.E. (C. 1879-81.)

L1869 SMITH, WILLIAM WILBERFORCE, M.D., 14, Stratford-place, W.

1870 SNOW, WILLIAM VICARY, M.D., Richmond Gardens, Bournemouth.

1888 SOLLY, ERNEST, M.B., St. Thomas's Hospital, Albert Embankment, S.E.

1868 SOUTHEY, REGINALD, M.D., Commissioner in Lunacy; 32, Grosvenor-road, Pimlico. (C. 1882-4.)

Digitized by Google

Elected

1887 SPENCER, WALTER GEORGE, M.B., Assistant Surgeon to Westminster Hospital; 94, Wimpole-street, Cavendish-square, W.

1888 SPICER, ROBERT HENRY SCANES, M.D., Physician to the Department for Diseases of the Throat, St. Mary's Hospital; 28, Welbeck-street, Cavendish-square, W.

1868 SPRY, G. FREDERICK HUME, M.D., Surgeon-Major 2nd Life Guards, Regent's-park Barracks, N.W.

1861 SQUIRE, ALEXANDER BALMANNO, M.B., 24, Weymouth-street, Portland-place, W.

1885 SQUIRE, JOHN EDWARD, M.D., Physician to North London Consumptive Hospital, 23, Seymour-street, Portman-square, W.

1889 STEWART, EDWARD, M.D., 8, Upper Wimpole-street, Cavendish-square, W.

L1854 STEWART, WILLIAM EDWARD, 16, Harley-street, Cavendish-square, W.

1879 STIRLING, EDWARD CHARLES, Adelaide, South Australia [care of T. Gemmell, Esq., 11, Essex-street, Strand, W.C.].

1883 STOKER, GEORGE, Surgeon for Out-patients, Hospital for Diseases of the Throat and Chest, Golden-square; 14, Hertford-street, Mayfair, W.

1881 STOKES, HENRY FRASER, 2, Highbury-crescent, N.

1884 STONHAM, CHARLES, Curator of the Anatomical Museum, University College, London, and Assistant Surgeon to the Westminster Hospital; 62, Welbeck-street, Cavendish-square, W.

1875 STURGE, W. A., M.D., 29, Boulevard Dubouchage, Nice.

L1871 SUTHERLAND, HENRY, M.D., 6, Richmond-terrace, Whitehall, S.W.

1864 SUTTON, HENRY G., M.B. (V.-P. 1889), Physician to, and Lecturer on Pathology at, the London Hospital; 9, Finsbury-square, E.C. (C. 1875-6.)

1882 SUTTON, JOHN BLAND, Assistant Surgeon to, and Lecturer on Comparative Anatomy at, the Middlesex Hospital; 48, Queen Anne-street, W. (C. 1887-9.)

‡1867 SWAIN, WILLIAM PAUL, 17, The Crescent, Plymouth.

1881 SYMONDS, CHARTERS JAMES, M.S. (C.), Assistant Surgeon to Guy's Hospital, and to the Evelina Hospital for Sick Children; 26, Weymouth-street, Portland-place, W. (C. 1886-8.)

1870 TAIT, ROBERT LAWSON, Surgeon to the Birmingham and Midland Hospital for Women; 7, The Crescent, Birmingham.

1886 TARGETT, JAMES HENRY, M.B., M.S., Assistant Pathologist, College of Surgeons, Guy's Hospital, S.E.

1864 TATHAM, JOHN, M.D., Physician to the Hospital for Consumption and Diseases of the Chest, Brompton; 12, George-st., Hanover-sq., W.

1870 TAY, WARREN, Surgeon to, and Demonstrator of Practical Anatomy at, the London Hospital; 4, Finsbury-square, E.C. (C. 1881-2.)

1885 TAYLOR, HENRY H., Hospital for Consumption, Brompton, S.W.

1871 TAYLOR, FREDERICK, M.D., Physician to, and Lecturer on Medicine at, Guy's Hospital, and Physician to the Evelina Hospital for Sick Children; 11, St. Thomas's-street, S.E. (C. 1879-81.)

Digitized by Google

Elected

1880 TAYLOR, SEYMOUR, M.D., M.C., Assistant Physician to the West London Hospital; 16, Seymour-street, Portman-square, W.

1879 THIN, GEORGE, M.D., 22, Queen Anne-street, Cavendish-square, W. (C. 1889),

1870 THOMAS, JOHN DAVIES, M.D., Lecturer on Medicine in the University of Adelaide, 52, North-terrace, Adelaide, South Australia [care of Mr. H. K. Lewis, Gower-street].

1852 THOMPSON, Sir HENRY, Knt., Emeritus Professor of Clinical Surgery in University College; 35, Wimpole-street, Cavendish-square, W. (S. 1859-63. C. 1865-67. V.-P. 1868-70.)

1884 THOMSON, JOHN, M.B., C.M., 18, Walker-street, Edinburgh.

1874 THORNTON, JOHN KNOWSLEY, M.B., Surgeon to the Samaritan Free Hospital for Women and Children; 22, Portman-street, Portman-square, W.

1872 THORNTON, WILLIAM PUGIN, 35, St. George's-road, Canterbury.

1865 THOROWGOOD, J. C., M.D., Lecturer on Materia Medica at the Middlesex Hospital, Physician to the City of London Hospital for Diseases of the Chest; 61, Welbeck-street, W. (C. 1876-78.)

1880 TIBARD, NESTOR ISIDORE, M.D., Professor of Materia Medica at King's College, London; Assistant Physician, King's College Hospital, and to the Evelina Hospital for Sick Children; 28, Weymouth-street, Portland-place.

1884 TIVY, WILLIAM JAMES, 8, Lansdowne-place, Clifton, Bristol.

1856 TOMES, Sir JOHN, F.R.S., Consulting Dental Surgeon to the Middlesex Hospital; Upwood Gorse, Caterham, Surrey. (C. 1867-9.)

1864 TONGE, MORRIS, M.D., Harrow-on-the-hill, Middlesex.

1882 TOOTH, H. H., M.D., Assistant Demonstrator of Practical Physiology, St. Bartholomew's Hospital; 34, Harley-street, Cavendish-square, W.

1886 TOTSUKA, KANKAI.

L1872 TOWNSEND, THOMAS SUTTON, 68, Queen's Gate, South Kensington, S.W.

1888 TREVELYAN, E. F., M.D., Seamen's Hospital, Greenwich, S.E.

1881 TREVES, FREDERICK, Surgeon to, and Lecturer on Anatomy at, the London Hospital; 6, Wimpole-street, Cavendish-square, W. (C. 1887-8.)

1851 TROTTER, JOHN W., Surgeon-Major, Coldstream Guards; Bossall Vicarage, York. (C. 1865-9.)

1859 TRUMAN, EDWIN THOMAS, Surgeon-Dentist in Ordinary to Her Majesty's Household; 23, Old Burlington-street, W.

1888 TUBBY, ALFRED HERBERT, M.B., 63, Studley-road, Clapham.

1867 TUCKWELL, HENRY MATTHEWS, M.D., late Physician to the Radcliffe Infirmary; 64, High-street, Oxford.

1858 TUDOR, JOHN, Dorchester, Dorset.

L1875 TURNER, FRANCIS CHARLEWOOD, M.D., Physician to the London Hospital; 15, Finsbury-square, E.C. (C. 1884-6.)

1882 TURNER, GEORGE ROBERTSON, Visiting Surgeon, Seamen's Hospital, Greenwich; Assistant Surgeon to, and Joint Lecturer on Practical Surgery at, St. George's Hospital; 49, Green-street, Park-lane.

Digitized by Google

Elected.

1863 TURNER, JAMES SMITH, Consulting Dental Surgeon to the Middlesex Hospital; 12, George-street, Hanover-square, W.

1858 TURTLE, FREDERICK, Clifton Lodge, Woodford, Essex.

1880 TYSON, WILLIAM JOSEPH, M.D., Medical Officer of the Folkestone Infirmary; 10, Langhorne-gardens, Folkestone.

L1854 VASEY, CHARLES, 112, Cambridge-gardens, Notting-hill, W.

1867 VENNING, EDGCOMBE, 30, Cadogan-place, S.W.

L1867 WAGSTAFFE, WILLIAM WARWICK, B.A., Purleigh, St. John's-hill, Sevenoaks. (C. 1874, 1878-80. S. 1875-7.)

O.M. WAITE, CHARLES D., M.D., Senior Physician to the Westminster General Dispensary; 3, Old Burlington-street, W.

1885 WAKLEY, THOMAS, jun., 5, Queen's-gate, S.W.

1881 WALLER, BRYAN CHARLES, M.D., Masongill House, Cowan-bridge, Kirkby-Lonsdale.

1888 WALSHAM, HUGH, M.A., M.B., B.C., 134, Harley-street, W.

1873 WALSHAM, WILLIAM JOHNSON, M.B., C.M., Assistant Surgeon to, and Demonstrator of Practical and Orthopædic Surgery at, St. Bartholomew's Hospital, Surgeon to the Metropolitan Free Hospital; 27, Weymouth-street, Portland-place. (C. 1881-3.)

1859 WALTERS, JOHN, M.B., Reigate, Surrey.

1889 WASHBOURN, JOHN WYCHENFORD, M.D., 24, Maze Pond, Borough, S.E.

1877 WATERHOUSE, CHARLES, M.B., M.C., Carl Ludwigstrasse, Währing, Vienna.

1879 WATERS, JOHN HENRY, M.D., 101, Jermyn-street, St. James's, S.W.

1880 DE WATTEVILLE, ARMAND, M.A., M.B., Physician in charge of the Electro-Therapeutical Department, St. Mary's Hospital; 30, Welbeck-street, Cavendish-square, W.

1860 WAY, JOHN, M.D., 4, Eaton-square, S.W. (C. 1873-4.)

L1858 WEBER, HERMANN, M.D., Physician to the German Hospital; 10, Grosvenor-street, Grosvenor-square, W. (C. 1867-70. V.-P. 1878-80.)

1876 WEIR, ARCHIBALD, M.D., St. Mungho's, Great Malvern.

1864 WELCH, THOMAS DAVIES, M.D., Fairmount, Frith-hill, Godalming, Surrey.

1853 WELLS, Sir THOMAS SPENCER, Bart., Consulting Surgeon to the Samaritan Free Hospital for Women and Children; 3, Upper Grosvenor-street, W. (C. 1865-8. V.-P. 1876-7.)

L1851 WEST, CHARLES, M.D., 55, Harley-street, Cavendish-square, W. (C. 1856-7.)

1877 WEST, SAMUEL, M.D. (HON. SECRETARY), Assistant Physician to St. Bartholomew's Hospital, Senior Physician to the Royal Free Hospital; 15, Wimpole-street, Cavendish-square, W. (C. 1884-6. S. 1889.)

1888 WETHERED, FRANK J., M.B., 34, Queen Anne-street, Cavendish-square, W.

Digitized by Google

Elected

1867 WHIPHAM, THOMAS TILLYER, M.B., Physician to St. George's Hospital; 11, Grosvenor-street, Grosvenor-square, W. (C. 1880-2.)

1869 WHIPPLE, JOHN H. C., M.D., Army Medical Staff.

1877 WHITE, CHARLES HAYDON, 20, Shakespeare-street, Nottingham.

1881 WHITE, WILLIAM HALE, M.D., Senior Assistant Physician to, and Lecturer on Materia Medica at, Guy's Hospital; 65, Harley-street, Cavendish-square, W. (C. 1888.)

886 WHITE, WILLIAM HENRY, M.D., Physician to the Royal Hospital for Diseases of the Chest, 43, Weymouth-street, W.

‡1868 WHITEHEAD, WALTER, 24, St. Ann's-square, Manchester.

1877 WHITMORE, WILLIAM TICKLE, 7, Arlington-street, S.W.

1870 WICKSTEED, FRANCIS WILLIAM, Chester House, Weston-super-Mare.

1879 WILCOX, HENRY, M.B., Dorchester House, Herbert-road, Woolwich.

1869 WILKIN, JOHN F., M.D., M.C., New Beckenham, Kent.

1871 WILKINSON, J. SEBASTIAN, Late Surgeon to the Central London Ophthalmic Hospital; New Zealand.

L1855 WILKS, SAMUEL, M.D., F.R.S. (TRUSTEE), Member of the Senate of the University of London, Consulting Physician to Guy's Hospital; 72, Grosvenor-street, W. (C. 1857-60. V.-P. 1869-72, 1883-5. P. 1881-2.)

1879 WILLCOCKS, FREDERICK, M.D., Assistant Physician to Charing Cross Hospital, Physician for Out-patients to the Evelina Hospital for Sick Children; 14, Mandeville-place, Manchester-square, W.

1886 WILLETT, EDGAR WILLIAM, M.B., 60, Welbeck-street, Cavendish-square, W.

1869 WILLIAMS, ALBERT, M.D. (Travelling).

‡1858 WILLIAMS, CHARLES, Surgeon to the Norfolk and Norwich Hospital; 9, Prince of Wales-road, Norwich.

1866 WILLIAMS, CHARLES THEODORE, M.D., Physician to the Hospital for Consumption and Diseases of the Chest, Brompton; 2, Upper Brook-street, Grosvenor-square, W. (C. 1875-8.)

1881 WILLIAMS, DAWSON, M.D., B.S., 25, Old Burlington-street, W.

1872 WILLIAMS, JOHN, M.D., Obstetric Physician to University College Hospital; 11, Queen Anne-street, Cavendish-square, W. (C. 1878-80.)

1881 WILLIAMS, W. ROGER, Surgical Registrar to the Middlesex Hospital.

1864 WILLIAMS, W. RHYS, M.D., 95, St. George's-road, Pimlico, S.W.

1876 WILLIAMSON, JAMES MANN, M.D., Ventnor, Isle of Wight.

1863 WILLIS, FRANCIS, M.D., The Spa, Bracebrough, Stamford.

1889 WILSON, ALBERT, Leytonstone, Essex.

1888 WILSON, CLAUDE, M.D., C.M., 6, York-road, Tunbridge Wells.

1859 WILSON, EDWARD THOMAS, M.B., Montpelier-terrace, Cheltenham.

1859 WILSON, ROBERT JAMES, 7, Warrior-square, St. Leonards-on-Sea.

‡1861 WINDSOR, THOMAS, Consulting Surgeon to the Salford Royal Hospital; Woodcroft, Dudley-road, Manchester.

1889 WINGRAVE, V. HAROLD WYATT, 3, Vernon Chambers, Southampton-row, W.C.

Digitized by Google

Elected

1874 WISEMAN, JOHN GREAVES, Dearden-street, Ossett, Yorkshire.

1865 WITHERBY, WILLIAM H., M.D., Pitt-place, Coombe, Croydon.

1850 WOOD, JOHN, F.R.S., 61, Wimpole-street, W. (C. 1857-9. V.-P. 1872-4. T. 1884-7.)

1887 WOOD, T. OUTTERSON, M.D., 40, Margaret-street, Cavendish-square, W.

1854 WOOD, WILLIAM, M.D., Physician to St. Luke's Hospital; 99, Harley-street, W.

1876 WOOD, WILLIAM EDWARD RAMSDEN, M.A., M.D., The Priory, Roehampton, S.W.

1883 WOODCOCK, JOHN ROSTRON, 155, Hagley-road, Birmingham.

1883 WOODHEAD, GERMAN SIMS, M.D., 6, Marchhall-crescent, Edinburgh.

1879 WOODWARD, G. P. M., M.D., Deputy Surgeon-General; Sydney, New South Wales.

1884 WORTS, EDWIN, 6, Trinity Street, Colchester.

1869 WYMAN, W. S., M.D., Westlands, 280, Upper Richmond-road, Putney, S.W.

1884 WYNTER, WALTER ESSEX, Templecombe, Twickenham.

1869 YEO, I. BURNEY, M.D., Physician to King's College Hospital; 44, Hertford-street, Mayfair, W.

1872 YOUNG, HENRY, M.B., Monte Video, South America.

Digitized by Google

Digitized by Google

ANNUAL REPORT OF COUNCIL, 1888-89.

PRESENTED AT THE ANNUAL MEETING, JANUARY 15TH, 1889.

As on the occasion of the presentation of the last and many previous Annual Reports, the Council has the satisfaction of congratulating the Society upon a further increase in its members, who now number 709, as compared with 691 at the same time last year. Twenty-five new members have been elected, of whom three are non-resident. One resident member has become non-resident, and one non-resident member has become resident. Two have resigned, and five members have been removed by death, viz. Dr. Houghton, Mr. Chalk, Dr. Greenhow, Mr. Dunn, and Mr. Mallam. Mr. Chalk had been a member of the Society since 1849; Dr. Greenhow had held the office of Vice-President, and his papers on 'Lung Disease in Operatives' and on 'Addison's Disease' will be long remembered.

The Council would point with satisfaction to the last volume of the 'Transactions,' as a proof of the large amount of very excellent material which has, during the last session, been brought before the Society; and would particularly call attention to the valuable papers contained in Section X, and amongst these to that of Professor Crookshank on the so-called "Hendon Cow Disease, and its Relation to Scarlatina in Man." The discussion which followed the reading of this communication was one of great interest.

At the early part of the present session an animated debate on the morbid anatomy and pathology of chronic alcoholism was introduced by Dr. Payne; it has been largely attended and well maintained.

Digitized by Google

It has been thought wise, in order to make our work more widely known, to distribute our 'Transactions' amongst various Continental and foreign schools of learning. About fifty copies are to be sent out annually, in addition to those which it has been the custom to present. It is trusted that this will be an additional incentive to our members to contribute if possible more important observations than before.

The Council has determined to recommend the adoption of a composition fee according to a sliding scale, depending upon the number of years of membership, both for the subscriptions and, in the case of resident members, for the receipt of the 'Transactions.' It is hoped that this, if adopted, will be found a convenience to members and will not entail any pecuniary loss to the Society.

The balance at the Society's bankers is £60 19*s.* 1*d.*, as compared with £38 11*s.* last year.

Digitized by Google

THE PATHOLOGICAL SOCIETY OF LONDON,

Cr. *In Account with the Treasurer*, WILLIAM CAYLEY, ESQ., M.D., *41st Session*, 1887–88. **Dr.**

	£	s.	d.	£	s.	d.
By *Balance* at Bank, January 1st, 1888	40	1	0			
Less Cheque not presented	1	10	0			
				38	11	0
Subscriptions:						
414 Annual (Current)	434	14	0			
22 Ditto (in Advance)	23	2	0			
9 Ditto (in Arrear)	9	9	0			
25 Resident Admissions	26	5	0			
10 Non-Resident Admissions	21	0	0			
1 Life Composition	15	15	0			
				530	5	0
Sale of Transactions:						
At 53, Berners Street	28	11	0			
By Smith, Elder, & Co.	67	19	6			
				96	10	6
Dividends on "Goschens" (including bonus of £2 18s. 4d. and an extra quarter under new arrangement)				45	9	11
				£710	16	5

	£	s.	d.	£	s.	d.
To *Meetings:*						
Contributions towards Expenses of Rooms, &c.	78	15	0			
Ditto for Extra Meeting	5	5	0			
Refreshments, &c.	39	4	0			
R. Coldrey (Meetings, &c.)	8	0	0			
Microscopes and Lamps	17	3	0			
Expenses of Committee on a Parasitic Fœtus	1	6	0			
				149	13	0
Transactions:						
Balance due for Delivery of Vol. XXXVIII.	3	14	3			
Printing, Binding, Delivering of Vol. XXXIX	201	0	0			
Illustrations (Newman)	42	8	10			
(Burgess)	18	12	0			
(Mr. Sutton)	19	17	0			
(Balcomb)	7	7	6			
(Gilmour)	5	17	0			
(Typo Etching Company)	1	12	6			
(Mintern)	36	18	6			
(Huth)	14	13	9			
(Dangerfield)	20	0	0			
(Danielsson)	44	2	6			
				416	3	10
Secretariat and Treasury:						
Assistance to Hon. Secs.	28	7	0			
Petty Cash at 53, Berners Street	14	17	5			
Ditto (Medical Secretary's)	1	2	6			
Commission on Collecting Subscriptions	20	4	0			
Posting Ledgers (Mr. MacDermott)	2	2	0			
				66	12	11
Stationery and Printing (Sundry):						
Adlard	12	2	1			
Wodderspoon	4	1	0			
Evans and Hallewell	0	5	6			
Beck	0	19	0			
				17	7	7
				649	17	4
Balance in Treasurer's hands				60	19	1
				£710	16	5

January 15th, 1889.

W. CAYLEY, M.D., *Treasurer.*

Audited and found correct, WILLIAM ANDERSON, ISAMBARD OWEN, MD., } *Auditors.*

R. J. GODLEE, *Hon. Secretary.*

Digitized by Google

Digitized by Google

LIST OF SPECIMENS AND REPORTS

BROUGHT BEFORE THE SOCIETY DURING THE SESSION 1888-89.

PAGE

ADDRESS by the PRESIDENT, W. HOWSHIP DICKINSON, M.D. 1

I. DISEASES, ETC., OF THE NERVOUS SYSTEM.

1. Unusual case of meningeal tuberculosis By HARRINGTON SAINSBURY, M.D. 9
2. A case of chronic syphilitic meningitis, arteritis, and cerebral atrophy and sclerosis in a boy aged four, with some notes on the histology of these lesions and of the "granular shagreen" appearance of the ependyma observed in some cases of hydrocephalus [With Plate II] By ANGEL MONEY, M.D. 13
3. A case of hydatid cyst on the left cerebral hemisphere By HERMANN WEBER, M.D. 17
4. Symmetrical sarcoma of both cerebral hemispheres By J. A. ORMEROD, M.D. 19
5. Multiple tubercular tumours in the brain of a child aged 1 year (Card specimen) By NORMAN DALTON, M.D. 20
6. Hæmorrhage into pons Varolii (Card specimen) By J. A. ORMEROD, M.D. 21
7. Hæmorrhage into the pons of a child aged 6 (Card specimen) By WILLIAM COLLIER, M.D. 21
8. Infantile paralysis (Card specimen) By R. G. HEBB, M.D. 22
9. Pseudo-hypertrophic paralysis; affection of the heart and diaphragm; area of softening in the cord; degeneration and atrophy of the nerve-trunks [With Plate I] By H. HANDFORD, M.D. 24

Digitized by Google

II. DISEASES, ETC., OF THE ORGANS OF RESPIRATION.

PAGE

1. Congenital growths in the larynx By Lennox Browne 34
2. Fracture of thyroid and cricoid cartilages (Card specimen) By H. Montague Murray, M.D. 36
3. Diphtheritic membrane expelled from a tracheal wound (Card specimen) By William Henry Battle, for Dr. F. E. Nichol 37
4. Caseous bronchial gland perforating and obstructing the trachea By G. Gulliver, M.B. 38
5. Complete rupture of bronchi By A. Marmaduke Sheild, M.B. 39
6. Syphilitic ulceration of trachea and larger bronchi By G. Gulliver, M.B. 40
7. Primary carcinoma of the left bronchus By H. Handford, M.D. 41
8. Embolism of pulmonary artery (Card specimen) By Raymond Johnson, M.B., B.S., for M. Berkeley Hill, M.B. 45
9. Lymphosarcoma of left lung (Card specimen) By Arthur Davies, M.B. 46
10. Lymphosarcoma of the mediastinum involving the large blood-vessels (Card specimen) By Robert Maguire, M.D. 47
11. Two cases of mediastinal growth involving the pericardium and heart By Frederick W. Mott, M.D. 47
12. Mediastinal sarcoma in an infant aged 15 months By Angel Money, M.D. 54

III. DISEASES, ETC., OF THE ORGANS OF CIRCULATION.

1. Fatty heart, from a case of chronic alcoholism (Card specimen) By Frederick Walter Mott, M.D. 57
2. Unusual form of rupture of the heart (Card specimen) By W. H. White, M.D. 58

Digitized by Google

PAGE

3. Mitral stenosis. Enlarged auricle compressing left bronchus By H. H. Taylor, M.D. 5
4. Stenosis of mitral and tricuspid valves (Card specimen) By R. G. Hebb, M.D. 60
5. Atheromatous disease of aorta and arteries of lower limbs (Card specimen) By Raymond Johnson, for Mr. Heath 61
6. Aortic aneurysm which burst into the œsophagus (Card specimen) By Frank Penrose, M.D. 62
7. Case of aneurysm at the junction of the transverse and descending portion of the arch of the aorta which ruptured into the pericardium. Death in fifty-six hours By S. Herbert Habershon, M.D. 62
8. Aneurysm of the thoracic aorta bursting into the œsophagus just above the diaphragm, causing fatal hæmatemesis (Card specimen) By John R. Lucas 66
9. Arterio-venous aneurysm of splenic vessels, with thrombosis of mesenteric veins and localised acute colitis By James F. Goodhart, M.D. 67
10. Aneurysm of the right brachial and ulnar arteries, resulting from embolism By Frederick Walker Mott, M.D. 71
11. Thrombosis of aorta [With Plate III] By G. Newton Pitt, M.D. 74
12. Thrombosis of veins of neck (Card specimen) By J. A. Ormerod, M.D. 75

IV. DISEASES, ETC., OF THE ORGANS OF DIGESTION.

1. Simple ulcers of œsophagus (Card specimen) By H. W. G. Mackenzie, M.B. 76
2. Sarcoma of œsophagus (Card specimen) By J. H. Targett, M.B., M.S. 76
3. Fatty tumour in wall of stomach (Card specimen) By H. Montague Murray, M.D. 78

Digitized by Google

PAGE

4. Ulcer of the stomach close to the pylorus (Card specimen) By Frank Penrose, M.D. 78
5. A case of cancer of the stomach, ? originating in a chronic ulcer By James F. Goodhart, M.D. 78
6. Lymphadenoma of the stomach and intestines [With Plates IV and V] By G. Newton Pitt, M.D. 80
7. Diffuse sarcoma of the stomach (Card specimen) By H. Handford, M.D. 89
8. Ulcers of intestine and stomach from a case of chronic Bright's disease (Card specimen) By R. G. Hebb, M.D. 92
9. Two cases of obstruction of small intestine by a ring formed by adhesion between contiguous appendices epiploicæ By E. C. Perry, M.B. 93
10. On congenital abnormalities of the lower ileum [With Plate VI] By Leopold Hudson 98
11. A case of columnar epithelioma of the ileo-cæcal valve, complicated by a post-cæcal abscess, and with secondary growths in the mesocolic glands, liver, and lungs By Angel Money, M.D. 103
12. Two anomalous vermiform appendices (Card specimen) By Frederick Walker Mott, M.D. 105
13. Perforated cæcum from a case of volvulus of sigmoid flexure. Vermiform appendix measuring seven inches (Card specimen) By Frederick Walker Mott, M.D. 106
14. Ulceration of the cæcum followed by almost complete occlusion of the ileo-cæcal valve (Card specimen) By Frederick Walker Mott, M.D. 106
15. Ulceration of the cæcum, followed by almost complete occlusion of the cæcal valve (Card specimen) By Frederick Walker Mott, M.D. 107
16. Ulcerative colitis with extensive perforation [With Plate VII] By J. A. Ormerod, M.D. 109
17. Two cases of cancer of the large intestine By Raymond Johnson, M.B., B.S. 110

Digitized by Google

PAGE

18. Parts after Allingham's inguinal colotomy (Card specimen) By G. R. Turner 114
19. Retro-cæcal hernia of the appendix cæci (Card specimen) By L. A. Dunn, M.B., B.S. 114
20. Some hernial sacs and their contents By C. B. Lockwood 115
21. Lumbar hernia By J. Hutchinson, jun. 117
22. Ectopion of the cæcum with other malformations, and prolapse of intestine through the ileo-cæcal valve By William Henry Battle 120
23. Diffuse calcification of the liver By J. H. Targett, M.S. 123
24. Free iron in the liver in pernicious anæmia (Card specimen) [With Plate VIII, fig. 2] By Frederick Walker Mott, M.D. 127
25. Hepatitis in enteric fever (Card specimen) [With Plate VIII, fig. 1] By H. Handford, M.D. 129
26. Syphilitic liver, in which the left lobe is much larger than the right (Card specimen) By Frank Penrose, M.D. 133
27. Internal rupture of liver (Card specimen) By J. H. Targett, M.B., M.S. 133
28. A case of cirrhosis of the liver, probably originating in phlebitis of the portal vein. By James F. Goodhart, M.D. 134
29. Cirrhosis of liver in a child (Card specimen) By. J. H. Targett, M.B., M.S. 136
30. Pericellular cirrhosis of liver? (Card specimen) By J. A. Ormerod, M.D. 137
31. Primary carcinoma of liver (Card specimen) By Leopold Hudson 137
32. Melanotic sarcoma of liver By Norman Moore, M.D. 138
33. Tubercular excavation of liver (Card specimen) By F. Wetherred, M.D. 139
34. Carcinomata of cystic gall-bladder and bile-duct (Card specimen) By J. Griffiths, M.B. 140
35. A case of primary cancer of the pancreas causing biliary obstruction By W. Henry Kesteven 140

Digitized by Google

V. DISEASES, ETC., OF THE GENITO-URINARY ORGANS.

PAGE

1. Kidney from a case in which albuminuria was hereditary [With Plates IX, X and XI]
By W. H. Dickinson, M.D. 144
2. Two cases of unilateral nephritis with atrophy of the kidney induced by pressure, (1) on the ureter, and (2) on the renal blood-vessels
By George F. Crooke, M.D. 153
3. Cystic dilatation in a cirrhotic granular kidney (Card specimen) By Samuel G. Shattock 159
4. Cystic degeneration of kidneys, with two ureters on right side (Card specimen) By A. M. Jackson, M.B. 160
5. Absence of upper two thirds of left ureter, with very small cystic kidney. Surgical right kidney after gonorrhœa (Card specimen)
By Frank Penrose, M.D. 161
6. The histological changes in the kidney in hydronephosis
By Joseph Griffiths, M.B. 161
7. Calculus in ureter; disorganisation of kidney (Card specimen) By F. D. Drewitt, M.D. 172
8. Malposition of left kidney (Card specimen)
By A. Primrose, M.B. 172
9. Stricture of urethra, death caused by a false passage made by the patient (Card specimen)
By Frank Penrose, M.B. 174
10. Case of vesiculation of the mucous membrane of the bladder [With Plate XII]
By Quarry Silcock, M.D. 175
11. Epithelioma of the male urethra
By Joseph Griffiths, M.B. 177
12. Encysted prostatic calculi By W. Bruce Clarke, M.B 179
13. Cancer of prostate (Card specimen)
By Berkeley Hill, M.B. 181
14. Cystine calculus By Anthony Bowlby 182
15. Abscess of epididymis (Card specimen)
By A. Marmaduke Sheild, M.B., B.S. 182

Digitized by Google

PAGE

16. Chylous fluid removed from tunica vaginalis (Card specimen) By Sydney Jones, M.B. 183
17. Extra-vaginal hæmatocele of scrotum (Card specimen) By F. S. Eve 183
18. Varicocele, a spontaneous variation in the spermatic veins [With Plates XIII and XIV] By W. G. Spencer, M.S. 185
19. Paget's disease, affecting the scrotum and penis [With Plates XV and XVI] By H. Radcliffe Crocker, M.D. 187
20. Large fatty tumour in the scrotum surrounding the testis, but not adherent to it By Jonathan Hutchinson, F.R.S. 191
21. Sarcoma of the testicle, following on removal of the other for hypertrophy of a doubtful nature, which the microscope had declared not sarcomatous By Jonathan Hutchinson, F.R.S. 193
22. Extra-uterine fœtation; rupture of cyst; abdominal section; peritonitis; death (Card specimen) By Frederick Walker Mott, M.D. 197
23. Blood concretions in the ovaries By H. W. G. Mackenzie, M.D. 198
24. Large ovarian tumours in a seven months' child [With Plate XVII] By Alban Doran 200
25. Columnar-celled carcinoma of the ovary (Card specimen) By Samuel G. Shattock 208
26. Specimen of tubercular disease of ovary By Walter Edmunds, M.D. 210
27. Tubercle of the ovaries By W. S. A. Griffith, M.D. 212
28. Tubercle of the ovary Additional notes By W. S. A. Griffith, M.D. 219
29. Sequel to the case of primary cancer of the Fallopian tube reported in the thirty-ninth volume of the Society's 'Transactions' [With Plate XIII] By Alban Doran 221

Digitized by Google

VI. DISEASES AND INJURIES OF THE OSSEOUS SYSTEM.

PAGE

1. An account of the skeleton of the Norwich dwarf [With Plates XVIII and XIX] By JONATHAN HUTCHINSON, F.R.S. 229
2. Notes on a case of dislocation of shoulder without rupture of capsule By D'ARCY POWER, M.B. 235
3. The late Dr. Carnochan's specimen of the so-called congenital dislocation of both hip-joints; sent from New York [With Plates XX and XXI] Exhibited by WILLIAM ADAMS 237
4. A case of tubercular teno-synovitis By C. H. GOLDING-BIRD, M.B. 244
5. Cases of talipes By D'ARCY POWER, M.B. 247
6. Cast of a child's feet, taken shortly after birth, in a position of talipes varus and valgus (Card specimen) By W. G. SPENCER, M.B. 251
7. Disease of shoulder (Charcot's joint) (Card specimen) By JOHN R. LUNN 251
8. Osteo-porosis of the calvarium, shown in the fragments of a skull found on the Island of Lamoo, Zanzibar, June 8th, 1888 By JOHN FREDERICK BRISCOE 252
9. The structure of the eburnated substance in two specimens of advanced osteo-arthritis By SAMUEL G. SHATTOCK 254
10. Pedunculated chondroma removed from the knee-joint (Card specimen) [With Plates XXII and XXIII] Exhibited by SAMUEL G. SHATTOCK 256
11. Osteoma of the metacarpal bone By J. HUTCHINSON, jun. 263
12. Synostosis of upper cervical vertebræ (Card specimen) By L. A. DUNN 264
13. Epiphysitis of the upper extremity of the humerus (Card specimen) By L. A. DUNN 265
14. Syphilitic disease of the knee-joint and kidneys [With Plate XXIV] By JONATHAN HUTCHINSON jun. 266

Digitized by Google

PAGE

15. Syphilitic osteitis of tibiæ (Card specimen) By G. N. Pitt, M.D. 270
16. Defective development of right fibula (Card specimen) By L. A. Dunn 272
17. Spina bifida (Card specimen) By J. Bland Sutton 273

VII. MORBID GROWTHS AND TUMOURS.

1. The "crateriform ulcer of the face," a form of acute epithelial cancer [With Plate XXV] By Jonathan Hutchinson, F.R.S. 275
2. Congenital cyst of the tongue (Card specimen) By H. A. Lediard, M.D. 281
3. Pedunculated chondroma from knee-joint (Card specimen) By S. G. Shattock 282
4. Myxo-lipoma of the spermatic cord (Card specimen) By J. H. Targett, M.S. 282
5. Epithelioma of floor of mouth, tongue, and lower jaw (Card specimen) By Raymond Johnson, M.B., B.S. for Mr. Heath 283
6. "Tumour" of skin (cylindroma carcinomatodes) (Card specimen) By R. G. Hebb, M.D. 284
7. Duct cancer of breast (Card specimen) By H. Betham Robinson, M.B. 285
8. Tumour removed from Scarpa's triangle By Sydney Jones 286
9. Hæmorrhagic sarcoma (Card specimen) By J. A. Ormerod, M.D. 290
10. Myxo-sarcoma. Six recurrences in twenty-three years (Card specimen) By H. Handford, M.D. 291
11. A complete case of ossifying sarcoma [With Plate II, fig. 1] By D'Arcy Power, M.B. 293
12. Retro-peritoneal sarcoma (Card specimen) By Raymond Johnson, M.B., B.S., for Mr. Heath 295
13. Lympho-sarcoma of kidney (Card specimen) By R. G. Hebb, M.D. 296

Digitized by Google

PAGE

14. Sarcoma of forearm growing into a large vein at the bend of elbow (Card specimen)
By Frederic S. Eve and J. H. Targett, M.B., M.S. 297
15. Granuloma tumour of skin ? lupus (Card specimen)
By R. G. Hebb, M.D. 298

VIII. DISEASES, ETC., OF THE DUCTLESS GLANDS.

1. Congenital goitre (Card specimen)
By H. A. Lediard, M.D. 299
2. Disease of suprarenals; ? nature (Card specimen)
By H. H. Taylor 299
3. Lympho-sarcoma of right suprarenal body; the right kidney (Card specimen)
By Arthur Davies, M.B. 300
4. Symmetrical tubercular disease of the suprarenal capsules in which tubercle bacilli were found, from a case of Addison's disease (Card specimen)
By D'Arcy Power, M.B., for Dr. Vincent Harris 300

IX. DISEASES, ETC., OF THE SKIN.

1. Pemphigus malignus By G. Newton Pitt, M.D. 303
2. A case of leprosy (Card specimen)
By J. W. Washbourn, M.D. 307

X. SPECIAL COMMUNICATIONS

Discussion on the Morbid Anatomy and Pathology of Chronic Alcoholism.—Introductory Address
By Joseph Frank Payne, M.D. 310

Digitized by Google

XI. MISCELLANEOUS SPECIMENS.

PAGE

1. Fœtal cretinism (Card specimen)
By J. H. Targett, M.S. 385
2. Dermoid cyst of lumbo-sacral region [With Plate XXVI] By Leonard Wilde, M.B. 386
3. Dermoid cyst near knee (Card specimen)
By J. H. Targett, M.B., M.S. 388
4. Cysticercus cellulosæ from human muscle
By H. Betham Robinson, M.B. 388
5. Perforating ulcer of foot
By A. Marmaduke Sheild 390
6. Tubercular abscess of the breast
By Samuel G. Shattock 391
7. Microscopic specimens of tuberculosis (Card specimen)
By F. J. Wethered, M.D. 399
8. The formation of mucous cysts in the mouth
By W. G. Spencer, M.B. 400
9. Nasal calculus (Card specimen)
By Sydney Jones, M.B. 401
10. Phosphatic concretion from a recto-vaginal fistula (Card specimen) By A. H. Robinson, M.D. 402
11. Cast of the right leg from a case of alcoholic neuritis (Card specimen) By D'Arcy Power, M.B. 403
12. Localised symmetrical œdema (Card specimen)
By Stephen Mackenzie, M.D. 403
13. Actinomycosis of the lower jaw of a heifer (Card specimen) By Samuel G. Shattock 404
14. Case of actinomycosis of the liver (Card specimen)
By Frederic S. Eve 405
15. A case of actinomycosis hominis [With Plates XXVII, XXVIII, and XXIX]
By Sheridan Delépine, M.B. 408
16. Psorospermial cysts of both ureters [With Plate XII]
By Frederic S. Eve 444
17. Further specimens illustrating the neoplastic process in trees [With Plate XXX]
By W. Roger Williams 446

Digitized by Google

XII. DISEASES, ETC., OF THE LOWER ANIMALS.

PAGE

1. A disease of the bones of goats, having points of resemblance to mollities ossium, osteitis deformans, and multiple sarcoma of bone [With Plate XXXI] By W. G. Spencer, M.B. 449
2. Multiple symmetrical tumours of bone from a dog [With Plate XXXII] By W. G. Spencer, M.B. 457
3. Camel with tuberculosis (Card specimen) By Walter K. Sibley, M.B. 460
4. Supernumerary limbs in frogs and toads (Card specimen) By J. Bland Sutton 461
5. A cyst of undescended testis of an imperfectly developed male sheep [With Plate XXXIII] By Frederic S. Eve 463

Digitized by Google

REPORTS OF THE COMMITTEE ON MORBID GROWTHS.

PAGE

1. On Dr. Handford's specimen of carcinoma of bronchus (F. Taylor and F. C. Turner) . . . 44
2. On Mr. Targett's case of calcification of liver (S. J. Sharkey and F. S. Eve) 125
3. On Mr. Hutchinson's case of disease of testicle (R. W. Parker and S. G. Shattock) . . . 196
4. On Mr. Briscoe's specimen of osteo-porosis (F. Barlow, F. S. Eve, S. G. Shattock, and J. B. Sutton) . 254
5. On Mr. Hutchinson's specimen of crateriform ulcer (Norman Moore and H. H. Clutton) . . 281
6. On Mr. Spencer's specimen of disease of bone in a dog (R. W. Parker and S. G. Shattock) . . 459
7. On Mr. Sydney Jones's specimen of tumour of Scarpa's triangle (C. J. Symonds and A. A. Bowlby) . 289

Digitized by Google

Digitized by Google

LIST OF PLATES.

		TO FACE PAGE
I.	Pseudo-hypertrophic Paralysis. (Dr. HANDFORD.) (Page 24)	27
II.	Fig. 1. Ossifying Sarcoma. (Mr. D'ARCY POWER.) (Page 293) Fig. 2. Syphilitic Meningitis. (Dr. ANGEL MONEY.) (Page 13)	15
III.	Thrombosis of Aorta. (Dr. PITT.) (Page 74)	74
IV.	Lymphadenoma of Stomach. (Dr. PITT.) (Page 80)	82
V.	Lymphadenoma of Intestines. (Dr. PITT.) (Page 80)	82
VI.	Abnormalities of Ileum. (Mr. HUDSON.) (Page 98)	99
VII.	Ulcerative Colitis. (Dr. ORMEROD.) (Page 109)	109
VIII.	Fig. 1. Liver in Enteric Fever. (Dr. HANDFORD.) (Page 129) Fig. 2. Liver in Pernicious Anæmia. (Dr. MOTT.) (Page 127)	127
IX. X. XI.	To illustrate Dr. Dickinson's paper on Hereditary Albuminuria. (Page 144)	148
XII.	Fig. 1. Vesiculation of Mucous Membrane of Bladder. (Mr. SILCOCK.) (Page 175) Fig. 2. Psorospermial Cyst of Ureter. (Mr. EVE.) (Page 444)	176
XIII.	Fig. A. Primary Cancer of Fallopian Tube. (Mr. DORAN.) (Page 221) Fig. 2. Varicocele. (Mr. SPENCER.) (Page 185)	185
XIV.	Varicocele. (Mr. SPENCER.) (Page 185)	185
XV. XVI.	Paget's Disease of Scrotum. (Dr. CROCKER.) (Page 187)	188
XVII.	Ovarian Tumour in Infant. (Mr. DORAN.) (Page 200)	200

Digitized by Google

		TO FACE PAGE
XVIII. XIX.	Skeleton of Norwich Dwarf. (Mr. HUTCHINSON.) (Page 229)	230
XX. XXI.	Congenital Dislocation of both Hip-joints. (Mr. WILLIAM ADAMS.) (Page 237) . .	238
XXII. XXIII.	Pedunculated Chondroma. (Mr. SHATTOCK.) (Page 256)	257
XXIV.	Syphilitic Disease of Knee. (Mr. HUTCHINSON, jun.) (Page 266) . . .	267
XXV.	Crateriform Ulcer of Face. (Mr. HUTCHINSON.) (Page 275)	276
XXVI.	Dermoid Cyst. (Mr. LEONARD WILDE.) (Page 386)	387
XXVII. XXVIII. XXIX.	Actinomycosis. (Dr. DELÉPINE.) (Page 408)	420 429 431
XXX.	Fig. 1. Dermoid Cyst. (Mr. TARGETT.) (Page 388) Fig. 2. Neoplastic Process in Trees. (Mr. ROGER WILLIAMS.) (Page 446)	388
XXXI.	Disease of Bones in Goats. (Mr. SPENCER.) (Page 449)	450
XXXII.	Symmetrical Tumours of Bone in Dogs. (Mr. SPENCER.) (Page 457) . . .	457
XXXIII.	Cyst of Retained Testicle in Sheep. (Mr. EVE.) (Page 463)	464

Digitized by Google

WOODCUTS.

		PAGE
1.	Primary carcinoma of bronchus (Dr. Handford)	41
2.	Lumbar hernia (Mr. Hutchinson, jun.)	118
3.	Osteoma of metacarpal (Mr. Hutchinson, jun.)	263
4.	Spina bifida (Mr. Sutton)	273
5.	Cirrhosis of liver from 'Philos. Trans.' of 1685 (Dr. Payne)	314
6.	Formation of mucous cysts in the mouth (Mr. Spencer)	400
7.	Actinomycosis from human liver (Mr. Eve)	407
8.	„ from tongue of ox (Mr. Eve)	407
9.	Sections through symmetrical tumours of bone in a dog (Mr. Spencer)	458
10.	Supernumary limbs in frogs and toads (Mr. Sutton)	461
11.		462
12.		463

Digitized by Google

Digitized by Google

ADDRESS

BY THE PRESIDENT, W. HOWSHIP DICKINSON, M.D.,

DELIVERED AT THE FIRST
MEETING AFTER THE ANNUAL GENERAL MEETING, JANUARY 29TH, 1889.

GENTLEMEN,—I assume with great diffidence the honour which you have conferred upon me, a feeling which grows when I consider the great names of many who have occupied this chair before. Not to speak of those who in later days have received this distinction, the names of Williams, Latham, Cæsar Hawkins, Watson, Fergusson, Prescott Hewett, Simon, and Jenner, will be present to all who are familiar with the early history of the Society. Nor can I but derive something which approaches discouragement when I think of the eminent qualifications, upon which it would not become me to dwell, of the great pathologist and great surgeon who has been my immediate predecessor.

I liken myself in my own mind to the figure-head of a great ship, a wooden structure which contributes nothing to its progress though it occupies the foremost place; but to no other part of the vessel, or the venture, can any dispraise attach, for the cargo is select and the motor power all that modern science can make it.

The importance of this Society might well impress a sense of responsibility upon anyone, be he whom he may, who is placed in the position of its President, for I look upon it as representing and comprising within itself what most of all makes medicine a science. For in the scientific treatment of disease it is surely of the first importance to know what it is. Medicine is partly a science, partly an empirical art; so far as it is a science it is pathology that makes it so. But for this we should have nothing but the treating of symptoms, a mode of practice too often based on fanciful ignorance if not upon conscious imposture. Pathology, in teaching the intimate nature of disease, is useful in more ways

Digitized by Google

than one; the nature of the disease may suggest its treatment, whether it be extraction of a stone or tumour which but for pathology we could not assign to its position, the pulling out of an intussusception which but for pathology we could not understand, or the relief of an empyema which our pathological observations have enabled us to diagnose. On the other hand the nature of the disease may suggest that it is not to be treated, that it is outside the range of medical influence, and that the patient may be spared disappointment, the vain spending of his living on physicians, and treatment which is useless and possibly tormenting.

Pathology is of great antiquity, but is apparently far from being exhausted. The science of the nineteenth century has touched it with new vitality; and with the help of the microscope and chemistry it is now developing and bearing fruit in a manner which has no parallel in any former period of its long history.

The ancients were acquainted with some of the larger facts of pathology and turned them to practical use. They learned at a very remote date to connect pus in the pleura with its external signs, but on the whole their observations were superficial, more upon the living than the dead. I cannot find that before the seventeenth century there was any knowledge of conditions to us so obvious as cerebral hæmorrhage and hepatization of the lung, though the symptoms in connection with them were matters of ancient experience. So great indeed have been the acquirements of modern times that we of this day can scarcely imagine the state of medicine even at a date so recent as to be within the life, and possibly within the memory, of some who are still with us. Bright published his observations on the kidney in 1827. How confused must have been the ideas of dropsy and coma before that time, and how much of enlightenment was due to his observations in morbid anatomy and his association of them with certain obvious symptoms.

This Society was founded in 1846. Let me briefly glance at the advances which its chosen science has made since that date. In 1847 Virchow made known some of the processes of embolism which were more fully worked out by the late Dr. Kirkes, and the results published in 1852. There appear to have been isolated observations of the same kind before these. I owe to Dr. Payne[1] the knowledge that in 1684 one William Gould, an Oxford doctor, recorded the fact that clots, "particles of a polypus" he calls them,

[1] 'Philosophical Transactions,' xiv, 1684.

Digitized by Google

were carried from the left ventricle to the carotid artery and there impacted stopping the intercourse of spirits in the brain. But our present knowledge is due to Virchow and Kirkes. The light they have been the means of directing upon many disorders, particularly of the brain, is such that we can scarcely realize the confusion and obscurity in which they must have been involved before these simple pathological observations provided the clue so much needed. Among great pathological discoveries this in importance as in date follows next upon that of Bright.

Close upon this comes the lardaceous or amyloid disease, which had been slowly emerging from primordial darkness since in 1842 it was noticed by Rokitansky as a simultaneous infiltration of several organs by an albuminous blastema, which imparted the aspect of lard or bacon and accompanied cachectic states. In 1853 Virchow discovered the so-called amyloid reaction, and constructed the amyloid theory. With the ready means of detection thus provided, and the interest of a novel theory, the disorder became the subject of attention and of further elucidation, as the annals of this Society sufficiently show; and as the direct result of pathological inquiries assumed a position in clinical medicine to which great importance must be attached, whether we have regard to the number and consequence of the organs it embarrasses, or at the practical benefits which often ensue from its recognition.

Next in time comes the discovery of Addison, who in 1855 did for the suprarenal bodies what his colleague had done for the kidneys, and astonished the world by showing that these hitherto disregarded organs were subject to morbid changes which were connected with symptoms as striking as any that Bright had associated with renal disease.

Of more frequent application, and therefore of more practical importance, is the discovery of the nature of suppuration, which was not completely accomplished until 1867. The migration of leucocytes had indeed been noticed by William Addison at an earlier date, but it is owing to the later and apparently independent observations of Cohnheim that the process became an accepted part of medical science—a part which seems to us now so essential that we can but wonder that until so recent a date pathologists and surgeons were generally content to believe, what now appears impossible, that this flux, often so profuse, was the product of the tissue, not of the blood. It is interesting to recall a forecast made

Digitized by Google

seventy-four years before Cohnheim's observations, which comes as near to the true theory of suppuration as was possible without microscopic research. "Pus," said John Hunter, "is formed from some change, decomposition, or separation of the blood which that undergoes in its passage out of the vessels."

I may next touch upon the nervous system. When this Society was founded the minute pathology of this paramount portion of the human frame was almost absolutely unknown. An important structural disease of the cord was described as essential paralysis, I suppose because paralysis was thought to be its essential and solitary character, and to which no organic change was annexed, nor had any of the disorders now known to depend on mischief in the anterior horns been then traced to their organic origin. Locomotor ataxy was then beginning to be recognised by its symptoms, but scarcely yet by its lesions. The symptoms of pseudo-hypertrophic paralysis, and of the various forms of sclerosis and of neuritis, had not yet been separated from those of other disorders, and no human eye had discerned their attendant morbid anatomy, the condition which with regard to sclerosis and neuritis comprises their definition and distinction. At the time of our foundation no one could make sections of the brain or cord which displayed any but the coarsest alterations; the art of making translucent sections is quite a recent one; we owe it chiefly to Lockhart Clarke, whose methods initiated a new epoch in the pathology of the nervous system. By such means some diseases, as has been seen, have been traced to definite pathological origins, while others have been associated with lesions not hitherto known to belong to them, though it is probable that these lesions are not the ultimate result of inquiries which must be still regarded as incomplete. But they are not without use, for they show the track and mode of morbid actions which have not yet been traced to their source. Among the diseases of the pathology of which we have learned something, though not everything, may be mentioned, tetanus, hydrophobia, chorea, the various forms of insanity, and I trust I may not be thought egotistic or obstinate if I add diabetes to the number. Some of these diseases, hydrophobia certainly, and tetanus probably, have beginnings in the humours, whether they be called infectious or zymotic; but none the less must they be material, proper for pathological research and capable of pathological identification.

Digitized by Google

Here we enter upon a wide field, one as vast as has ever been presented to biological inquiry. Addison (not the physician) imagines a being endowed with miraculous vision, as taking "a greater pleasure in considering the works of creation in their immensity than in their minuteness," and as choosing rather to resolve the milky way into its components than to witness the dissection of a mite or of "one of those little animals which we find in the blue of a plum." But to us the smaller may be more important than the greater. Little things are great to little men. A group of bacteria under a microscope may fill as large a space upon the retina as the constellation of Orion, while the species they belong to may exert an influence upon the fortunes of humanity as great as the fictions of astrologers ever attributed to the stars.

The possibility that minute animal or vegetable organisms might be the essential causes of contagious diseases is a hypothesis which has long been present in the minds of physicians and naturalists. Sir Henry Holland fifty years ago speculated upon insect life as a cause of disease. He tells us that the exanthemata and other contagious disorders had been, in the imagination of an earlier theorist, attributed to different species of acari, and quotes Henlé, who had recently propounded the theory that "the material of all contagious disease was not merely organic, but matter possessing all the conditions of parasitic life." But it has been reserved for later times and our own contemporaries to place this theory upon a basis of observation. Vibriones have long been known as connected with decomposition, but any definite association of bacteria with disease is younger than this Society. The bacillus of anthrax was made known in 1855, that of relapsing fever in 1873, that of tubercle in 1882. I need not mention others; their name is legion; they threaten to become almost as numerous as diseases. The detection and definition of as yet unknown kinds, and their association each with its ailment, or, if not so, with the condition, whatever it be in which it presents itself, is work for the future; to which must be added further questions, Is the bacillus the cause of the disease, or is it only associated with the cause? Is it essential or accidental, or sometimes one and sometimes the other? What chemical changes are associated with the life of the bacillus? What are its relations to the blood and tissues? These questions and many others suggest themselves; the field of view widens, but as yet we

Digitized by Google

can see no limit to it. Practical results have already been gained, among others the system of antiseptic surgery.

What with section-making and germ-hunting, we have pushed our knowledge of disease in many directions; we have provided morbid anatomy for disorders hitherto thought to have none, and we have learned a little, with promise of more, of the intimate nature of certain complaints belonging to the large class of fevers, heretofore known only as groups of symptoms, though the imaginative may have connected them with changes in the blood and the process of fermentation. But it looks now as if a poetical simile were about to become prosaic fact, and each disease be traced to its organism, as the production of alcohol is to the yeast plant. Whether scarlet fever and measles will prove to be botanical or zoological, whether Kew Gardens or those of the Zoological Society are to present the organic essences of these diseases to the students of the future, the future must determine.

But while we pry into the doings of the organisms by which we are infested, let us not forget that there are such things as chemical diseases, by which I mean such as depend in the first place neither on organisms nor organs; not so much on the machine as on the material which is put into it or taken out of it. More or less oxygen, nitrogen, or carbon, more or less acid or alkali, the due balance of potash and soda—all these questions land us in pathology, and that of the most important kind. Be it remembered that we are a *pathological* society, not one of mere morbid anatomy. Among chemical diseases, or what we suppose to be such, I need instance only rheumatism, gout, and scurvy. About these we have learned something, and seem to be on the verge of learning more; but the part that is wanting is generally the final one, which should give coherence and use to all the rest. Nature treats us like the illogical lady who granted the major and the minor but denied the conclusion. For example, take scurvy. Few things seem better ascertained than that foods are antiscorbutic in proportion to the potash they contain; thus scurvy should depend on a want of potash and be prevented or cured by this alkali. But as yet we have not been able to make the sum prove. Potash will not cure scurvy, though pot-herbs will. We seem to be close to something which we have not grasped; could we go but one step further and find the precise pathological deficiency which constitutes the disease we might find ourselves in possession of a chemical antidote.

Digitized by Google

Let what we have done encourage us to attempt more. Let us think twice before we admit that any disease is *functional*, unconnected, that is, with material change. Let it be the function of this Society to unmask functional disease. An alteration in the action of an organ may depend upon a change in the organ itself, in the material supplied to it, or in the nerves which regulate it; but there must be a change somewhere. Changes in the organ or its supply are obviously within the scope of research, pathological or chemical. Alterations in innervation are less obviously so, but not necessarily and for ever outside it. If we can find nothing amiss in the nerve we must look at the nerve-centre, and, failing this, at the agencies, be they what they may, by which that centre is influenced. Here we may be clinically successful, but perhaps may as yet find nothing within the range of morbid anatomy. If these agencies, many of which belong to the outside world, are only temporarily wrong, equally transient may be the result. In delirium, for example, fleeting and difficult to seize may be the conditions, whether in brain or blood, which pertain to it; but where the result is enduring or permanent we should be able to recognise something in the permanent structures to keep it up. A transient mental disturbance which we must call functional, because whatever change there is with it is not discernible, may leave disease which is persistent. A fright may cause chorea, insanity, or diabetes. But where the disease is thus lasting it must be kept up by something as lasting as itself, which cannot be elsewhere than in the organism. It is impossible that any such durable mischief will remain for ever out of sight. I myself refuse to consider any disease, be it short or long, as functional in the sense of being without material change; but I am willing to call so many disturbances which pass away with their cause and leave no wrack behind. But when diseases outlast their external cause, or come without one, and persist even unto death, then the word functional is but a disguise for ignorance of the grosser kind. Let us not say with the ostrich, Because I see nothing there is nothing to see. Let us admit the necessity for a fundamental lesion, even where we have not found one, and not be easily discouraged in our search for it. In many disorders, especially of the nervous system, which we have not yet got to the bottom of, we have found traces and tracks of morbid action which should lead to something further. Let us follow up such clues, and strive to replace imagination by ob-

Digitized by Google

servation, and fancied modes of going wrong without reason by knowledge of the changes on which the disturbance depends.

This is no barren inquiry; no seeking of knowledge only for the sake of knowledge. The practical issue may be distant, but it is none the less certain that an understanding of the nature of disease must in the end prove a guide in the treatment of it, whether it be in the direction of what to do or what not to do.

I would venture in conclusion to apply to my fellow members words which are not my own, and have neither novelty nor antiquity to give them interest, but were never more justly spoken than to this community:

> "Men, my brothers, men the workers, ever reaping something new,
> That which they have done but earnest of the things which they shall do."

Digitized by Google

REPORT.

SESSION 1888-1889

I. DISEASES, ETC., OF THE NERVOUS SYSTEM.

1. *Unusual case of meningeal tuberculosis.*

By HARRINGTON SAINSBURY, M.D.

JANE LAWRENCE, aged 48, was admitted into the Royal Free Hospital, under Dr. Cockle,[1] on October 15th, 1888. She complained of loss of power in the right leg and arm. The leg had been feeble for three weeks, the arm for three days before admission.

The family history does not bear on the case; it is therefore omitted.

The *present state* describes the patient as "an emaciated-looking woman, unable to walk without support, of very emotional disposition." The weakness complained of in the right arm was not very obvious on admission; it became more marked subsequently.

On testing the relative power of the legs it was noted that on attempting to walk the right leg performed jerky and extravagant movements, and that it was unable to support the patient's weight. When in bed it was found that the movements at ankle, knee, and hip were all present, and that the knee could be bent with some force when this movement was opposed. Decubitus was chiefly on the left side with general flexure of the joints. The superficial reflexes were equal in both legs and on the two sides of the abdomen and chest, the patellar reflex was much exaggerated on the right side, and on this side patellar clonus and also ankle-clonus were

[1] For the clinical notes I am indebted to Mr. Roalfe Cox, house physician to Dr. Cockle.

Digitized by Google

obtained. As to sensation, no complaint was made; it does not appear to have been tested, and indeed it is doubtful whether any reliable results could have been obtained.

On admission the patient's intellect was quite clear, but the emotional element was strongly marked. At night there was much restlessness and wandering, but no delirium.

The patient was troubled with cough and purulent expectoration. Over the lungs there were the physical signs of phthisis. There was nothing noteworthy in the other organs.

On October 20th (five days after admission) the patient complained of severe frontal headache; there was vomiting. She then lapsed into an apathetic state, accompanied by delirium at night, and the tongue became dry and fissured. At this stage the *superficial reflexes could not be obtained in the right leg, whilst the deep reflexes continued to be much exaggerated.*

On the 23rd of October the patient was quite delirious.

On the 25th she died comatose.

At no time were there any convulsions.

The temperature reached 100° on one occasion; with this exception it did not exceed 99°.

The clinical record is very incomplete, but during the first few days in hospital it was not possible to obtain very trustworthy results from examination of the patient's powers of movement and of perception, on account of the emotional state of the patient, and during the last days it was equally impossible to obtain satisfactory results owing to the gradual mental failure.

I would draw attention, however, to the weakness in leg and arm; to the abolition of the superficial reflexes in the right leg, which occurred a few days after admission; to the exaggeration of the deep reflexes in the right leg present throughout.

At the *post-mortem* examination the dura mater was found unusually adherent to the left hemisphere at one spot, just outside the longitudinal fissure, and a little posterior to its mid point; here the knife had to be used to separate the dura from the pia-arachnoid, which latter became slightly torn.

There was no evidence of tension within the brain (no flattening of the convolutions or dryness of the surface, no arching of the corpus callosum). The membranes at the base of the brain were healthy; there was no excess of fluid in the ventricles; the corpus callosum and fornix were rather soft.

Digitized by Google

The spot of adhesion of the dura mater to the pia-arachnoid above referred to proved to be just over the upper end of the fissure of Rolando. At the same level, on the mesial aspect of the hemisphere, minute tubercles were seen surrounded by pus; they were grouped around the upper termination of the fissure of Rolando. The cortex at this spot was slightly injected. Above the injection of the cortex was continued on to the outer surface of the hemisphere, and involved apparently both sides of the fissure of Rolando; certainly it involved the upper end of the ascending parietal and spread somewhat into the parietal lobule. It was not possible to speak so positively with regard to the upper end of the ascending frontal, since the pia-arachnoid had become slightly separated here. The miliary tubercles were most evident on the mesial surface of the brain.

Low down in the ascending frontal convolution and adjoining the fissure of Rolando, and two centimetres above the fissure of Sylvius (in the hardened state) there was found a small caseous focus, rather under the size of a lentil, and not quite circular in outline; it lay immediately beneath the pia-arachnoid. Around the mass there was little, if any, injection of the membranes.

The examination of the pons, medulla, and cerebellum, and of the right hemisphere was negative. The spinal cord was free from any disease.

The examination of the rest of the body was negative with the exception of the lungs. These were tuberculous with cavities in both apices. There were numerous miliary tubercles in the upper lobe of the right lung. The lower lobes of both lungs were in a condition of acute œdema.

The case appears to me to be worth recording, first as an example of cerebral localisation, the weakness in arm and leg, simulating a hemiplegia, being the result of two distinct lesions situated within the cortical areas which have been assigned to arm and leg. I would point out that the lesion in the ascending parietal lobe was towards the lower limit of the area usually described as including the arm centres.

Next the case illustrates the value of the two symptoms taken together, exaggeration of the deep reflexes, suppression of the superficial reflexes, as evidence of organic cerebral disease (see Gowers). It is in cases such as the present, in which the question

Digitized by Google

of hysteria has to be considered, that evidence of this kind is of the utmost value.

Lastly, from the point of view of morbid histology, the case is unusual. Tubercular meningitis as a basal affection is common; as an affection of the vertex it is more rare, but as a circumscribed affection of the vertex, so limited as to give rise to a monoplegia, it is much more rare. *February 19th*, 1889.

Appendix to case read at the Pathological Society on February 19th, 1889.—On slicing the left hemisphere, the surface lesions of which are described above, it was found that there was deeper infiltration of the brain substance just in front of the termination of the calloso-marginal fissure, at about the junction, therefore, of the ascending parietal convolution with the superior parietal lobule. The infiltration was of the caseous variety, though it was made up of a number of adjacent small foci; in depth the infiltration extended through the thickness of the grey matter, but did not involve the white matter. Further, at the hinder end of the fissure of Sylvius a few small caseous foci were found in the grey matter; the largest did not exceed a lentil in size; from before backwards the extent of the infiltration measured, perhaps, half a centimetre. Another small mass, the size of a lentil, was found just behind and above this in the angular lobule. All these masses in the neighbourhood of the termination of the fissure of Sylvius were confined to the grey matter.

The value of the case, therefore, will stand chiefly in regard to the localisation of the leg centre and the condition of the reflexes, superficial and deep.

Digitized by Google

2. *A case of chronic syphilitic meningitis, arteritis, and cerebral atrophy and sclerosis in a boy aged four, with some notes on the histology of these lesions and of the "granular shagreen" appearance of the ependyma observed in some cases of hydrocephalus.*

By Angel Money, M.D.

[With Plate II.]

Ernest G—, aged 4, was brought to me at the age of eleven months, suffering from water on the brain and syphilitic disseminated choroiditis. The head was large, its circumference measured twenty-two inches, and over the vault fifteen inches. The anterior fontanelle was tense and convex, its dimensions were two and a half by two inches. The parietal and frontal bones were, however, much thickened, so that the skull was "bossy" and natiform. The flatness of the root of the nose and an enlarged spleen were additional arguments in favour of syphilis. The family history was also of the most marked kind.

The father was a drill master and formerly a sergeant in the regular forces. He admitted having had syphilis, and a personal examination left no doubt on the point, for there was on his abdominal surface on the right side an extensive area, on which grew a tubercular and squamous eruption of unmistakable character.

There were four children of the family, all now dead. The first, which I did not see, died at nineteen months of age of "consumptive bowels." The second was the case now in question, and the third was a girl aged four months who was under my care, and on whom I made a *post-mortem* examination; she died from hæmatemesis and epistaxis, the associates of interstitial hepatitis, a large spleen and other evidences of syphilis on the face, mouth, and bottom.

Ernest G— was put upon iodide of iron and mercurial inunction, with good food, fresh air, and cod-liver oil. His health began steadily to mend, and very slowly the hydrocephalus receded, until at the age of three and a half years his skull seemed securely consolidated and his general condition very satisfactory. But at this time his eyesight began to fail more decidedly, and he was

Digitized by Google

seen by Mr. Marcus Gunn, who discovered extensive atrophy of the choroid, and degenerative disease about the macula lutea. His head was anointed at frequent intervals with mercurial ointment, and the sight certainly seemed to have improved; his attendances at my clinic became fewer and fewer, until August 18th, 1888, when he appeared again with a well-marked left hemiplegia; the arm and leg were rigid, the knee-jerk was exaggerated, a front tap, an ankle-clonus and a wrist contraction were obtained. His head was ordered to be shaved, and fresh inunctions of mercurial ointment ordered. I now began to visit my patient at his home, the Industrial Schools at Lewisham, and made many clinical observations on him, the details of which have but little interest in connection with the morbid anatomy of the case.

A new thing happened on October 11th, 1888, for at breakfast he spoke for the last time in asking for some "more fish."

On October 13th I saw him and found him speechless, and with very marked right hemiplegia. The right knee-jerk could not be obtained. The temperature in the rectum was not raised.

On October 14th, 1888, my notes state that the eyes are mostly directed to the left, and are frequently moved further to the left, and that there was slight horizontal nystagmus in the left eye, whilst this additional movement to the left was taking place. The right knee-jerk was exaggerated to-day, an ankle-clonus could not be obtained. The left pupil was dilated, eight millimetres wide, the right measured four millimetres and varied in size during the deviation of the eye to the left.

His mental condition was the same on both days, and till his death. He moaned continuously, but articulated no recognisable words; he seemed to understand a little but was very restless and peevish. He was constantly kicking with the left leg, which had recovered a little power, though it was stiff and excessively irritable to percussion. The left arm too had recovered a little power since its paralysis six weeks before. His condition remained much the same, some difficulty of swallowing set in, his naso-pharynx became full of muco-pus, and death occurred on October 19th at 3 a.m.

I made the necropsy with Dr. Arkle at 3 p.m. on October 20th. On removing the calvaria, which was a little thickened and vascular, and of purple colour in the frontal and parietal regions, the dura mater, greatly thickened, especially in the temporal

Digitized by Google

Digitized by Google

Fig 1.

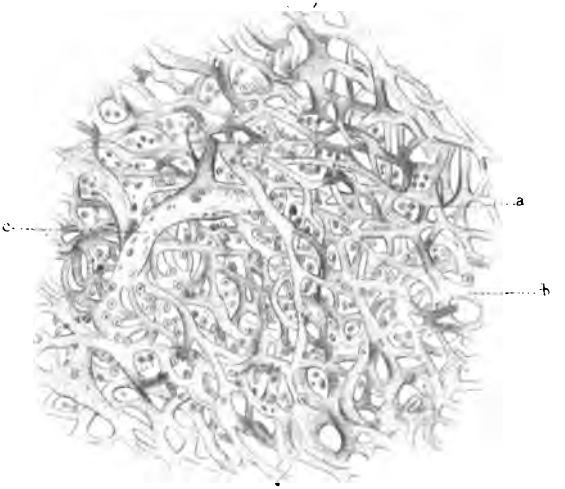

Fig. 2.

Digitized by Google

DESCRIPTION OF PLATE II.

FIG. 1 illustrates Mr. D'Arcy Power's case of Ossifying Sarcoma. (Page 293.)

The microscopical appearances presented by a nodule of ossifying sarcoma, which was secondary to sarcomatous disease of the knee-joint.

(*a*) Round sarcoma cells.
(*b*) Ossified trabeculæ.
(*c*) A capillary blood-vessel.

FIG. 2 illustrates Dr. Angel Money's paper on Syphilitic Meningitis. (Page 13.)

Two granulations from the ependyma, covering the corpus striatum, to illustrate the histology of the "shagreen" appearance.

Digitized by Google

Digitized by Google

regions, was exposed. The dura mater was adherent to the pia-arachnoid but could be separated therefrom. A great thickening of the pia-arachnoid, with some clear fluid in the subarachnoid space, were noteworthy facts. The obliteration of the subdural space by the adhesions between the dura mater and pia mater obtained all over the brain. The left hemisphere was exceedingly vascular, especially in its posterior half, and the colours recognisable were red, blue, and purple, the latter prevailing over the former. The hyperæmia was not patchy but uniform; section of the brain matter showed spots and striæ of redness, and in many places actual extravasations, especially in the sulci between the pia mater and cortex cerebri.

The right hemisphere was much less injected. The right "motor area" was much wasted, its sulci very deep, and its convolutions small and very hard. The right Sylvian artery and the right anterior cerebral artery were much thickened and opaque in an irregular manner, like that described in syphilitic arteritis. There was black fluid blood in the basilar, posterior, cerebral, and cerebellar arteries which were not thickened, but nearly all the arteries were too stiff and "cord-like" in appearance. The left Sylvian artery was but little affected. The right hemisphere was much distended by fluid within its ventricles, and collapsed greatly on being removed. The shrinking was most marked in the frontal lobe. There were no gummata on the nerves, but the nerves could not be dissected out of the thickened meninges. The optic nerves were decidedly atrophied.

The capsule of the spleen was thickened in its lower part. The valves of the heart were a little opaque and thickened, but no vegetations were to be observed on them.

The kidneys were healthy, and the lungs were only congested at their posterior halves. The other organs were natural. Microscopic sections have been kindly prepared, and drawings of some of the appearances made for me by Mr. C. F. Beadles, of University College Hospital (see plate).

The ependyma lining the ventricular surface of both caudate nuclei was markedly granular looking, as though sprinkled with fine grains of white sand. Sections of this part showed under the microscope a very large number of small round nuclei, very closely set together. The grains were similarly composed; their base was, however, of different structure, being more fibrous,

Digitized by Google

and giving the appearance as if the grains were not produced by a continuous budding from the thickened ependyma. It is possible that the granulations or grains are produced around a vascular loop because in some sections the base does seem to be of the same structure, and continuous with that of the thickened ependyma and surface of the brain immediately beneath.

The microscopy of the dura mater may be summed up by saying that it resembles the cartilage-like coating so common on the spleen and liver in cases of perisplenitis and perihepatitis, and like the corns on the surface of the heart. The under surface, which was agglutinated to the pia mater, shows more numerous nuclei, a looser and more vascular texture, with signs of periarteritis in the increased number of nuclei in and around its walls. The wavy dense bundles of connective tissue with few nuclei arranged in parallel series is well marked.

The arteries are of interest; one section exhibits complete obliteration of its lumen by fibrous tissue, with much destruction of the elastic membrane, such as is well known to occur in acquired syphilis, and the changes are in every respect the same in congenital syphilis (see a paper in 'Brain,' 1883, by the author). In some sections the blood in the arteries is in actual contact with the corrugated elastic lamina; this is probably due to *post-mortem* interference with the structure of the artery. The inflammatory changes in the arteries are not limited to the internal coat, and the greatest thickening is by no means always within the elastic membrane. Sections through the occipital lobe show the poverty of true nervous elements, the formation of numerous vacuoles and the small-celled infiltration, whilst the continuity of structure between the brain and thickened pia mater is well brought out. In this pia mater numerous vessels exhibiting slight inflammatory changes ramify and have been torn through in the separation of it from the dura mater.

The brain of a microcephalic child was also exhibited, showing atrophy and sclerosis of nearly the whole of the left hemisphere, without disease of the membranes or arteries, but yet, most probably, of syphilitic origin. The child died in convulsions, at the age of sixteen months; the brain weighed 14 oz.; there was some excess of fluid in the left ventricle, and beneath the pia mater of the atrophied left hemisphere. The child's head measured fifteen and three quarter inches in circumference and ten inches over the

Digitized by Google

vault. It could not stand nor sit nor talk, and seemed to recognise no one. Both legs were paralysed and spastic and also the right arm, but the left was moved about a little. The knee-jerks and wrist-jerks were marked, and there was ankle-clonus on both sides. The superficial reflexes were present on both sides.

January 29th, 1889.

---

3. *A case of hydatid cyst on the left cerebral hemisphere.*

By Hermann Weber, M.D.

M. P—, aged 22, a native of Poland, was admitted into the German Hospital on June 11th, 1888, soon after his arrival in this country. His illness had commenced, he stated, four weeks previously with headache, which occupied the whole head, gradually increased in severity, and was associated with nausea and occasional vomiting.

My colleague, Dr. Michel, the resident physician, to whom I am indebted for these notes, found the appearance of the man apathetic and stupid; the man seemed to comprehend slowly, and spoke rather indistinctly; he complained of frightful headache, and often held his head with both hands. His gait was somewhat unsteady; the muscular power in the whole of the left side, including the face, slightly diminished, although there was no real hemiplegia. The pupils were wide and sluggish in their movements; the right more so, and the left external rectus was slightly paralysed, so that the left eye could not be fully moved outwards. The ophthalmoscope showed a well-marked choked disc in both eyes (double optic neuritis,—Stauung's papilla). The sight was diminished, but he could count the fingers at a distance of about eighteen inches. The hearing seemed good, but he complained of loud noises in the left ear. The movements of the tongue were normal, as also the action of the sphincters of the rectum and bladder. There was some constipation. The urine was free from albumen and sugar. There was no tenderness of any part of the head. The temperature was slightly below the average (97° to 98°);

Digitized by Google

the pulse 68 to 80 without increased tension. These symptoms remained nearly the same during the first eight days, but rather increased in severity; and the apathetic condition was sometimes interrupted by fits of excitement, but there were neither convulsions nor unconsciousness. On the ninth day some peculiarity of respiration was observed, viz. that the thorax remained long in the state of inspiration, with fibrillar trembling action of the intercostal muscles. On the twelfth day the patient suddenly died.

The *post-mortem* examination showed nothing abnormal in the cranium; the vessels of the dura mater rather gorged; the sinuses empty; the substance of the brain dry; the gyri rather flattened. On the posterior lobe of the left hemisphere was an hydatid of the size of a small fist, which could be easily removed and left a deep hollow in the left hemisphere, lined by a perfectly smooth membrane. Left ventricle moderately dilated. The right hemisphere and cerebellum normal. The lungs and heart natural. The liver, spleen, and kidneys rather hard, somewhat enlarged and congested.

Remarks.—There are some peculiarities in the case:—1. The rather rapid course of the disease, considering that hydatids are in general of slow development. 2. That the hemiplegic symptoms were slight and were on the left side, the side of the lesion. 3. That the headache was not confined to any particular spot, but was in the whole of the head; and that there was no local tenderness at all.

As to *diagnosis*, Dr. Michel and myself were of opinion that there was a tumour; and Dr. Michel suggested that it might consist in an hydatid, but we were unable to fix the locality, and therefore did not venture to attempt an operation. It is the wish to elicit observations from members of the Society on the subject of the diagnosis which induced me to bring the case before the Society, so that others may perhaps in a similar case be able to save the patient; for had we known the exact seat of the hydatid we should have considered the operation and might probably have saved the life. I am afraid, however, that in the present state of our knowledge the exact diagnosis would have been almost impossible, as there was neither local pain nor local tenderness.

November 6th, 1888.

Digitized by Google

4. *Symmetrical sarcoma of both cerebral hemispheres.*

By J. A. Ormerod, M.D.

This is a specimen exhibiting disease almost symmetrical of the white matter of both hemispheres, due, as I believe, to new growth.

The patient was a man aged 31, who combined the professions of fancy box-coverer and prize-fighter. He was admitted to St. Bartholomew's Hospital under Dr. Gee on February 24th, 1888. His symptoms were of two days' duration, and consisted of headache, fever (temp. 102°), and a tendency to profuse sweats.

He denied syphilis, but admitted having drunk freely.

In about a week the neck and back were noted to be stiff. Optic neuritis developed. Then palsy of the right face and convergent squint of the right eye. Coma, preceded by talkative delirium, set in gradually. In the second week of March, right hemiplegia. Also a tendency to rigidity of the limbs, with exaggerated tendon-reactions, and even opisthotonos. He died in about five weeks from the onset. The temperature rose suddenly before death to 108°.

A definite diagnosis could not be made, but meningitis was thought to be most probable.

Post mortem the membranes were healthy, except that the arachnoid seemed a little more watery than usual. Much clear fluid exuded from the interior of the brain. The arteries were quite normal, and nowhere plugged.

A horizontal section made through the brain at the level of the basic ganglia showed no disease, except some softening of the fornix and distension of the ventricles with fluid.

Vertical sections (after Pitres' plan) were then made through the upper halves of the hemispheres which had been removed by the horizontal section, and these I now exhibit.

There was seen in the left frontal section an irregularly shaped patch of soft reddish tissue occupying nearly the centre of the corona radiata. In the sections next in front (left pediculo-frontal) and next behind (left parietal) were almost similar appearances. Smaller patches of disease were found (in the hardened specimens)

Digitized by Google

in the sections through the occipital lobe. On the right side there were like patches similarly situated, but smaller.

Thus it appears that in the corona radiata of either hemisphere there is a tract of disease, stretching antero-posteriorly, roughly club-shaped, and being biggest just opposite the motor convolutions, and tailing off rapidly towards its occipital end. On the left side it is broader on section than on the right, and reaches rather further forward (viz. a short way into the frontal lobe) upon the left side. Further there is extensive softening of the neighbouring white matter in the left parietal section, and this no doubt was the cause of the right hemiplegia.

Microscopic sections show that the soft red central patch (on each side) consists of very large rounded nucleated cells, some indeed with two or more nuclei. Scarcely any interstitial tissue is visible. There are abundant blood-vessels. I believe it to be a sarcomatous growth.

There were no growths in any other part of the body. Except for extreme congestion of the middle lobe of the right lung, all the other organs were normal. (Spinal cord was not examined.)

February 5th, 1889.

---

5. *Multiple tubercular tumours in the brain of a child aged* 1 *year.* (*Card specimen.*)

By Norman Dalton, M.D.

There are three tumours. 1. In the pons. 2. At the back part of the right internal capsule. 3. In cerebellum. There was no meninigitis. Death was due to ulcerative stomatitis. At the *post-mortem* miliary tubercles were found in nearly all the organs. There was no history either of tuberculosis in the family nor of syphilis. The symptoms appear to date from December 14th, when the child had a fall. There was paresis of the limbs on both sides, and well-marked athetosis of the right arm, otherwise there were no distinctive symptoms. *January 29th*, 1889.

Digitized by Google

6. *Hæmorrhage into pons Varolii.* (*Card specimen.*)

By J. A. Ormerod, M.D.

There was an independent hæmorrhage into the left cerebral hemisphere of the size and situation indicated in the diagram. Also a hæmorrhage in the left side of the pons, reaching from the inferior of the corpora quadrigemina to the upper part of the medulla. It involved the nuclei of the fifth, facial, and auditory nerves of the left side. The sixth would probably be pressed upon. The motor tract was not involved.

The patient, a female aged 38, was in St. Bartholomew's under Dr. Gee. She had complete left facial palsy, complete deafness of left ear, almost complete paralysis of left ocular movements, incomplete ditto of right. Anæsthesia of right face and limbs, and weakness of right arm and leg. Four days after admission she became comatose and died. *February 5th*, 1889.

---

7. *Hæmorrhage into the pons of child aged* 6. (*Card specimen.*)

By William Collier, M.D.

Lily W—, aged 6, was admitted to the Radcliffe Infirmary March 20th, 1889. Died March 28th. Was in good health until three weeks before her admission, when she was said to have caught cold. From this date she suffered from severe headache, vomiting, and increasing disinclination to move about, with progressive weakness of legs and left arm. Her previous health had been very good. Father and mother were alive and well. She had eleven brothers and sisters all healthy.

She was a delicate-looking child, with decided ptosis at right eyelid, paresis of muscles of half side of face, tongue pointed to the right. There was marked loss of power with rigidity in both legs, the left more than the right. Sensation blunted in lower limbs. Patellar reflex normal. No ankle-clonus. Pupils reacted to light,

Digitized by Google

and were equal. She was quite sensible, and complained of severe frontal and vertical headache. Ophthalmoscope showed double optic neuritis. All the organs healthy. Urine normal. After admission all the symptoms increased in severity. She vomited at intervals, the paralysis increased, the temperature rose rapidly a few hours before death to 108°.

Post-mortem notes.—On removing the brain the pons was seen to be much enlarged, especially the right half. Occupying the posterior half of the interpeduncular space was a quantity of flocculent lymph and gelatinous material resembling blood-clot. On washing this away, a small vein about the size of a No. 1 English catheter was found completely blocked by a dark clot. At inner margin of right crus a blood-clot about the size of a cherry was seen, pushing the crus outwards, and partly eroding its substance. On further examination the clot was found to be continuous with a larger clot which occupied the greater part of the substance of right half of the pons. No disease at any other part of the body discovered. *May 21st*, 1889.

---

8. *Infantile paralysis.* (*Card specimen.*)

By R. G. Hebb, M.D.

A. S—, a female, aged 2 years and 5 months, was admitted into Westminster Hospital December 28th, 1888, under Dr. Donkin. About the middle to the end of September, 1888, was taken suddenly "sick;" quite recovered next day. Two days after while standing at table suddenly cried out, and it was found that she could not use the left leg or walk. A fortnight later lost power in the right leg, but recovered it in seven weeks. Left leg has remained useless ever since. Otherwise has been fairly well. On admission the left leg was found to be palsied from hip downwards; muscles flabby and wasted. The right was apparently unaffected, but two weeks after admission it was noticed that it was paretic but not completely palsied like the left, the muscles of which gave the reaction of degeneration. There are contractions of calf-muscles on faradizing internal popliteal nerve. On right side re-

Digitized by Google

actions are apparently normal, though galvanic current did not easily produce contractions. There was no palsy of the arms. On January 17th temperature suddenly rose to 103·8°. By February 4th symptoms of tubercular meningitis had well developed, and the patient died February 9th. On *post-mortem* examination eight hours after, the usual appearance of tubercular meningitis were found in brain and upper part of cord; the grey matter of the cord was distinctly pink throughout; and after hardening in Ammon. Bichrom. it was seen that the centre of the grey matter in the left anterior cornu of the lumbar region was much paler than the right.

On microscopical examination it was found that (1), although the severity of the disease is most marked in the lumbar region, the anterior cornu is affected *all down the left side*, and this cornu is also diminished in size. (2) The shape of the left half of the cord, from the dorsal region downwards, is much altered; the front half, where the anterior rootlets make exit, losing its curve in the dorsal region, where it is flattened, and in the lumbar region becoming markedly incurved. (3) Examination with low powers shows that even in the upper cervical region the multipolar cells are greatly lessened in quantity; that in the dorsal region they disappear; and that in the lumbar region the grey matter is replaced by a thin fibrous tissue, traversed by numerous blood-vessels. (4) On the right side of cord the number of multipolar cells is also much diminished. (5) Examination with higher powers discovers remains of cells in various stages of atrophy. Neither they nor their immediate vicinity shows any evidence of an inflammation specially affecting them; hence it would seem that their disappearance and wasting stand in a similar relation to an undetermined cause, just as the wasting of the muscles to them. (6) The large cells in the upper (posterior) portion of pons are considerably pigmented, and the left sciatic nerve (which is distinctly smaller than the right) contains a large quantity of withered tubules.

In some respects the microscopical appearances and the clinical history are in marked agreement, *e. g.* the condition of the lumbar region accords with the symptoms observed during life; but it should be noted that while the cord is affected, though unequally, throughout its extent, there was during life no obvious affection of the parts supplied by the cord above the lumbar region.

Duration of the disease about eighteen weeks.

April 16th, 1889.

Digitized by Google

9. *Pseudo-hypertrophic paralysis; affection of the heart and diaphragm; area of softening in the cord; degeneration and atrophy of the nerve-trunks.*

By H. Handford, M.D.

[With Plate I.]

The boy who forms the subject of the present paper was 17¾ years old at the time of his death. The following family history was obtained:—His father is a very stoutly-built, robust collier, residing in a small Derbyshire village, and is aged 52. His mother is a spare but active and healthy woman aged 60. They have had four children. The eldest a woman aged 27, is strong and in good health, and is a domestic servant. The second, a boy, died four years ago at the age of 16½ years, apparently of pseudo-hypertrophic paralysis, which commenced when he was four or five years old. I never had the opportunity of seeing him. The third is the subject of this paper. The fourth is a girl, aged 14, and is in good health.

The third child, the subject of this communication, began to be affected at the age of 5 years. His general health was good, except for periodical attacks of sickness and vomiting. In the end of 1881 and beginning of 1882 he was a patient in the General Hospital, Nottingham, for a period of four months. He was then 10¾ years old, and the disease had been in progress six years. He had at that time all the classical symptoms of pseudo-hypertrophic paralysis, but he improved considerably during his stay in the hospital.

In December, 1886, I found him in a Derbyshire village, well nourished, and as intelligent as could be expected for a boy who had never been to school. For four years (eventually six) he had been unable to walk or move about by himself, and for three years (eventually five) he had been unable to stand, even when helping himself with his arms. He never had any incontinence of urine or fæces, or any interference with the functions of the bladder or rectum. The sexual organs were well developed. His voice was usually rather deep, but occasionally he would speak a whole sen-

Digitized by Google

tence in the shrill falsetto of a child. These sudden alterations in the pitch of the voice were not under voluntary control, and were much more marked than is usual when the voice is "breaking." The condition was so striking as to suggest some impairment of the laryngeal muscles. (Unfortunately they were not examined at the *post-mortem*, and the point was not cleared up.) He had no difficulty in respiration or in swallowing. Sensation was normal, so far as could be ascertained by rough tests. No electrical examination could be carried out. The knee-jerks were completely absent on both sides; the plantar reflex was imperfect. The patient could feel the tickling of the soles, and occasionally the calf-muscles twitched in response, causing a contraction of sharply localised portions of the calf (a coarser motion than fibrillary twitching), but there was no movement of the foot or leg. He was very sensitive to tickling under the arms and also on the back. The calves were strikingly large, and measured, the right thirteen and three quarters inches, the left fifteen and a quarter inches. The calves were flabby, and one could feel the individual muscular masses with the intervening loose tissue, just like a bag of hard sausages. When lying on his back he could not raise his head from the pillow or lift his heel from the bed. When sitting there was a well-marked lateral curvature of the spine with the convexity to the left. The erector spinæ was small. The forearms were of average size and the muscles hard, but the grasp of the hands was extremely feeble; the upper arms were very small and flabby; the right deltoid was of about the normal size, but the left was very small. With the arms hanging straight down he could not move them from the side in any direction. When he leaned on the arms the ligaments of the elbow gave way, so that the angle on the flexor surface was about 210°, and on the extensor about 150°; that is to say the forearm was extended about 30° beyond the straight line. The thyroid was not definitely enlarged, but the neck was rather full. He never had any fits. There was no œdema of any part.

In the latter part of 1888 he caught cold during the severe foggy weather, and died of bronchitis, after two or three days' illness, on December 31st, 1888, at the age of 17¾ years. Through the kindness of Dr. Fielding I was able to go over on the receipt of a telegram, and make an inspection the same afternoon, fourteen hours *post mortem*. The difficulty of making such an examination by candle-light and unassisted, in a garret seven feet by five feet, must

Digitized by Google

be my excuse for not examining the brain, and for other shortcomings, more especially a more careful dissection of the trapezii and the pectoral muscles, and of the smaller peripheral nerves.

There was no rigor mortis, although the body felt cold and was in a room without a fire, and the state of the weather was a hard frost. The lateral spinal curvature had increased and become permanent. The erector spinæ consisted almost entirely of fat with a few pale reddish fibres here and there. The calf-muscles were in much the same condition. No adequate search was made for the trapezii. I could not find any trace of the pectorals, but the regions of their insertion into the humerus and coracoid were not examined, so that I am not in a position to say whether they were absent. The diaphragm hardly showed any trace of muscular structure to the naked eye. It was not examined microscopically. The blood was remarkably fluid. Possibly this was due to the mode of death, which was apparently from asphyxia. The vessels of the spinal canal were very much engorged, probably from hypostasis. The cord was removed and placed at once in a 2 per cent. bichromate of potash solution. Portions of the sciatic and popliteal nerves and their branches, the anterior crural, the cervical portion of the vagus, and the middle cervical ganglion of the sympathetic were removed and placed, some in bichromate solution, and some in proof spirit. On reaching home some of the fragments in the proof spirit were transferred to absolute alcohol, and the rest washed in distilled water and hardened in a 1 per cent. solution of osmic acid. The lungs showed signs of broncho-pneumonia and hypostatic pneumonia. The heart was of average size and free from valvular disease; there was no means of weighing it. The layer of subepicardial fat was greater than usual in a lad of seventeen, and had burrowed somewhat into the muscular substance. Portions of the heart, liver, kidney, adrenals, stomach, and large and small intestines were preserved for microscopic examination.

Pseudo-hypertrophic paralysis is a disease the pathology of which, using the word in its widest sense, is not yet sufficiently definite for it to be a work of supererogation to make a detailed examination of all the organs. It is not at all certainly known why some muscles become large and hard from the interstitial formation of fat, why others remain of average size or shortened and unduly hard from the formation of fibrous tissue, and why others atrophy without enlarging and without excessive formation of fibrous tissue

Digitized by Google

Digitized by Google

DESCRIPTION OF PLATE I.

To illustrate Dr. Handford's paper on Pseudo-hypertrophic Paralysis. (Page 24.)

FIG. 1.—Transverse section of the spinal cord (lower part of the brachial enlargement?), hardened in 2½ per cent. bichromate of potash solution, and stained with aniline blue black. Zeiss, A, oc. 2. Notice the inequality in the size of the grey matter on the two sides, the patch of softening on the right in the grey matter, and the general integrity of the ganglion-cells. The central canal is filled with proliferated cells. In the softened area was a very large number of coloured blood-corpuscles and leucocytes. The staining round the margin was more intense. These facts show that the cavity was not due to imperfect hardening or manipulation of the section.

FIG. 2.—Transverse section of small muscular branch of internal popliteal nerve, stained with alum carmine. The majority of the fibres are degenerated, only a few healthy ones remaining.

FIG. 3.—Portion of transverse section of vagus in the neck, hardened in alcohol, and stained with aniline blue black. Four medium-sized medullated fibres and several masses containing fine medullated fibres, and either nuclei or transverse sections of non-medullated fibres.

FIG. 4.—Transverse section of the sciatic nerve, hardened in osmic acid, and stained with alum carmine. A few full-sized medullated nerve-fibres from $\frac{1}{1600}$th to $\frac{1}{3600}$th of an inch, and a large number of very small fibres (? atrophied fibres). A connective-tissue mass at the top, in which a few fibres are apparently embedded.

Digitized by Google

Fig 1

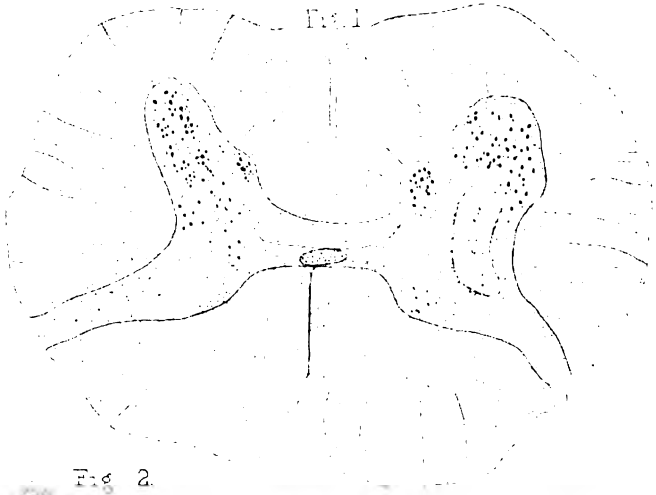

Fig 2.

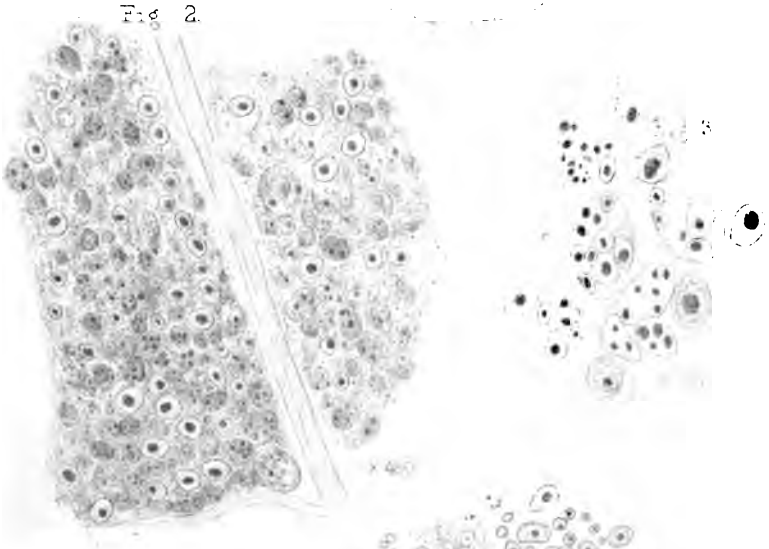

Fig 4

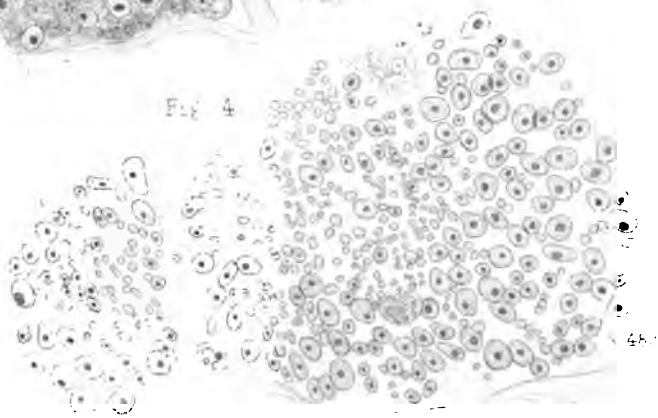

Digitized by Google

Digitized by Google

or fat; although all three varieties may be met with in the same case. The condition of the affected muscles in the first instance is indistinguishable from that resulting from degeneration of the motor nerves. The perfectly healthy condition and well-marked striation of the few muscular fibres that remained embedded in the fat in the present case were very striking, and would accord well with the fact that "in most lesions of nerves, other than actual division, some fibres recover even though others are permanently destroyed." The changes in the nerves to be presently described give some support to that view.

The muscles in the second series closely resemble a chronic myositis, and the affection could be paralleled by the still rarer myositis ossificans. From the observation of five or six cases of pseudo-hypertrophic paralysis I am inclined to think that the disease frequently comes on rather rapidly, advances very irregularly, often remaining quiescent for long periods and sometimes improving somewhat, though eventually progressing to a fatal termination. I am not clear, too, that there is not in the early stages some tenderness of the muscles.

The heart and the hollow viscera were examined with a view of ascertaining whether the involuntary muscles shared at all in the degeneration of the rest of the muscular system. The result, as detailed below, shows that the non-striped fibres were not at all affected, but that the striped fibres of the heart and of the diphragm were extensively degenerated.

In turning to the microscopic examination I may say at the outset that I could find no alteration in the liver, kidney, adrenals, and stomach and large or small intestine. The muscular coats of the latter were not thickened or altered.

The voluntary muscles examined were the soleus and the erector spinæ. Any fibrous tissue between the muscular fibres was completely obscured by fat-cells, which were present in enormous numbers. The few muscular fibres were well striated and of good size with very few exceptions. This would indicate that any process of degeneration was not actively proceeding. The muscular fibres were not so examined as to enable me to give an opinion as to the condition of the terminal end organs of the motor nerves.

Although there was no excessive fatty overloading of the heart the muscular fibres of both right and left ventricles were separated by an excess of fibrous and fatty tissue, and the muscle-cells them-

Digitized by Google

selves were in many instances most evidently atrophied and degenerated, and in some places they had quite disappeared. I have no means of proving that the process was essentially the same as the pseudo-hypertrophy of the voluntary muscles, but so far as the structural alterations are concerned there is no visible difference between them. At the age of seventeen, even after five or six years of paralysis, the heart, though sure to be small and feeble, does not necessarily become subject to fatty infiltration and consequent pressure atrophy of the muscular fibres. The advanced degeneration of the diaphragm, although its fibres are of a different kind, strengthens the view that the heart affection was part of the pseudo-hypertrophic process.

Turning next to the nervous system. I had no opportunity of examining the brain, but should not have expected to find any change in it. The spinal cord presented no change to the naked eye. It was successfully hardened in a 2½ per cent. bichromate of potash solution. Sections were cut, after freezing, every half inch throughout the whole length of the cord and were stained with alum-carmine, aniline blue-black, logwood by Weigert's method, and in other ways, and in every one of the scores of sections examined many healthy ganglion-cells were seen in the anterior horns and elsewhere in the grey matter. They were in the main in good condition, but in most sections cells could be seen here and there pigmented, or that did not stain well, or that had lost their processes, or in some way appeared degenerated. Such cells were, however, on the whole very few. The ganglion-cells seemed to be in the usual numbers, but a more exact map of the size, position, and number of the cells in the average normal condition is required before any moderate deficiency in their numbers can be readily detected. Still I think I am in a position to say that no such deficiency in number was observed as would account for such an extensive muscular atrophy as existed in this case. In the intermediate grey matter of the upper part of the lumbar enlargement an area of softening was found, and there was a striking inequality in the shape and size of the grey matter on the two sides.

That the area of softening was not artificially produced by manipulation or imperfect hardening was shown by the deeper staining around the margins of the patch, and by the large numbers of blood-corpuscles and leucocytes in the patch, as well as the breaking up of the nervous elements. It was what one would call in the

Digitized by Google

brain red softening, and was due, I have little doubt, to a hæmorrhage. After careful examination no other similar patches were found elsewhere in the cord.

The vessels of the cord generally were somewhat engorged. It is possible that the exaggerated lateral curvature of the spine may have had something to do with causing the inequality in the size and shape of the grey matter on the two sides. Though inequality of the grey matter is unusual, it is found sufficiently frequently to render it doubtful whether it has any definite pathological significance. After finding this area of softening I see that Gowers and Lockhart Clarke described an exactly similar condition in a case examined by them some years ago. It is a remarkable coincidence, but it is doubtful whether it is anything more. It appeared quite recent, and may indicate some delicacy of the vessels.

In approaching the examination of the nerve-trunks, I have felt very much the want of more accurate and precise standards of the normal histology, and of the variations that may be met with within the limits of health. We have many atlases of pathology, but not sufficiently good and detailed illustrations of the variations in the organs in health. It is well known that the size of the nerve-fibres in the spinal cord varies much in different columns, and in different parts of the same column. It is known that they are smallest in the postero-median, or Goll's column, and largest in the crossed and direct pyramidal tracts. But the exact significance of this is not known. The time must come when in a transverse section of the cord the nerve-fibres will be mapped out by their size, appearance, and arrangement, as well as by their function, more definitely than the ganglion-cells in the grey matter are at present, and at least as accurately as the convolutions of the brain or the stars in the heavens.

Again, there is very little information available as to the normal proportion of medullated and non-medullated fibres in the nerve-trunks, and as to the relative size of the medullated fibres. Schwalbe supposes that, in the spinal nerves, those fibres are thickest which have the longest course before they reach their end organs, whereas Gaskell finds that the longest nerves are not necessarily the thickest; for the visceral nerves in the vagus are small nerves, and yet run a very long course. It is more probable that, as in the case of electricity, the amount of electro-motive

Digitized by Google

force that can be conveyed along a wire depends on its sectional area; so in the nervous system the amount of nervous energy that can be transmitted along a nerve-fibre depends on its size; and that consequently the largest nerve-fibres go to the largest tissue elements. It is probable that the largest motor nerve-fibres go to the coarse-fibred muscles. We know that the visceral nerve-fibres in the vagus going to small tissue elements (not striped muscular fibres, &c.) are themselves small. We do not know yet whether there is any structural difference between sensory and motor nerves; or whether, as seems probable, the one may not be capable of uniting with the other, and of conducting in either direction. Till these points are cleared up it must remain a matter of much difficulty to detect any but the coarser and more pronounced alterations of disease.

From what we know of the process of repair of nerves after injury; from the fact that, whether in the lower animals or in man, unless in excision nearly an inch be removed, the two ends of the nerve will reunite in the course of a few weeks or months, and restoration of function follow, we must suppose that in health the process of nutrition in the nerve-trunks goes on very actively. It is not improbable that a few fibres here and there are frequently degenerating and being replaced by regenerated ones.

Nothwithstanding the general truth of the Wallerian law of the degeneration of nerve-fibres, it has been shown[1] that "continued inaction of a nerve diminishes and may ultimately abolish the excitability. Thus the central ends of divided sensory nerves after amputation of a limb lose their excitability, although the nerves are still connected with the central nervous system, because the end organs through which they were normally excited have been removed." In like manner with the motor fibres. I cannot imagine that when the muscular fibres to which they go have disappeared by degeneration, and ceased to exist, the motor nerve-fibres *in the course of a sufficiently long time* should not atrophy from abolition of their function, although they remain in undisturbed continuity with the motor ganglion-cells, in the anterior horns of the grey matter of the spinal cord. It would be contrary to all experience that tissues whose functional activity has ceased should not in the course of years—and pseudo-hypertrophic paralysis lasts many years—undergo atrophy from disease. If

[1] Landois' 'Physiology,' p. 784, 2nd edition.

Digitized by Google

this principle be granted, it makes it a matter of much difficulty to decide whether the changes in the nerve-trunks and in the small peripheral nerves is the primary morbid condition or is secondary to the muscular degeneration. It has been shown in the case of the octopus,[1] that muscular fibres possess a certain degree of functional activity independent of any connection with the nervous system. Cardiac muscular fibres have been shown to possess the power of rhythmical contraction when quite cut off from nerve-fibres and nerve-cells. Nutritional independence must accompany functional independence, and so a primary muscular atrophy becomes possible. In fact for some years past good grounds have existed for supposing that primary muscular atrophy is a not uncommon disease. Such, it is now supposed, is the nature of pseudo-hypertrophic paralysis, but of the pseudo-hypertrophy no adequate explanation has been given, nor has any satisfactory reason been assigned for its difference from the other examples of idiopathic, or primary, muscular atrophy.

As pseudo-hypertrophic paralysis runs such a very chronic course, it was not to be expected that the appearances which characterise a rapid degeneration of nerve-fibres should be found. A few fibres both from the popliteals and from branches of the anterior crural were teased in glycerine after hardening in a 1 per cent. solution of osmic acid. No such changes as segmentation of the myelin or nodosity of the fibres could be detected. Unfortunately, the small intramuscular nerves were not so examined. Both transverse and longitudinal sections were cut after freezing, and stained with alum-carmine, aniline blue-black, osmic acid, Weigert's logwood method, and in other ways. In none of these nerves examined was there any increase of the connective tissue. In the numerous sections of the sciatic nerve the proportion of degenerating fibres in which the axis-cylinder had disappeared, and the myelin was represented by a granular mass, was very small. A very striking feature, however, which I have not met with in the examination of the nerves of numerous subjects dying of accident or acute disease, was the very small number of the large medullated fibres of which the normal nerve-trunks chiefly consist, and the immense predominance of very small medullated fibres down to one seven thousandth, or even one ten thousandth

[1] Ransom, "On the Cardiac Rhythm of Invertebrata," 'Journal of Physiology,' vol. v, No. 4.

Digitized by Google

of an inch in diameter. Most of these presented the normal structure of axis-cylinder, medullary sheath of myelin, and primitive sheath. But in the case of the very small ones, even with a power of 960 diameters (one twelfth homogeneous immersion), it was not easy in all cases to distinguish the cross section of an empty primitive sheath passing through a nucleus, the axis-cylinder and myelin having disappeared, from the cross section of a small non-medullated fibre, especially if cut slightly obliquely. The nuclei of the primitive sheath in many places, I feel no doubt, were more numerous than normal, and had proliferated. Here and there three or four angular-shaped nuclei, larger, more deeply stained than, and differing in shape from, cross sections of axis-cylinders, were contained within one rounded enclosure resembling a large primitive sheath. There can be little doubt they were proliferated nuclei, the axis-cylinder and myelin having disappeared. Both in the sciatic and the plantar nerves there were very numerous instances of a number of minute nerve-fibres grouped together and forming a bundle within one sheath, and having an area somewhat larger than the cross section of a large medullated fibre. They closely resembled the appearance of nerve-fibres in process of regeneration as represented in fig. 286 of 'Ziegler's Pathology.'

The popliteal and the plantar nerves were in much the same condition as the sciatic. But the smaller branches of the anterior crural, and the muscular branches of the internal popliteal to the calf-muscles were extensively degenerated and showed only a small proportion of healthy fibres. The perfect condition of the healthy fibres, in which such details as the small protoplasmic area around the axis-cylinder and the protoplasmic lining of the primitive sheath could be seen, showed that the nervous structures had not suffered in the course of preparation. The vagus was examined both fresh by teasing and in numerous sections from different parts, but no definite change could be detected. In the sympathetic system many of the ganglion-cells in the middle cervical ganglion showed extensive pigmentary degeneration, but no other changes could be detected.

I repeat that I have no means of showing whether the above-described changes were primary or secondary. The grounds against their being primary are that no sensory disturbances were present during life in this case, nor have they been described in others. And, moreover, the changes hardly seemed sufficiently

Digitized by Google

extensive, especially in the larger trunks, to account for such an advanced and very widely spread muscular atrophy. I think, however, I have made out a case for the further investigation of the following points:

The presence of degeneration and atrophy of the peripheral nerves in pseudo-hypertrophic paralysis.

The question whether such degeneration and atrophy, when found, is primary or secondary.

The normal proportion of large and small fibres in the principal nerves.

A means of distinguishing microscopically motor, sensory, and vaso-motor fibres. *March 5th*, 1889.

Digitized by Google

II. DISEASES, ETC., OF THE ORGANS OF RESPIRATION.

1. *Congenital growths in the larynx.*

By Lennox Browne.

Alfred A—, aged 3, was brought to the Central London Throat and Ear Hospital, as an out-patient, on 3rd December, 1888, and was admitted three days later.

History.—Since birth the child had never had any voice, and had always suffered more or less from difficulty of breathing, which had increased in the last six weeks. He was reported to sleep with mouth widely open, and to breathe loudly. He had occasional cough, which was aphonic in character. The child was also reported to suffer slightly from headache.

Condition on admission.—A well-nourished and healthy-looking child, but with a *voice* absolutely aphonic. During physical examination he emitted a faint and almost toneless cry. The *respiration* was laboured, and there was slight in-sucking of the lower costal cartilages on both sides. Inspiration was loudly stridulous. Air entered each lung equally, but the chest was by no means fully expanded. The *fauces* were congested, and with the laryngoscope the *glottis* was seen to be filled with growths. A No. 3 intubation tube was introduced experimentally and was followed by immediate benefit to the breathing, but the mother not desiring to leave the child it was withdrawn after a short time.

The day following admission a serious increase in the dyspnœa occurred, and in my absence, my colleague, Mr. Jakins, again performed intubation. This was followed by hæmorrhage, and the tube was immediately withdrawn. The boy became speedily asphyxiated, but was relieved by extending the head backwards. However, the dyspnœa returning as soon as the normal position was resumed, Mr. Jakins promptly performed tracheotomy, and re established vitality by artificial respiration. Up till the after-

Digitized by Google

noon of the following day, the patient seemed fairly comfortable, with the exception that his breathing was rather jerky. About 5 p.m., that is twenty-four hours after the tracheotomy, a burst of hæmorrhage took place from the tube, which was withdrawn, and the wound kept open by means of a dilator. At 6 the tube was again introduced, and at 7.30 the hæmorrhage recurred; the same measures were repeated but with less success; respiration steadily deteriorated, and the child died about forty hours after the operation, of apnœa.

Autopsy twelve hours after death.—The tracheotomy wound was of healthy appearance, and there were no signs of any external hæmorrhage. On opening the *larynx*, the laryngeal aspect of the *epiglottis* was seen to be abnormally red and slightly granular. Two minute cysts about the size of a pin's head were also visible. On both the *vocal cords*, and on both ventricular bands, were a collection of warty growths. There was an abraded and hæmorrhagic point on the right cord whence the bleeding had evidently come at the second introduction of the intubation tube.

Microscopic examination demonstrated that the growths were of truly papillomatous structure. Both *lungs* were very much collapsed, and were not larger than those of an infant at term. The edges and substance for some distance inwards were in a corneified condition (atelectasis). At the apex of each lung, and in the lowest lobe of the right, were large areas, three in all, of pulmonary hæmorrhage. These were probably the sources of the bleeding which took place subsequently to the tracheotomy.

Remarks.—The interest of this case consists in the fact that it presents, so far as I can ascertain, a hitherto unrecorded source of danger from tracheotomy in an infant, the subject of congenital obstruction to laryngeal respiration. There can be but little doubt that the increased volume of air admitted by means of the tracheotomy tube led to rupture of lung tissue, which had never been expanded to its normal capacity. It also indicates that tubage is contra-indicated in cases of laryngeal new growths.

March 5th, 1889.

Digitized by Google

2. *Fracture of thyroid and cricoid cortilages.* (*Card specimen.*)

By H. MONTAGUE MURRAY, M.D.

A DRUNKEN man, aged 58, fell backwards under an omnibus. It was believed that one of the wheels passed over him. His chin was cut in two places, and his neck and upper part of chest were much bruised. Crepitus could be felt in the neighbourhood of the cricoid. General emphysema rapidly set in, causing great distension of the tissues of the neck, and extending almost as low as the umbilicus. Patient died from asphyxia eighteen hours after the accident.

Post-mortem examination. — General extravasation of blood through tissues of neck and parietes of upper part of chest. Cavities, size of an olive, found in areolar tissue over trachea. These contained air. Hyoid bone uninjured. Thyroid cartilage (ossified) fractured in two places:—(1) On right side, commencing quarter of an inch from middle line below, running vertically upwards for one third of an inch, and then communicating with right side of interalar notch by a fissure. The plane of this fracture runs backwards and to the right. (2) The second fracture is also mainly vertical. Its course is upwards and a little forwards through the middle of the left ala. The outer portion is bent slightly inwards.

The *cricoid* (ossified) is fractured vertically, rather less than one third of an inch to the left of the middle line. The outer fragment is displaced forwards and inwards.

The third, fourth, fifth, tenth, and eleventh *tracheal rings* are also fractured, all a little to the left of the middle line.

The *perichondrium* over the fracture in the cricoid, in the left ala of the thyroid, and the lower part of that in the right, is torn. There is considerable hæmorrhage into the submucous tissue, of both larynx and trachea, but no rupture in the *mucous membrane.*

The pleural surfaces are everywhere adherent.

The second left rib is fractured near the spine; the first, second, and third right ribs near the spine; the second and third right ribs also in the front axillary line; and the fourth right rib just outside the costal cartilage.

The upper fragments have wounded the lung on the right side. No large vessel is injured. *November 6th*, 1888.

Digitized by Google

3. *Diphtheritic membrane expelled from a tracheal wound.* (*Card specimen.*)

By William Henry Battle, for Dr. F. E. Nichol.

These remarkable casts were expelled from the trachea of a boy, aged 11, under the care of Dr. Nichol, who performed tracheotomy for symptoms of urgent laryngeal obstruction.

The largest is an almost complete cast of the lower part of the trachea with bronchi, and measures more than four inches in length, the upper three inches being almost complete and without a branch, the remainder being branched to a considerable extent, having come, at the terminations of these branches, from bronchi as low as the fourth division. It resembles much the appearance of a tree pulled up by its roots, and is firm and tough.

This was the first cast expelled from the wound on the day of operation, viz. the 25th, being the fifteenth day of disease.

The cast which is next in size, although forming a continuous membrane of about five inches in length from end to end, is not complete, is of more varying thickness, and terminates in a filamentary offshoot which may have come from a minute bronchus. This was expelled through the tube (No. 2 Durham) on the 26th.

The three smaller pieces were expelled within a short time and were probably continuous in the air passages; they vary in length from two and a half to two inches, and when combined equal in length and size the second piece exhibited. They were expelled before midnight on the 26th.

Other small pieces were expelled at times, but they were not kept.

The boy afterwards suffered from albuminuria, and at the end of a month from paralysis of accommodation, but made a perfect recovery. The tube was kept in for eight days.

It is worthy of note that the intervals which elapsed between the expulsion of the casts were very short, and that the invasion of the larynx and trachea appeared after complete subsidence of faucial and pharyngeal affection, when the boy appeared to be commencing convalescence. *May* 21*st*, 1889.

Digitized by Google

4. *Caseous bronchial gland perforating and obstructing the trachea.*

By G. Gulliver, M.B.

This specimen, which was taken from the body of a child aged 4, shows the larynx, trachea, and principal bronchi together with enlarged glands in the neighbourhood. The larynx and upper part of the trachea are healthy, but the latter on the right side immediately above the bifurcation presents a circular aperture, about a third of an inch in diameter, through which projects a mass of the size of a hazel nut, which till the tube was distended by pieces of glass, reached the opposite wall so that the lumen must have been almost entirely obliterated. The mass in question was found to be the caseous centre of one of the bronchial glands, that portion of it which projects into the trachea being continuous with a smaller portion outside the tube. The mass is not adherent to the walls of the ulcer in the trachea, so that it would require but little force to push it from its present position into the latter. On the same side half an inch above is seen a small gland which has been laid open so as to show a similar caseous centre.

There were two or three small caseous nodules in the lungs, but the organs were otherwise normal. The clinical details which I am able to give of this case are but meagre. The child was admitted suffering from great dyspnœa, which was almost entirely expiratory. It was thought to be suffering from bronchitis. The dyspnœa seems to have ceased somewhat suddenly, so that one may perhaps be warranted in supposing that a suppurating gland, which was causing pressure on, had burst into, the trachea. At any rate the child got well enough to be discharged. A few days afterwards it was brought back again suffering from the same kind of dyspnœa, which proved fatal in a few hours. If the first attack was due to the pressure of an abscess and relieved by the bursting of it, the second was produced by the subsequent projection into the trachea of this core, which was left after the fluid matter was discharged.

A fair number of cases of this kind appear to have been recorded, but the one which bears the greatest resemblance to this is one which Dr. Kidd brought before the Society in 1885. In fact the

Digitized by Google

two cases, except in a few minor details, seem to be nearly identical. At the same time Mr. Poland showed a specimen where both trachea and œsophagus were perforated. Dr. Coupland, Dr. Gee, and Dr. Goodhart have also brought forward similar cases, and lastly Mr. Makins in 1884 showed a case where death resulted from the pressure of a suppurating gland, causing bulging of the tracheal wall. *March 19th*, 1889.

---

5. *Complete rupture of bronchi.*

By A. Marmaduke Sheild, M.B.

The specimen showed a complete rupture of the left bronchus at its junction with the trachea. It was taken from the body of a man, aged 47, who had been violently crushed between a van-pole and a wall, the accident being instantly fatal. The sternum and right true ribs were broken anteriorly, the fractured ends projecting into the mediastinum. The third and fourth ribs on the left side were broken near their angles, and the fractured ends projected into the chest. Much blood was effused into the mediastinal tissue, the pericardium was torn, and the aorta ecchymosed, but the heart and main nerves, with the œsophagus, were intact. The lungs were bruised, not torn. The accident is a rare one, and not alluded to in the text-books. Guthrie, in his extensive relation of chest injuries, does not describe it. The museum of Middlesex Hospital contains a specimen of a similar nature, and at St. George's Hospital is a specimen of rupture of a secondary bronchus. A case of penetrating wound implicating the bronchus is related in vol. x of the 'Transactions' of the Society. *March 19th*, 1889.

---

6. *Syphilitic ulceration of trachea and larger bronchi.*

By G. Gulliver, M.B.

The specimen shows the larynx and trachea taken from the body of a woman, aged 38, who was under my care early in last year. The larynx and upper part of the trachea are seen to be

Digitized by Google

healthy, but the latter at about an inch and a half above the bifurcation shows the commencement of an ulcerative group, which extends throughout the remainder of its length, and also for an inch or more down each bronchus. The ulceration is irregular, and consists for the most part of small elongated, transversely disposed ulcers, which in many cases have laid bare the cartilages of the trachea. In addition it will be seen that, in parts, cicatrisation has taken place, so as to cause narrowing of the tubes, this being most marked just above the point of bifurcation and throughout the left bronchus, which is especially affected. In the fresh state the whole mucous membrane in the parts mentioned showed evidence of excessive inflammation.

Confirmatory evidence of the syphilitic origin of the disease was afforded by the condition of the soft palate, which was extensively cicatrised.

The left lung was the seat of acute pneumonia and pleurisy, whilst the right was healthy.

Clinically, the facts are briefly these. The patient was taken ill three months before admission with cough and dyspnœa, which continued to increase till her admission in April last, and she died forty-eight hours after that. The breathing was obviously stridulous, but as the larynx was healthy no operative interference was thought of, the more so as there was evidence of very general bronchitis and consolidation of the left base. She died after a severe paroxysm of dyspnœa. *March 5th*, 1889.

---

7. *Primary carcinoma of the left bronchus.*

By H. Handford, M.D.

In the early part of last year, I gave a detailed account of two cases of carcinoma of the lung, ('Transactions,' vol. xxxix.) I now add a third. All three occurred in my own practice within twelve months; and, contrary to the usual teaching,[1] in all three

[1] Fagge mentions twenty-six cases of mediastinal new growths involving the

Digitized by Google

the fatal end was brought about by sudden and profuse hæmorrhage. In Cases 2 and 3 the very small bulk of the new growth was a striking feature, and added greatly to the difficulties of diagnosis, from the absence of extensive dulness. In none of the cases was it *absolutely* clear in what organ, whether lung, bronchus, pleura, or lymphatic gland the growth took its origin. There is, however, strong ground for thinking that in Cases 2 and 3, if not also in Case 1, it commenced in the bronchial mucous membrane. It is difficult otherwise to explain how in Case 3 the left bronchus and the trachea became so much involved, there being nowhere much and in most places no growth *outside* the bronchi. It is common for mediastinal new growths to spread along the bronchi or the blood-vessels;

Woodcut 1.

but then they usually extend along the peribronchial or perivascular lymphatics, at the same time involving more or less the wall of the vessel or bronchus. It is also common to find greater or less occlusion of a bronchus from external pressure causing flattening of the tube, and consequent diminution of its calibre, with or without infiltration of its wall. In this instance the phenomena were quite different. Roughly speaking, about one half the bulk of the whole growth was intrabronchial. The occlusion was due to a true stenosis. The calibre of many of the smaller bronchi was completely obliterated, and they were reduced to solid cylinders. There was no pressure from without; no mass of growth round the bronchus; no evidence of the bronchial mucous membrane having been invaded from without. Everything pointed to the growth being a primary carcinoma (scirrhus) originating in the bronchial mucous membrane (hypoblastic epithelium), leading to stenosis of the tube, spreading centrally to the trachea, and peripherally to the smaller bronchi, and to a large extent prevented from extending beyond the walls of the bronchus by the cartilages which, quite uninvolved themselves, formed a barrier to the infiltrating cells.

trachea or bronchi, but says "they do not commonly destroy life suddenly and unexpectedly by hæmorrhage."

Digitized by Google

In places, however, the growth extended between the cartilages into the external connective-tissue sheath.

The difficulty in ascertaining their point of origin has led to the association, under the title of mediastinal new growths, of tumours of very different kinds, pursuing a very different course, and having a very different clinical history.

The true carcinomata situated at the root of the lung seem to be smaller in bulk than the other forms, and to have a greater tendency to perforate vessels and lead to hæmorrhage. They are also generally multiple, and associated with secondary growths, especially in the liver or kidney. Necessarily of hypoblastic origin they usually, if not invariably, commence in the mucous membrane of the bronchi. The sarcomata and lymphadenomata tend to be much more bulky, less frequently lead to hæmorrhage, but produce mischief chiefly by pressure.

Case.—J. S—, aged 64, collier, admitted May 14th, 1888, complaining of cough, shortness of breath, and rapid wasting. He used to drink heavily years ago, and has been short of food the last two or three years. He was strong and in good health till five months ago, when he fell and hurt his chest. He attributes his present illness to the accident, and has had cough and been losing flesh ever since. He has had copious frothy expectoration, occasionally streaked with blood, for some weeks. On admission he was thin and wasted. There was deficient expansion of the left side of the chest, especially at the upper part, with impaired percussion note and very feeble, distant, somewhat tubular breathing, and finally total absence of breath-sounds. At the left base, too, the respiratory murmur was weaker than on the right. He expectorated 10 to 12 oz. of frothy muco-purulent fluid stained with blood. He also had paroxysms of difficulty of breathing, coming on three or four times a day, and lasting a few minutes. There was no difficulty of swallowing, but the voice was hoarse. The diagnosis was a new growth, or an aneurysm, pressing on the left bronchus, and causing collapse of the upper lobe of the left lung. As the vessels at the wrist and temple were extremely atheromatous aneurysm was thought to be the more probable, though there were no other signs of it.

On May 26th he began to cough up frothy blood in small quantities at a time, but for the next three days continued to bring up

Digitized by Google

from 20 to 30 oz. a day. He died of exhaustion on May 30th, after the hæmoptysis had ceased for thirty-six hours.

At the inspection, twenty-two hours *post mortem*, the right lung was found to be voluminous and bulky, and the lower lobe in a state of hypostatic pneumonia. The left lung was very adherent, especially at the upper part. There were numerous small growths, from the size of a shot to a lentil or split pea, on the visceral pleura. The upper lobe was collapsed, and contained many nodules of new growth, white in section, up to the size of a small hazel-nut. The lower lobe only showed one or two white, fibrous-looking bands, spreading along the bronchi, which in some instances were completely obliterated. The mediastinal and bronchial glands were enlarged. The mucous membrane of the trachea was affected by the new growth about three quarters of an inch above the bifurcation. The growth had spread along the left bronchus, nearly filling up its lumen, but without affecting the outside at all. The growth did not extend beyond the cartilages. The bronchus had evidently not been involved from the outside. The right bronchus was unaffected. The source of the hæmorrhage could not be discovered. The liver weighed 70 oz., and contained three or four secondary growths, the largest about half an inch in diameter. There were none in the pancreas, spleen, or kidneys.

Microscopic sections of the left bronchus and of the secondary nodules in the pleura and in the liver, which were exhibited to the Society, left no doubt that the growth was a carcinoma of the scirrhous type. If the commencement of carcinoma exclusively in tissues of epiblastic or hypoblastic origin is accepted, the question of the place of origin of the above growth is much simplified. The epiblast is out of the question. The hypoblastic structures are the epithelial lining of the œsophagus, the epithelial lining of the trachea and bronchi with their mucous glands, and possibly the epithelium of the alveoli of the lung. The œsophagus in this case was totally unaffected. It is unlikely that of the growths in the lung itself one was primary and the others secondary, since they resembled one another so closely. There only remains the epithelial structure of the bronchi.

I have had but little opportunity of looking up the literature of new growths of the bronchi, but must remain satisfied with giving the following references. It is possible that the influence of a preconceived idea of the non-occurrence of primary carcinoma of the

Digitized by Google

bronchi may have influenced the interpretation of many cases of obscure origin.

Biermer quotes a case of infiltration of the bronchial walls by sarcoma in the Würzburg collection. The specimen is described by Virchow ('Verhandlungen d. phys. med. Ges. zu Wurzburg,' Bd. vii, p. 257).

According to Förster, primary cancer of the trachea and bronchi had not been observed.

Rokitansky describes a cancerous formation extending from a bronchial stem to its branches, by which the walls of the bronchi were thickened, rendered rigid, and diminished in their calibre. He considered it, however, to be secondary to carcinoma of the bronchial glands and pleura.

Türck related a case of carcinoma of the trachea, but considered it secondary.

Langhans ("Primärer Krebs der Trachea und Bronchien," 'Virchow's Achiv,' Bd. liii, p. 470) shows that the trachea and bronchi may serve as a point of origin for primary cancer.

February 5th, 1889.

The specimen was referred to the Morbid Growths Committee, who reported as follows:

Report on Dr. Handford's specimen of carcinoma of the left bronchus and root of the lung.—We have examined the specimen and mounted sections submitted to us.

The sections show very well a carcinomatous growth of the mucous membrane of the bronchus continuous with similar growth outside, which is much less in amount, and embedded in peribronchial connective-tissue growth.

The specimen shows a considerable amount of fibrous thickening of the connective tissue outside the trachea and affected bronchus, in which some enlarged glands are embedded and fixed to the air passages; and the growth in the trachea and bronchus is not ulcerated, and its appearance macroscopically is not unlike that of a growth which has invaded the air passages from the œsophagus.

But from the typically carcinomatous type of the growth, from the absence of any lesion of the œsophagus, and from the fact that the peribronchial thickening, as shown in the sections, is chiefly a connective-tissue hyperplasia with comparatively little epithelial

Digitized by Google

growth, we agree with the author in regarding the disease as having most probably arisen as a primary lesion of the mucous membrane of the trachea or bronchus.

FREDERICK TAYLOR,
February 29th, 1889. F. CHARLEWOOD TURNER.

---

8. *Embolism of pulmonary artery.* (*Card specimen.*)

By RAYMOND JOHNSON, M.B., B.S., for M. BERKELEY HILL, M.B.

THE specimen consists of the heart and lungs. The arch of the aorta has been divided and the pulmonary artery laid open. The latter contains a firm clot between six and seven inches in length, lying coiled up at the bifurcation and projecting into both branches. The clot in the recent state was firm and pale, whilst projecting from it into the smaller branches was black *post-mortem* clot.

The internal saphenous vein, with part of the femoral and external iliac veins, are also shown. The saphenous, as high as its entry into the femoral, is completely filled with firm adherent clot, which projects for about one inch into the femoral, where it ends in a broken-off looking extremity.

Above this point the femoral and iliac veins contain no coagulum, except here and there small adherent patches. The clot in the pulmonary artery came almost certainly from this situation.

The lungs contained excess of frothy serum.

The specimen is from a female aged 54. She had suffered from varicose veins in the right leg for many years, with several attacks of phlebitis. After the last attack a red, tender swelling remained at the inner side of the knee. This was incised, but only a little softened clot and no pus escaped. Nineteen hours later, whilst turning in bed, she was seized with sudden pain in the chest and urgent dyspnœa. The dyspnœa continued with varying intensity, and she died nine and a half hours later.

December 4th, 1888.

Digitized by Google

9. *Lymphosarcoma of left lung.* (*Card specimen.*)

By Arthur Davies, M.B.

The left lung taken from a lad, aged 18, who came under observation on December 30th, 1887, at the Royal Chest Hospital, with cough of nine months' duration, night sweats and loss of weight. For a fortnight previously he had complained of acute pain in the left side, increased by inspiration, inability to lie on that side, and dyspnœa. The expectoration had been frequently accompanied with blood, and this symptom on and off continued till March, 1888. In December, 1887, he noticed pain in the right groin, which radiated into the testicle and down the right leg, and which ultimately prevented him from walking. There had been no hæmaturia, nor was micturation more frequent than normal. There was a previous history of pleurisy in the left side in March, 1886. The physical signs appeared to be those of commencing phthisis, with rapid consolidation and excavation at the left apex, where a large vomica was formed. This disappeared in the course of three weeks, and was replaced by absolute dulness and loss of breath-sounds. The heart was pushed over to the right side of chest, and in the right groin a large new formation sprang up. Similar new growth was eventually formed above the left clavicle. Death took place on June 20th.

Post-mortem examination.—Body greatly emaciated. Above the left clavicle was a mass the size of an orange. In the right groin was a large mass above Poupart's ligament, filling up the hollow of the ilium and extending to the middle line. Below Poupart's ligament were three or four nodular masses. On opening the *left* side of the chest the pleural cavity was obliterated, and the whole side of chest filled by a hard mass of new growth, scarcely any lung-substance being visible. The growth had extended downwards through the diaphragm into the abdominal cavity, where it projected as an irregular nodular mass. The left lung cut with difficulty, and presented a mottled appearance and yellow colour; the growth was most distinct along the pleural cavity. Microscopic sections showed the growth to be one of round-celled lymphosarcoma, which completely filled up the alveoli.

Right lung: No new growth.

Digitized by Google

Liver: Few nodules of new growth in left lobe.

In the centre of the abdominal cavity over the spine and eroding one vertebra for about eighteen inches, was a mass the size of the fist, pushing forwards and involving the pancreas.

Springing from the right iliac bone was an irregular nodulated mass of new growth, which was continuous with the masses above and below Poupart's ligament. All the growths consisted of an abundance of round-cells. *May* 21st, 1889.

---

10. *Lymphosarcoma of the mediastinum involving the large blood-vessels.* (*Card specimen.*)

By Robert Maguire, M.D.

A female was admitted into St. Mary's Hospital suffering from left pleural effusion, with dulness across the upper part of the sternum, and dilatation of the superficial veins of the right side of the thorax and neck, and of the whole of the abdomen. Two enlarged glands made their appearance at a later stage in the right side of the neck. The patient died with symptoms of asphyxia.

A large mediastinal growth was found surrounding and involving the wall of the large vessels, especially the veins. The endothelium of the vessels was intact. The left innominate vein was occupied by a fairly firm clot. *November 6th*, 1888.

---

11. *Two cases of mediastinal growth involving the pericardium and heart.*

By Frederick W. Mott, M.D.

I. *Malignant Growth of Anterior Mediastinum, involving the Pericardium and Heart, with obliteration of the left innominate vein.*

E. K,—unmarried, female, aged 21, was admitted to Charing Cross Hospital under Dr. Green, June 28th, 1888, and afterwards was under the care of Dr. Lubbock. There was nothing

Digitized by Google

noteworthy in the family history, and the patient stated that up till September, 1887, she had always been in good health. She was then laid up for three weeks with an attack of rheumatic fever. She recovered from this, though not completely, as for some time afterwards she suffered from weakness and pains in the knees. About the beginning of May she noticed that her breathing was laboured and there was a sense of oppression under the left breast. About the end of May she suffered from shortness of breath and a hacking cough. She never spat any blood, nor had she lost weight. In June, as her breathing became worse, she consulted Dr. Green at Brompton, and he sent her for admission to Charing Cross Hospital.

Condition on admission.—Patient looks a well-nourished girl; she is lying in bed on her left side, cheeks flushed and considerable dyspnœa, the breathing being hurried and laboured, and the alæ nasi working. The lips are somewhat livid; the veins of the neck are not distended; respirations 30; pulse 120; temperature 98°. The left side of the chest is large and does not move. The apex-beat of the heart is two and a half inches to the left of the nipple; there is some dulness and resistance over the upper part of the sternum, and there is a complete absence of resonance and increased resistance over the entire left side of the chest, both back and front, extending above the clavicle even. There is absence of vocal fremitus and breath-sounds over the entire left chest.

The heart-sounds are normal, the urine contains a large amount of urates, and is scanty, dark in colour, and of high specific gravity—no albumen.

Two days after admission the patient was tapped, 50 oz. of clear serous fluid being removed from the left pleural cavity. Within a week it was necessary to repeat the operation, and three days later paracentesis was again resorted to.

July 12th.—A new symptom developed, slight œdema of both legs and feet, and also œdema of the left arm and hand. This gave her some discomfort, and the arm was raised in a sling, with the result that the œdema of the arm disappeared in a few days.

During the next fortnight paracentesis was performed three times, from 60 to 90 oz. of clear serous fluid being withdrawn on each occasion. After each of these operations only a slight amount

Digitized by Google

of resonance was noticed in the upper part of the front of the left chest.

During all this time the temperature was either normal or subnormal, except on one occasion, when it reached 100°.

Early in August patient seemed to be improving a little, the œdema of the legs had disappeared, the breathing was not so difficult, and the diarrhœa she had suffered with had ceased. On August 14th, however, patient became worse, the œdema of the legs and the left arm returned in an aggravated form, the left hand and arm not only being affected, but the left side of the chest. A few days later symptoms appeared which suggested pericardial effusion. The heart's apex-beat could not be felt; there was dulness over the whole of the sternum; the pulse was feebler and had increased in frequency to 160. There was considerable cyanosis and dyspnœa. On auscultation the heart-sounds were distant, weak, and toneless; the veins in the left side of the neck were distended, also those of the left arm.

August 21st.—The cough became very troublesome, sputum streaked with bright blood; pulse 140; temperature 101°; wandering delirium. She continued much in this condition for a week, and died on August 29th.

Previous to death the pulse could not be counted; the pupils were never affected, both being equal and reacting to light until a short time before death. There was never any stridor, although there was considerable dyspnœa, nor was the voice affected beyond its being weak.

The symptoms presented by this case were very puzzling. There was a history of rheumatic fever, and following this, thoracic trouble, commencing with pain between the left breast and difficulty of breathing. Until the œdema of left arm and hand there were no definite symptoms pointing to malignant growth of the mediastinum; and this, disappearing as it did upon raising the arm, was rather against obstruction of the vein by a growth.

Certainly the absence of pyrexia with such severe effusion limited to the left pleural cavity, together with the unusual dulness in the upper part of the left chest and behind the upper part of the sternum, suggested a mediastinal growth invading the left lung; but against this we have the important fact that the fluid which was removed from the left pleura was a clear serous effusion and not blood-stained, as is the case when the lung is invaded by new

Digitized by Google

growth. She had not ever spat any blood (till within a few days of death), which is a frequent symptom of this condition. Again, her whole illness seemed to date from an attack of rheumatic fever. The diagnosis, then, lay between malignant growth and a subacute pleuro-pericarditis with thickened pleura, although the former seems much the more probable. The dulness over sternum was not complete owing to compensatory hypertrophy of the right lung.

Conditions found at the autopsy explained the very remarkable symptoms exhibited during life.

Upon opening the chest the sternum was found fixed by two pedicles of growth of the size of a shilling. On removing the sternum, a hard white cartilaginous mass was found occupying the superior mediastinum and surrounding the great vessels. The growth had produced erosion of the sternum, so that the bone had become partially absorbed. The left pleural cavity contained three pints of slightly stained serous fluid. The pericardium was greatly distended, and extended fully four inches to the right of the middle line. It contained nearly 30 oz. dark stained serous fluid. After opening the pericardium and removing the fluid the appearance presented was remarkable. The surface of the heart and the pericardium were covered with rounded irregular white patches of new growth, to all appearances as if candle-wax had been melted and dropped unequally on the surface of the organ. The right ventricle was adherent by a large mass to the pericardium, and the great vessels were embedded in and totally obscured by the growth. After dissection it was found that the large arteries, although surrounded by the growth, had not their coats involved to such an extent as to obliterate in any way their lumen. The veins, with their thinner walls were, however, considerably involved, particularly the left innominate, which passed right through the centre of the growth.

Microscopical sections of this vein showed that the growth which infiltrated the walls by means of the lymphatics and lymph-spaces had led to thrombosis of the vessel. It is difficult to say whether the thrombus had been involved by the growth or not. The blocking up of the left innominate extended up to the subclavian and internal jugular veins. It is remarkable that the vagi, recurrent laryngeal and cardiac branches of the sympathetic, which must have been involved in the growth, yet were not sufficiently injured to

Digitized by Google

give rise to symptoms during life. This, however, can be explained when we examine the condition of the muscle-substance of the heart. The growth in this organ has infiltrated from without, inwards, the lymphatics of the organ, and around each fibre are numbers of small round-cells; but the fibres themselves show a striation, and the organ presented when cut into a fairly red appearance where it was not involved much by the growth. The cardiac failure which supervened so suddenly in the disease was in all probability connected with the pericarditis and very extensive effusion. The growth affected the lungs only very slightly; the left lung was adherent in two places, but the adhesions were inflammatory. The bronchial glands and the glands of the posterior mediastinum were unaffected to any extent, and this accounts for the remarkable freedom from new growth presented by the lungs. The bronchi were not affected so as to diminish in any way their lumen. The growth surrounded the pulmonary vein, but had not infiltrated the walls. The disease microscopically proved to be a lymphosarcoma, which originated either in the remains of the thymus or cardiac lymphatic glands of the superior part of the anterior mediastinum, and involved those structures whose lymphatics are connected with those glands, namely, the pericardium and heart. I should think it probably commenced in the remains of the thymus for the following reason,—the evidence of bilateral origin, viz. the existence of two brownish-red pedicles, which were connected with the mass of the growth posteriorly and anteriorly with the sternum. The pedicles were quite symmetrical, and of the size of a shilling.

II. *Case of Mediastinal Tumour invading Pericardium, left Lung, and Secondary Growths in other organs.*

E. B—, carpenter's labourer, aged 45, was admitted February 6th, 1888, into Charing Cross Hospital for pain in the pre cordial region, vomiting, and weakness. There was nothing noteworthy in the family history. He had always had good health till the previous September, when he first noticed pain over the heart, which after a few weeks intensified so that he was unable to follow his occupation. He had always suffered with some shortness of breath, and during the last few months he has lost flesh considerably.

Condition on admission.—Patient is emaciated, and has an anxious

Digitized by Google

expression. The skin is in loose folds, and the veins over the abdomen are more prominent than usual. The pupils are equal, and react to light and accommodation. He does not suffer from any constant pain. He suffers with frequent cough, but has never expectorated any blood.

Examination of the chest.—The sternum and costal cartilages are very prominent, and there is evident flattening under the left clavicle. The intercostal spaces are well marked on the right but not on the left side, and there is a marked precordial bulging of the chest. The right chest appears much fuller than the left, and the latter scarcely expands at all. Vocal fremitus is much diminished all over the left lung, and entirely absent over its base. The left half of the chest is absolutely dull; this absolute dulness is, however, limited to the left of the mid-sternal line. There is, however, increased resistance, and a slight dulness extending for an inch and a half over the right chest in the first and second intercostal spaces. Otherwise there exists hyper-resonance over the right lung. The breath-sounds are inaudible over the left lung, except in the second space and above the clavicle, where bronchial breathing is heard during inspiration and expiration. There are no râles of any kind. Vocal resonance is greatly diminished all over the left lung. Over the right lung loud harsh breath-sounds with sonorous rhonchi heard everywhere. The heart's apex is at the nipple, and there is nothing exceptional about the heart-sounds. The temperature was about 99°, and remained so for a few days.

February 15th.—It went above 100°; an exploratory puncture was made into the left chest, and some pus was obtained.

21st.—Temperature for some days had been 101°.

23rd.—The patient was operated upon by Mr. Barwell. He excised a portion of the tenth rib; no pus was obtained, but a purulent discharge was noticed daily in the dressings. The wound continued to discharge, but patient was not relieved in his breathing, and lost strength and flesh daily. Suffered from flatulence, and lost all appetite. The emaciation progressed rapidly; for the last few days of his life he was fed by nutrient enemata, as he could not take food, and he died March 17th.

Autopsy thirty-eight hours after death.—On removing the sternum the right lung much distended; projecting from the left lung there were several large irregular nodules of growth.

Digitized by Google

The pericardium contained 28 oz. of blood-stained serum; the upper part of the cavity was invaded by the growth and the left auricle completely surrounded. Heart cavities normal, except left auricle, which is much compressed by the growth, and the growth has commenced to infiltrate the wall at its upper part.

A large hard white mass was found at the root of the lung quite six inches in diameter. The growth had not invaded the right lung, but the left was infiltrated with the growth, particularly at its lower part. The left lung was found adherent everywhere, and was with difficulty removed. On section it was found to be solid, and nowhere was crepitation obtained. The whole of the lower lobe had broken down into small anfractuous cavities intercommunicating and discharging, on squeezing, a purulent fluid.

Secondary deposits were found in the pancreas, kidneys, and spleen.

This case is of interest because, owing to the house physician having obtained pus on the introduction of a needle associated with some pyrexia, empyema was considered probable, and an operation resorted to.

The condition of the lung at the autopsy explained why pus had been obtained on the introduction of the needle, why there was a rise of temperature, and why no pus was obtained at the operation, although there was a constant purulent discharge on the dressings. The breaking down of the lung, with the formation of cavities, explained the pyrexia; air did not enter the lung, and so it could not be ascertained by auscultation. The needle had entered a cavity and withdrawn the contents. Empyema on this evidence was diagnosed, and an operation performed with the result mentioned. The airless base of the lung, as it broke down, afforded the purulent discharge found on the dressings.

The operation had no injurious effect as far as I could determine.

In vol. xvi of the 'Pathological Society's Transactions' Dr. Peacock brought forward two cases of malignant growth involving the heart, and cited forty-four cases which he had collected; of these twenty-two were of metastatic origin.

Somewhat similar cases to both of those which I have related have been recorded in the Society's 'Transactions' previously.

In vol. xix Dr. Ogle reported a case, under the care of Sir Thomas Watson, occurring in a young woman aged 22, which was strikingly similar in the history, clinical symptoms, and pathological conditions,

Digitized by Google

th e case having been regarded as one of tubercular phthisis. In the same volume Sir J. Risdon Bennett reported a case of intra-thoracic growth involving the left lung, and converting it into a s eries of abscesses.

Orth. ('Lehrbuch der Spec. Pathologie Anatomie,' p. 201) states that the malignant lymphomata may appear secondarily in the heart, partly by direct infiltration from the bronchial or mediastinal glands or from the thymus, or it may be by a true metastatic deposit. *November 6th*, 1888.

---

12. *Mediastinal sarcoma in an infant aged* 15 *months.*

By Angel Money, M.D.

Gertrude F—, aged 15 months, was admitted into the Hospital for Sick Children, under my care, on August 16th, 1888, with the following history:—She had wasted when about six months old. At twelve months she acquired a cough, and a doctor said she had bronchitis, which lasted two or three weeks. After recovering for a while she grew worse again, lost flesh quickly, and had no appetite. Cough was not severe, and only occurred twice or three times a day. Vomiting after taking new milk; sweating, especially about the head; restlessness, crying out when lifted by taking hold of the lower part of the chest; absence of feverishness; regular bowels—were the other symptoms elicited from the mother. The patient had been really ill for about a week. There was nothing of note in the previous or family history.

On admission it was noticed that the child was very dusky in the face, the breathing was laboured, and the extremities cold and blue. The respirations 48; pulse 144, soft and regular. An ineffectual short cough also occurred frequently, and there was expiratory respiration, the commencement of the expiration causing a panting sound.

The thorax was rickety; lateral grooving and prominent sternum; beaded ribs. The epigastrium, lower sides of chest, especially the left, receded during inspiration.

The percussion-note was resonant all over the left lung but dull

Digitized by Google

over the lower half of the right side, in front, behind, and in the side. The breath-sounds were well heard over the left back with numerous mucous râles. In the right lung the breath-sounds were feeble above and almost absent below the angle of the scapula. In the upper half of the right axilla there was bronchial breathing.

The heart's apex-beat was felt in the fourth interspace just inside the nipple line. The liver extended three fingers' breadth below the ribs.

The head was large and square; the fontanelle measured three fingers' breadth across. The wrists and ankles were slightly enlarged.

August 18th.—The patient was first seen by Dr. Money. A needle was introduced into about the eighth space behind, but nothing was withdrawn, and it was remarked that the substance into which the needle was pushed appeared solid.

The lips, nose, and ears were blue tinted; the breathing was 80; the pulse 164, weak and small; the temperature only 100·2°.

On admission the temperature was normal; on August 17th 99·2° in the morning, 100° in the evening. The bowels acted three times on the 16th, five times on the 17th. Mustard baths and cold douches to the head appeared to afford some relief from the dyspnœa. The baby died on August 19th.

The necropsy was made forty-eight hours after death. The body weighed nearly 12 lbs.

On opening the thorax the lungs were seen to be greatly condensed and the heart much pushed forwards, so as to throw the lungs apart; the pericardium was distended with clear fluid.

On removing the larynx, lungs, and heart *en masse* a tumour was discovered extending down to the diaphragm and up to the fifth dorsal vertebra. It was somewhat apple-shaped, and extended much more to the right side of the middle line; the aorta and vena cava and vena azygos major were raised on to its front surface; the tumour occupied about one fourth of the thoracic cavity. The liver was displaced downwards, so as to extend three to four fingers' breadth below the costal margin. The tumour measured two and a half inches from above downwards, three inches from side to side. At least three fourths of the tumour projected into the right side. The tumour was quite separate from the diaphragm, and section of it proved that it did not grow from the bony vertebræ, nor from the periosteum, for it could be easily separated from these

Digitized by Google

structures, which were quite smooth and shiny beneath the tumour; the vertebræ were not eroded.

The right lower lobe of the lung was extremely collapsed, and only about the size of the middle lobe. The back part of the right upper lobe was collapsed. The left lung was larger than the right lung, but it had an area of collapse on the back part corresponding to the part pressed upon by the tumour. The most collapsed parts of both lungs were those in contact with the tumour, but many small patches of collapse were noted elsewhere.

There was mucus but no blood in the bronchial tubes. The right side of the heart was much distended, and contained a dark soft clot.

The liver was congested, the stomach dilated, the kidneys and adrenals normal.

No sign of a secondary nodule was found anywhere. The brain and calvaria were natural. The tumour was a round-celled sarcoma; no muscular tissue was found in it.

There can be no doubt that the child's death was chiefly due to the interference with respiration caused by this large tumour. During life the case excited some interest, because the dulness appeared to be so "flat," and suggested something more than mere collapse; moreover, the breath-sounds were abolished over the area of dulness; indeed, silence prevailed over this region, nothing of bronchophony or bronchial breathing being heard except in the outlying parts of the dulness. The exploring needle yielded no fluid, and when in position seemed to be held fast in solid tissue. It does not seem possible that the tumour could have been removed during life. *November 6th*, 1888.

Digitized by Google

III. DISEASES, ETC., OF THE ORGANS OF CIRCULATION.

1. *Fatty heart, from a case of chronic alcoholism.* (*Card specimen.*)

By Frederick Walker Mott, M.D.

R. W—, male, aged 36, admitted into Charing Cross Hospital, being brought in a state of unconsciousness by the police. His friends said he was a carpenter by trade, and had been a very heavy drinker. He was quite unconscious and greatly collapsed. The pulse at the wrist could not be felt, and the heart-sounds could hardly be heard. The breath smelt strongly of alcohol. Dr. Bruce, under whose care the patient was, ordered brandy and ether to be injected hypodermically, hot bottles to his feet, and other restoratives. In the evening, four hours after admission, he regained consciousness, but the pulse could not be felt. At 8 p.m. he suddenly fell back dead from fatal syncope. At the autopsy there was found extensive fatty degeneration of the heart affecting particularly the musculi papillares of the left ventricle. The coronaries were not stenosed, and there was no atheroma of the aorta. The liver was enlarged, fatty, and cirrhotic. Microscopical examination showed most extensive fatty degeneration of the muscle-substance. Dr. Sharkey has suggested that possibly this was due to changes in the nerves. I have examined sections of the cardiac nerves from this case, and certainly there are an excess of leucocytes around and between the nerve-fibrillæ, but I think it is hardly definite enough to claim any reliable association between the two conditions, although *a priori* it is a most rational explanation. *April 16th*, 1889.

Digitized by Google

2. *Unusual form of rupture of the heart.* (*Card specimen.*)

By W. H. White, M.D.

The heart of a man, aged 45, who had been under observation for nine months at the Royal Hospital for Diseases of the Chest, for aneurysm, and who died suddenly on going upstairs with symptoms of internal hæmorrhage.

On opening the pericardium, which was greatly distended, about 20 oz. of blood and clot were found in its cavity. Subsequent examination of the heart showed a small rupture capable of taking a No. 2 catheter, situated in the wall of the left ventricle, an inch and an eighth below the auriculo-ventricular groove, and five eighths of an inch from the interventricular groove. On passing a director through the rupture the opening was found to lead obliquely upwards, backwards, and to the right along a narrow channel into the right ventricle immediately below the pulmonary valves, the heart-substance being very degenerate in this part.

The aorta itself was in a condition of advanced atheroma, whilst the conus arteriosus was distended on the right side into a large unilocular aneurysm with very thick walls, due in part to organised clot.

The aneurysm had encroached considerably upon the lumen of the pulmonary artery.

The heart is preserved in the museum of St. Bartholomew's Hospital, Series vii, No. 1368 (*a*). *March 5th*, 1889.

---

3. *Mitral stenosis. Enlarged auricle compressing left bronchus.*

By H. H. Taylor, M.D.

Patient, male, aged 16 years. No previous illness, no history of rheumatism; shortness of breath three years; palpitation and cough; slight hæmoptysis at times.

Physical signs.—Marked precordial bulging, cardiac impulse

Digitized by Google

diffused and heaving. Dulness commenced at second rib and sloped obliquely downwards to axilla and base of left lung. Well-marked presystolic thrill. Presystolic and systolic apex murmurs.

Liver enlarged and pulsatile; some dropsy; urine albuminous.

Post-mortem.—On removing the sternum the right lung is seen to be adherent to the right costal cartilages and pericardium. The upper part of the left lung only is seen. The pericardium occupies the greater part of the left side. It contains about one pint and a half of amber-coloured fluid. The lung is pushed upwards and towards the spine, so that the pericardium is in contact with the lower and posterior walls, and also the lateral and lower anterior aspects.

Abdominal cavity contains a quantity of straw-coloured fluid acid in reaction.

Heart considerably enlarged. Tricuspid valve admits five fingers. Mitral valve slit-like and just admits one finger. Its margin is thickened and rigid. There are a few tough granulations on the ventricular surface of the flaps. Chordæ tendineæ and muscular papillæ thickened. The left auricle is enormously distended, containing 11 oz. of dark clot, the wall being nearly one quarter inch in thickness, the appendix also dilated and thickened. The cavities generally are dilated, and muscular walls equally hypertrophied.

Aortic valves are competent; segments rather thickened, and some tough granulations on the corpora orantii. Aorta perhaps rather small.

The left auricle extends upwards to a point just below the bifurcation of the trachea.

The left bronchus passes behind and in close contact with the left auricle, and is flattened from before backwards in its whole length. The right auricle also comes into relation with the left auricle, but is not compressed by it.

Subtracheal glands slightly enlarged and pigmented.

Right lung œdematous; shows brown induration. Left lung, upper lobe retracted; also shows brown induration. Lower lobe completely collapsed; upper two thirds almost airless; lower two thirds choked with coagulated blood. *May 7th*, 1889.

Digitized by Google

4. *Stenosis of mitral and tricuspid valves.* (*Card specimen.*)

By R. G. Hebb, M.D.

A. V—, female, was admitted into Westminster Hospital under Dr. Sturges, December 3rd, 1884, at the age of 18, for disease of the heart. Had suffered from attacks of palpitation and dyspnœa when 9, 14, 16, and 18 years of age. At the last attack had general pains but no joint (or other) swellings. *Had never had any acute disorder.* There was no family history of rheumatism. At the beginning of 1886 was seized with left hemiplegia, in consequence of which the left extremities became rigid and wasted. The cardiac dulness was large, the heart's action irregular, and there were a presystolic thrill and murmur. While in hospital was subject from time to time to attacks of faintness and dyspnœa, and which were at last fatal. Died, aged 23, February 1st, 1889.

Post-mortem examination.—Anasarca, hydrothorax, hydropericardium, ascites. Brain 40 oz. Both right ascending convolutions in their lower halves and the posterior parts of the first and second frontals are in the condition of yellow softening. The marginal convolution in front of the central fissure is in a similar condition as is also the cerebral tissue lying between these internal and external planes. The degeneration reaches downwards as far as the wall of the right lateral ventricle, and involves the posterior two thirds of the caudate nucleus. Bronchitis and hæmorrhagic infarcts in lungs. Heart 13½ oz. The cusps of mitral and tricuspid valves are thickened and adherent, so that the apertures of these valves are stenosed. Both auricles are much enlarged, and their walls hypertrophied. The valvular endocardium is quite smooth, but there is some recent inflammation of that of the left auricle. The left appendix is blocked with firm, adherent, and almost laminated clot. The rest of the viscera are not noteworthy.

April 2nd, 1889.

Digitized by Google

5. *Atheromatous disease of aorta and arteries of lower limbs.* (*Card specimen.*)

By Raymond Johnson (for Mr. Heath).

C. P—, male, aged 56, was admitted to University College Hospital, under the care of Mr. Heath, on December 3rd, 1888. There was a history of *syphilis*.

The right leg had been amputated in the upper third for gangrene of the foot in December, 1887. On admission in December, 1888, the second, fourth, and fifth toes of the left foot were in a condition of dry gangrene. A very feeble pulse could be felt in the femoral artery at the groin, but none in the popliteal or tibials. The foot was amputated through the metatarsus. The flaps became gangrenous, and the patient died with high fever (101° to 103·8°) on the ninth day.

The specimen consists of the aorta and the large vessels of the lower extremities. The inner surface of the aorta presents large irregular raised patches, yellow in colour, and many of them soft in consistence. The surface of the smaller ones is soft, but the larger patches are roughened and have firm clot adherent to them. The disease is very marked around the origin of the branches. Above the bifurcation is a large calcareous plate, with some loosely adherent clot.

The right common iliac artery contains a thick calcareous plate over an inch in length. The external iliac and femoral arteries are almost completely obliterated by partly decolourised clot. The profunda is still pervious. The popliteal artery (which ended in the stump) is impervious, being blocked by the thickened inner cord, and firm decolourised clot.

In the left external iliac arteries the swollen inner coat is separating in a large flake. In the popliteal artery the inner coat can be easily separated, and the lumen is obliterated by firm coagulum.

The smaller vessels, tibials and peroneal, are solid cords. A section shows the final obliteration of the lumen to be due to firm decolourised clot. Examined microscopically, there is seen to be great thickening of the intima, and complete filling of the lumen with organised clot. The vessels of the upper limbs were only

Digitized by Google

slightly diseased. The liver was fatty, and the kidneys in a condition of early cirrhosis. There was considerable thickening of the aortic valves.

In comparing the condition of the larger with that of the smaller arteries it is noticeable that in the latter the overgrowth of the inner coat is much more uniform, and does not show the same tendency to degeneration. *January 29th*, 1889.

---

6. *Aortic aneurysm which burst into the œsophagus.* (*Card specimen.*)

By Frank Penrose, M.D.

The specimen was taken from the body of a man aged 37, who was found in Hyde Park, sitting on a bench with a pool of blood in front of him. He was brought to St. George's Hospital, and died soon after admission.

The specimen is a good example of a combined fusiform and sacculated aneurysm. *March 19th*, 1889.

---

7. *Case of aneurysm at the junction of the transverse and descending portion of the arch of the aorta which ruptured into the pericardium. Death in fifty-six hours.*

By S. Herbert Habershon, M.D.

This specimen is from a man aged 34, who was the subject of aortic aneurysm. As the case is of some interest owing to its unusual termination, I have thought it worthy of record.

Previously a soldier, the patient had been engaged as a porter for several years before his illness.

There was no history of syphilis, rheumatic fever, or intemperance, and his only acute illness was malarial fever in South Africa six years ago.

Digitized by Google

In December, 1886, and again in June and July, 1887, he had suffered from severe attacks of vomiting, and also continuously for eighteen months from dyspnœa.

In July, 1887, he was admitted to St. Bartholomew's Hospital under Sir Dyce Duckworth's care, who has kindly allowed me to refer to his notes. The condition at that time was as follows:—A pulsating swelling of the size of half a walnut presented in the second left intercostal space. A systolic bruit could be heard over it and at mid-sternum. The aortic second sound was accentuated. The cardiac impulse diffused, and apex-beat situated in the fifth interspace just within the nipple line. There was no inequality of pupils or pulses, no dysphagia and no laryngeal trouble.

The most urgent symptoms on admission were pain in the seat of the tumour and dyspnœa. Under his treatment of low diet and increasing doses of iodide of potassium (up to 30 grains three times a day) the pain disappeared, the pulsation diminished, and he was discharged on October 12th, 1887.

Subsequently, on May 7th, 1888, the patient applied to me at the Marylebone Dispensary, Welbeck Street, complaining of pain in the left side of the chest, cough and hoarseness, which had commenced a week previously. He suffered slightly from dyspnœa and palpitation. All other signs of aneurysm were absent except the presence of a small pulsating swelling in the second intercostal space, not prominent, with dulness over it extending one inch and a half to the left of the sternal border, and over the second and third costal cartilages. Other physical signs did not differ from those observed in St. Bartholomew's Hospital, except that there was no definite systolic bruit. Breath-sounds were normal.

There was no sign of paralysis of the vocal cords, but both were brightly injected as by acute laryngeal catarrh.

The patient was aware of the serious nature of his malady, but in spite of warning he continued his work, and on the following day, May 8th, was seized at 7 p.m., while sweeping out a room, with sudden faintness and pain in the left chest. He was carried to his home, and I saw him at 8 p.m. He was then in a state of collapse. The face blanched but no lividity. The skin cold and clammy, and extremities cold. Pulse imperceptible at the wrist, and no pulsation to be detected by the hand either over aneurysm or heart. The heart-sounds were feebly audible by the stetho-

Digitized by Google

scope. There was no increase of precordial dulness, nor any sign of effusion into either pleural cavity. He was quite sensible and did not appear to be in pain.

On the following morning his friends told me that he was better, and I visited him at 10 a m. He was less pale, the pulse was perceptible, small, soft, but regular, and with 120 beats to the minute. Temperature 101°. Cardiac dulness not increased, pulsations still not felt. No bruit or pericardial friction to be detected, and no sign of effusion. There was more cough and pain in the chest, the latter only with the cough.

He was still living on the 10th, but since the previous night the cough had become more paroxysmal and accompanied with intense pain. When I saw him in the afternoon he had two attacks of this spasmodic cough, and the pain was then so severe that he would jump forward in the bed to a sitting posture, and struggle for breath. Respiration during his quiet moments was hurried. There was no lividity. The pulse was still regular and soft, and of the same rapidity. Temperature 99·6°. Precordial dulness had now increased in all directions,—to the left as far as one inch outside the left nipple line, to mid-sternum on the right, and above merging with the aneurysmal dulness. The heart-sounds very feebly audible. No pericardial friction. At both bases of the lungs resonance was impaired, but more at the right than at the left side. Breathing feeble and bronchial, but no râles to be heard.

His breathing became more difficult, and he died at 3 a.m. on the morning of the 11th, fifty-six hours after the onset of collapse.

Post-mortem.—On opening the chest I found the pericardium enormously distended with dark fluid blood (about a pint and a half), no whipping or frothing of the blood or general clotting.

The surface of the pericardium showed no sign of lymph or flaky deposit.

The heart and large vessels were removed entire.

The specimen presents a fusiform aneurysm of the aorta, with two large saccules. One, the larger, at the junction of the ascending and transverse portion of the arch, involves the region of the root of the innominate and left carotid arteries. It is coated with a thick layer of indistinctly laminated clot (partially detached in opening the vessel) from a quarter to half an inch in

Digitized by Google

thickness. The layer of clot terminates at the opening of the innominate artery. The other saccule is smaller, and occurs at the junction of the transverse and descending parts of the arch. It presents the appearance of a deep ulcerated cavity, one and a half inches across the mouth and an inch in depth, with ragged surface and no deposit of fibrinous clot. The wall of the vessel in the neighbourhood of the saccule is as much as three quarters of an inch in the thickest part, the innermost layer being of almost cartilaginous hardness, and the outer consisting of dense fibrous tissue. Through this thickened wall the ulceration from the saccule has extended in a downward and forward direction, immediately overlying the left bronchus and opening into the pericardial cavity, anterior to the pulmonary artery at the point where the pericardium is reflected over it (a black glass rod has been passed through it). The perforation is large enough to admit the tip of the little finger. Round the opening, for the distance of about an inch, is a thin layer of decolourised fibrin adherent to the pericardium. The wall of the aorta in its ascending and transverse portions is generally thickened and the internal surface is irregular and atheromatous. The valves of the heart are healthy and competent. There is no marked hypertrophy of its muscular walls. The lungs were deeply congested at both bases.

Remarks.—This case presents several points of interest. According to the published accounts, rupture into the pericardium is the most uncommon of all the terminations to which an aneurysm of the descending part of the arch is liable.

In the 'Transactions' of this Society only two cases of extra-pericardial rupture are recorded, and these occurred in the ascending part of the arch immediately above the valves (Dr. Irvine, vol. xxviii, p. 73, and Dr. William Ewart, vol. xxxi, p. 82). Mr. Wagstaffe, in vol. xxix, gives an abstract of twenty-five cases of aneurysms bursting into the pericardium. In all cases but one rupture occurred in the vicinity of the aortic valves,—in one case from the lower part of the arch, beneath the innominate artery.

Sir Dyce Duckworth has kindly sent me the report of a case (published by him in the 'Edinburgh Medical Journal' for 1869) of aneurysm of the descending aorta rupturing into the pericardium and left bronchus. In this case also the patient lived for three days after the symptoms commenced.

In commenting upon the rarity of it he quotes Dr. Sibson's

Digitized by Google

statistics,[1] to the effect that "sacculated aneurysms of this part of the aorta rupture in 75 per cent. of the published cases. In 26 per cent. of these they burst into the left pleura, in 18 per cent. into the right pleura; into the trachea in 4 per cent.; the left bronchus in 16·5 per cent.; and in only 2 per cent. do they burst into the pericardium."

A further point of interest is in the clinical history, which evidently points to a gradual leaking from the aneurysm. It is not often that opportunity is afforded of observing effusion of blood thus slowly accumulating in the pericardium. In the few cases in which it has been recorded the temperature was higher than in the present case. In a case of Mr. Irvine's (vol. xxviii, 'Path. Trans.,' p. 68) it rose to 104° a few hours before death. In all but four of the reported examples that I have found death was sudden. These, however, are matters rather of clinical than of pathological interest. In the specimen itself the twofold efforts at repair are well shown by the thick deposit of fibrinous clot in the larger saccule, presumably the result of his hospital treatment, and by the thickening of the aneurysmal walls. *November 6th*, 1888.

---

8. *Aneurysm of the thoracic aorta bursting into the œsophagus just above the diaphragm, causing fatal hæmatemesis.* (*Card specimen.*)

By John R. Lucas.

Charlotte C—, aged 38, was admitted into the New Marylebone Infirmary, Notting Hill, April 23rd, 1889. She stated that for the last four years she had drunk freely (chiefly rum). For two months before her admission she had lost flesh, but had not vomited until two days before admission, when, without any warning, she vomited a large quantity of blood, and had similar attacks of hæmatemesis, followed by offensive melæna, causing the patient to be blanched and drowsy. She was able to swallow food without pain or immediate sickness. Various drugs were tried, accompanied by rest, but the patient had no relief, but gradually sank

[1] Dr. Sibson on the 'Aorta and Aneurysms of the Aorta,' 1857.

Digitized by Google

and died two days after admission. No physical signs showed themselves in the chest; undue epigastric pulsation was noted, but no murmur could be heard over the pulsation.

Autopsy.—Rigor mortis well marked. On removing the front of the chest wall a large tumour the size of two fists was found lying against the lower dorsal vertebræ above the diaphragm, just behind the heart and pericardium.

The œsophagus was closely adherent to the tumour, and on examination the tumour was found to be an aneurysm of the descending thoracic aorta, which had burst into the œsophagus, just above the diaphragm. The stomach was full of blood-clots; the intestines were distended and full of blood.

The liver was pale and friable. Heart normal. Aorta atheromatous.

May 21st, 1889.

---

9. *Arterio-venous aneurysm of splenic vessels, with thrombosis of mesenteric veins and localised acute colitis.*

By James F. Goodhart, M.D.

A married woman, aged 49, was admitted under me into Guy's Hospital on June 4th, 1888, and she died on July 6th. As a child she had enjoyed good health, but she had suffered a good deal in her life with bilious headache. She had had ten children, and some of her confinements had temporarily affected her health severely. After one of them she had on the day succeeding eighteen fits and subsequent fever, with an illness of five weeks. Her last confinement was twelve years ago, and the catamenia ceased eleven years ago. Eight or nine years ago she had a severe illness lasting fourteen days,—a severe pain in the abdomen, with great tenderness generalised over the abdomen and diarrhœa. She lost flesh, but does not remember that the abdomen was enlarged. The pains recurred occasionally, but gradually left her, and they were unassociated with any indiscretions of diet. Three years ago she had an attack of indigestion. She has been a great tea drinker for the relief of her headaches. During the last winter

Digitized by Google

she has had great discomfort after eating, and has noticed that her abdomen was getting larger, and at the same time the abdomen has been tender and has gradually become more so, to the degree of being unable to bear any pressure; there has also been constipation, with a good deal of flatulence and a constant headache. Eight weeks ago she was seized with a violent pain in the lower part of the back extending to the iliac region, of a stabbing character. Later still, pains in the abdomen of a constant aching character. She had also attacks of diarrhœa. Pain was always relieved by lying down, and disappeared at night. One day, during which she was much easier, she had a sleepless night, felt very ill, and early in the morning vomited some black fluid, and at the same time she passed a pitchy fluid *per anum*. She was sick several times, some of the vomit being bright red blood. She was much exhausted afterwards, and could take nothing but fluids for many days. The abdomen then was not swollen, but on getting up a fortnight after it began to swell rapidly.

When admitted she was a thin wasted woman without jaundice. The abdomen was much distended, globular in shape, the walls tense, the umbilicus flattened out, the skin smooth, the superficial veins dilated, and the surface tender. There was a well-marked thrill. The tongue was clean and moist; there was a good deal of thirst. No nausea or vomiting, but considerable diarrhœa. Nothing was to be obtained from palpation of the abdomen, or by examination of vagina or rectum. The cardiac sounds were rather noisy without bruit, and the impulse rather widely diffused, but not outside the nipple. A loud blowing murmur, in character like a venous hum in the neck, is heard on the left side over the splenic area. It extends backwards to the spine, as far upwards as the sixth rib; and its point of maximum intensity was in the ninth space in the mid-axillary line corresponding to the commencement of the splenic dulness. The bruit was synchronous with the cardiac systole, agreeing with it irregularly. Pulse 104, slightly irregular. The urine contained a considerable quantity of albumen, sp. gr. 1025, no sugar, blood, or casts. She had a good deal of troublesome diarrhœa while in the hospital, and the ascites gradually increased. She was also bothered by retching of mucus. She was tapped and ten pints of fluid removed from the abdomen, and this relieved her so much that she was allowed to sit up; but she immediately became very ill, had hæmatemesis to the extent

Digitized by Google

of 4 oz., and much blood was passed *per rectum*, and she became collapsed within a few hours. She had a second attack of hæmatemesis, and large quantities of blood passed again *per anum*. She never rallied after this, and gradually sank till her death some ten days later. The bruit became markedly weaker after the blood-loss, but it never actually disappeared.

The point that determined a diagnosis in this case was the existence of a peculiar bruit over the region of the spleen. This, with the history of hæmatemesis before admission, the occurrence of ascites, and some indefinite history of dyspepsia, led me to suppose that the case was one of gastric ulcer, in which some secondary thrombosis of the portal vein had succeeded; and the bruit was in some way dependent on the consequent hampering of the splenic circulation, and I had in my mind an aneurysmal dilatation of the splenic vein as a thing that I had seen from this cause, and which would, I thought, explain the bruit.

The actual state of things is not far removed from this, although there are no such conditions existing as I had supposed to lead up to it; and the actual disease is really without any explanation.

The autopsy was made by Dr. Perry. The subjoined are the salient features of it:

There was a swelling occupying the left parotid region, and on cutting into it pus exuded.

The lungs and heart were healthy; the latter weighed 9 oz.

There was some slight atheroma of the thoracic and abdominal aorta, but nowhere extreme.

The vena cava, superior and inferior, were healthy, so also the femoral vein, but there were *ante-mortem* thrombi in the posterior tibial vein.

The peritoneum contained a few ounces of serous fluid, and there were a few old adhesions of the mesentery to the anterior abdominal wall.

The œsophagus and its veins were healthy.

The veins of the stomach, in particular the gastro-epiploica dextra, and the coronary were filled with firm *ante-mortem* thrombus, exactly as if an injection had been made of them. The mucous membrane was everywhere pale, serving as a strongly contrasting background to the dark engorged veins.

Careful examination failed to discover any breach of surface or any ulcer.

Digitized by Google

The small intestines were normal, perhaps rather paler than usual.

About four inches beyond the ileo-cæcal valve there commenced intense congestion of the colon extending along the bowel for eight inches, and very clearly defined from the pale intestine above and below. The branches of the superior mesenteric vein going from this area were found to be full of adherent thrombus.

The liver contained numerous whitish nodules, most of them of the size of a split pea and not projecting above the surrounding area. Microscopically many of the sections of the portal vein were filled with blood clot, but one could not be certain that the clot was organised. There was marked nutmeg change, but no early abscesses. It remains uncertain what the white patches were, but I thought them anæmic, and perhaps fatty areas resulting from thrombosis of the small branches of the portal vein. There was no thrombus whatever in the main branches of vena portæ. The liver was of the usual size, weight, and shape.

Gall bladder contracted; some small calculi, but no trace of ulceration or old inflammation or adhesions.

The splenic vein at the hilum of the spleen was dilated into a cavity the size of a hen's egg, and filled with laminated clot. On dissection a valvular communication was found between the splenic artery and vein, about two inches from the origin of the latter, and in fact is now the wall of the sac above described. The whole length of the splenic vein was dilated and tortuous, and partially filled with *ante-mortem* thrombus, and the dilated sac in like manner contained a saucer-shaped clot of same size of *ante-mortem* formation. The splenic artery is of very full size.

The spleen weighed 5 oz.; it had a thick capsule, and contained several white wedge-shaped infarcts, the largest with a base of one third of an inch. There was some recent lymph on the spleen.

The author has no explanation to offer of the cause of the communication between the two vessels. The case is recorded because of its great rarity, and also because it adds another to the few recorded cases where thrombosis of the mesenteric vessels has led to serious inflammation of the coat of the bowel. Cases of this kind have been published by Dr. Hilton Fagge and Sir William Gull, in which actual gangrene of the intestine had resulted.

May 7th, 1889.

Digitized by Google

10. *Aneurysm of the right brachial and ulnar arteries, resulting from embolism.*

By Frederick Walker Mott, M.D.

C. G—, aged 13, was admitted into Charing Cross Hospital under the care of Dr. Green, April 10th, 1886, for heart disease.

There was a family history of rheumatism, but the patient did not know that he had ever suffered with rheumatic fever. Seven years previously he had been in a hospital for something the matter with his navel. He remembers very little about it, but he thinks it kept him in the hospital some months. The present illness commenced a year ago with palpitation of the heart, increased on exertion; he had been obliged to keep his bed the last four months. There is a visible impulse diffused over the precordial region of a heaving character. The apex-beat is in the fifth space in the nipple line, and a thrill can be felt over the aortic cartilage at its junction with the sternum. There is a soft systolic murmur heard at the apex conducted into the axilla. At the base there is a double murmur, the systolic being conducted up to the sterno-clavicular articulation and the diastolic down the sternum. Pulse 80, collapsing, and there is well-marked capillary pulsation. The patient complained of some pain in the left hypochondriac region, the liver somewhat enlarged and tender. During his stay in the hospital he was the subject of frequent attacks of pyrexia, and this, together with the physical signs previously described, led to the diagnosis,—infective endocarditis of the aortic valves.

April 18th.—Evidently a fresh infarct in the spleen. Temperature 102·5°, and tenderness over the left hypochondriac region. No hæmaturia, but a large trace of albumen in the urine.

May 28th.—Patient complained of great pain and numbness in the right arm. The ulnar pulse at the wrist disappeared. A little later the radial pulse was lost. The limb was wrapped up in cotton wool, and it was considered by Dr. Green that embolism of the ulnar and brachial arteries had taken place. A week or two later the posterior tibial was blocked in a similar way. Patient

Digitized by Google

remained in the hospital until August, when he died. There is no mention made in the notes of any pulsating tumour existing in the right arm in consequence of the embolism.

He had frequent attacks of pyrexia of an intermittent character while in the hospital, the temperature rising to 101° or between that and 103.°

Autopsy made by Mr. Boyd, who has referred to this case in Druitt's 'Vade Mecum.' The principal facts were: Heart weighed 15½ oz., the aortic valve was greatly constricted by huge vegetations, most of them calcified. Small vegetations were seen beginning to sprout from the anterior cusps of the mitral near its base, and on the adjacent part of the ventricular surface. The cardiac substance was pale, but the interior of the left ventricle was remarkable, being speckled and streaked with pale yellow spots and lines.

All the trabeculæ and musculi papillares were thus affected. Left ventricle wall nearly three quarters of an inch thick. Pleuræ, old basic adhesions on both sides, lungs otherwise healthy.

Liver nutmeg; both it and omentum adherent to greater part of anterior abdominal wall.

Spleen universally adherent; four or five infarcts, size of small chestnut downwards, all bright yellow and sunk below the surface, and quite firm.

There were old infarcts in the right kidney, but only cloudy swelling of the left.

The vessels of the right arm and forearm were examined. An aneurysm was found on the brachial a short distance below the teres major tendon about three quarters of an inch in length, and filled with an organising and laminated thrombus. Another, oval, about one inch in the long diameter, was found on the ulnar, just where the interosseus comes off. It was of the saccular variety and lay just below the small head of the pronator radii teres. All the surrounding parts were closely adherent to it and had a gritty feel, owing to calcareous deposit.

Sections were made of the wall of aneurysm and contained clot, but not until some years after it had been put up as a museum preparation; therefore it will be useless to argue as to the infective condition of the vessel wall, because precautions were not taken to prevent changes occurring.

Microscopical observations of these sections show that the inner

Digitized by Google

coat has been completely destroyed and that the structural elements of the inner and outer coats are separated by large numbers of pus-cells. The sac of the aneurysm is filled with a laminated clot in places undergoing organisation, thus accounting for the absence of pulsation during life.

If the section of the wall of this aneurysm be compared with a section of a vessel either blocked by a non-infective embolus or thrombosed from an aseptic ligature the difference in the conditions will be very obvious. In the latter, the elastic lamina, even the subendothelial layer, is intact, and as to the middle and outer coats they present a normal appearance, in striking contrast with the suppurating condition of the wall of the aneurysm. On the other hand, there is a striking similarity between the microscopic appearances of the wall of an artery which had been ligatured, the wound having become septic and from which secondary hæmorrhage had occurred. In this, as the specimens show, the wall is undergoing a process of ulceration, the middle coat being infiltrated with pus-cells.

The sections were examined for micro-organisms, but, as previously mentioned, although present, no satisfactory inference could be drawn.

The points of interest in this case are these:—1st. That undoubtedly embolism of an artery may produce aneurysm. 2nd. The case was one of calcified aortic valves, like that described by Ponfick in 'Virchow's Archives,' vol. lviii; but although it is reasonable to believe that irritation and ulceration of the vessel wall would be more likely to arise from a calcareous mass when impacted than a soft vegetation, yet we have here in this case a more important factor in the production of the ulceration and softening of the vessel wall, namely, an infecting condition of the embolic particles. 3rd. The striking similarity between the condition of the vessel walls in this case and in that of ulceration and secondary hæmorrhage of the popliteal artery in a case of wound infection after ligature.

I was unable to find the embolus, but I consider that the conclusion arrived at by Mr. Langton and Mr. Bowlby that the aneurysm is developed at the seat of embolism is proved by the fact that the aneurysm of the ulnar occurred just at the situation (namely, where the large interosseous branch is given off) where impaction would occur.

Digitized by Google

The above observers, in a most able paper on the subject, come to somewhat similar conclusions ('Med.-Chir. Trans.,' vol. lxx).

April 2nd, 1889.

---

11. *Thrombosis of aorta.*

By G. Newton Pitt, M.D.

[With Plate III.]

The specimen was taken from a man, aged 56, with epithelioma of the lower jaw, which was in consequence excised. The man was in a feeble state on admission, but he became much more so after the operation, and died of asthenia after a few days. During life there was nothing to suggest any local vascular trouble. The descending and the transverse arch of the aorta, especially on the convex and posterior surfaces, is lined by a firmly adherent decolourised clot; but there is still a moderate passage in the centre.

The clot on the convex surface is breaking down in the centre, the cavity of which is exposed. This veneer of clot is smooth and dense on the surface exposed to the blood-current. The clot lines the posterior surface smoothly. The aorta is very atheromatous, and the extending arch dilated. The clot extends from five inches below the subclavian up to the origin of that vessel.

To the upper part of the undoubtedly *ante-mortem* clot is a mass extending up to the heart. A part, but not all, of this is *post mortem*, and the same applies to a mass depending for some inches in the descending aorta. At the lower part of the descending aorta is a nodule of *ante-mortem* clot the size of a walnut.

Extensive thrombosis of the thoracic aorta must be extremely rare, as no cases have been recorded in our 'Transactions,' and I can find no references in any of the books I have referred to, with the exception of one recorded by Taurand ('Prog. Méd.,' x, 1882, p. 147).

We have in the museum at Guy's Hospital specimens with large *ante-mortem* clots at the bifurcation of the aorta, due to atheroma,

Digitized by Google

Digitized by Google

DESCRIPTION OF PLATE III.

To illustrate Dr. Pitt's case of Thrombosis of the Aorta. (Page 74.)

Digitized by Google

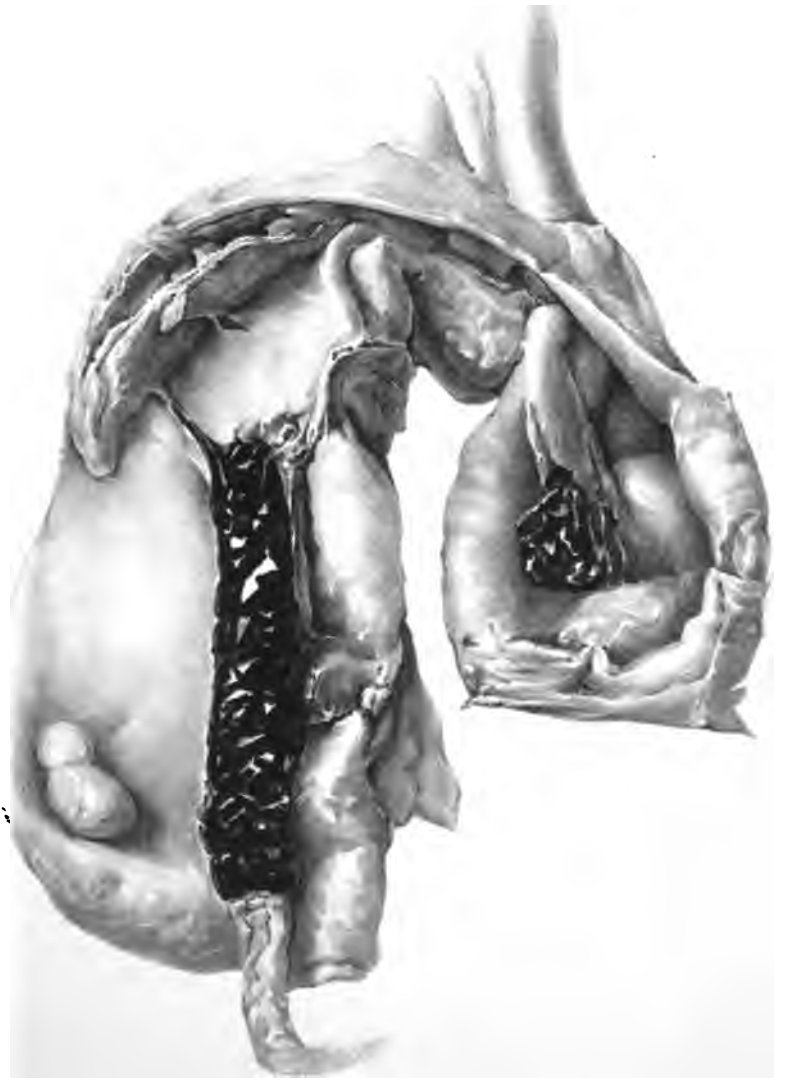

Digitized by Google

Digitized by Google

and I have seen a small thrombus on an atheromatous patch, but so extensive a thrombus near the heart must be rare.

May 21*st*, 1889.

---

12. *Thrombosis of veins of neck.* (*Card specimen.*)

By J. A. Ormerod, M.D.

The specimen shows complete obstruction of both innominate veins, internal jugulars, subclavians, anterior and external jugulars. They are filled with adherent clot. The clot is rather firmer on the right side than on the left. A projecting end of clot hung into the superior cava, but was not adherent here. The clot ceased at the opening of the azygos. The azygos and the superior intercostal opening into it were pervious and dilated. There was no clotting in the cerebral sinuses.

The patient was under Dr. Gee's care, and was admitted for mitral stenosis. There was much dilatation of the left auricle and right chambers. The symptoms of thrombosis, which developed in the hospital, pointed to its commencement in the right subclavian vein. No local cause could be found for it *post mortem*.

April 2*nd*, 1889.

Digitized by Google

IV. DISEASES, ETC., OF THE ORGANS OF DIGESTION.

1. *Simple ulcers of œsophagus.* (*Card specimen.*)

By H. W. G. Mackenzie, M.B.

In the upper part of the œsophagus are two similar flat oval patches of ulceration with their long diameters longitudinal, about three quarters of an inch by a quarter of an inch. Edges unthickened and even with the mucous membrane. Their floor is cicatrising, and there is no sign of granulation tissue. They have therefore the appearance of healing and comparatively recent ulcers, and look as if they had been in apposition.

From a child aged 22 months, who died of diphtheria. The child had only been ill for two days when tracheotomy was performed, and the child died two days later. Had never been ill before. No history of difficulty in swallowing, nor of possible injury to œsophagus. There was membrane on the upper part of the soft palate, and much in the trachea. *October* 16*th*, 1888.

---

2. *Sarcoma of œsophagus.* (*Card specimen.*)

By J. H. Targett, M.B., M.S.

This specimen was taken from a man aged 70, who had suffered from dysphagia for the last three months of his life. When admitted to the hospital he was unable to swallow anything but fluid food. There was much pain at the middle of the sternum and between the shoulders. No glandular enlargement detected. He had long been troubled with a cough, and there were marked physical signs at the right apex of the lung. An attempt to

Digitized by Google

swallow a portion of softened bread nearly choked him, but he continued to take fluids till his death.

Autopsy.—Body extremely wasted. There was recent lobular pneumonia in the lower lobes of both lungs, and extensive fibroid change with cavitation at the right apex. There appeared to be no secondary deposits of new growth in the viscera.

The œsophagus contained the tumour which is shown in the specimen. It was attached to the anterior wall of the gullet, and in the recent state measured four inches and a half long by two and a half broad, and about one inch and a half in thickness. Its upper border was just opposite the bifurcation of the trachea, and it extended down very nearly to the cardia. The œsophagus was distinctly dilated at the site of the growth, which was moulded to the form of the tube. The tumour was somewhat constricted at its attachment to the wall of the gullet.

On section it was found to spring entirely from the submucous tissue, the muscular coat being quite free, except at one small spot where the growth was perforating it. The mucous membrane could be traced a short distance over its upper and lower edges, but on the free surface it had been destroyed by ulceration and sloughing of the growth. The tumour itself appeared to be composed of a white uniform substance, firm and succulent, resembling encephaloid cancer. Histologically it was made up of small round, oval, spindle, and tailed cells, in varying proportions in different parts of the section. Some of the tailed cells were very large indeed, and contained three or four nuclei. There was no trace of alveolation, but many of the spindle-cells were arranged in bands running in various directions. Some parts had a much looser texture resembling myxomatous tissue. Healthy mucous membrane could be seen covering the new growth in certain sections.

This specimen is preserved in Guy's Hospital museum, and it is the first example of sarcoma of the œsophagus recorded in the 'Transactions' of this Society. *May* 21*st*, 1889.

Digitized by Google

3. *Fatty tumour in wall of stomach.* (*Card specimen.*)

By H. Montague Murray, M.D.

A fatty tumour in the wall of the stomach of a patient aged 64. It is situated in the submucous tissue of the posterior wall, close to the lesser curvature, and exactly two inches from the pyloric valve. Its structure is typical of the class to which it belongs. *November 6th*, 1888.

---

4. *Ulcer of the stomach close to the pylorus.* (*Card specimen.*)

By Frank Penrose, M.D.

F. I.—, aged 42, was admitted into St. George's Hospital on January 21st, 1889, for wasting and vomiting. In 1883 he first began to vomit blood, and has been doing so at more or less frequent intervals ever since. Death occurred from perforation.

The specimen is a much dilated stomach, and just within the pylorus is the opening of a gastric ulcer, and this opening leads into a small cavity with tolerably thick walls of inflammatory tissue. The perforation occurred through a weak spot in this cavity where it was lying beneath the left lobe of the liver. *March 5th*, 1889.

---

5. *A case of cancer of the stomach, ? originating in a chronic ulcer.*

By James F. Goodhart, M.D.

The interest of this case is chiefly in the history. The patient was a whitesmith, aged 32, who was at first under the care of Dr. Bull, of Chislehurst and afterwards under Dr. Wade. Rather more than two years before his death he first began to suffer with indigestion, fulness after food, and eructations. Sixteen months before his death he began to vomit, and when I saw him first,

Digitized by Google

thirteen months before his death, he was vomiting daily, at irregular times after his food, sometimes directly, sometimes not for many hours, when he would generally bring up a quantity. He said he had wasted a good deal. He had never vomited blood, nor had he passed any black evacuations.

He was very pale, and there was evidence of moderate dilatation of the stomach with a little induration under the upper belly of the left rectus abdominis. On looking carefully into the case, however, his only symptom was the vomiting, and as his temperament and surroundings were such as to make his nervous tone low and emotional I was much disposed to look upon this as chiefly a matter of bad habit on the part of the stomach, possibly called into existence, as Dr. Bull suggested, by some chronic gastritis. He got no better at home, so he was admitted into Guy's Hospital, and there remained for four weeks. During that time he was fed carefully, and for some days entirely on milk, with the result that he was never sick after he came into the hospital, and he gained some pounds in weight.

For two months after he left the hospital he was much better and he went to work again, but at the end of that time all his old symptoms returned and he was able to do no work afterwards. He then came under the care of Mr. Wade, of Chislehurst, and the case slowly developed into unmistakable cancer, and he died rather more than two years after the first onset of symptoms. I must confess that for a long time I was unwilling to accept that interpretation of the case, very much because his symptoms had all subsided when he was in the hospital under conditions of dieting which could be carefully watched, and because outside the hospital there was wanting to the case all stimulus to improvement, as I thought. Mr. Wade was kind enough to acquaint me of the man's death and to allow me to make the autopsy with him, and the result is, I think, of interest. The stomach, at one time dilated, is now closely contracted and its walls thickened by a diffuse carcinomatous growth, and close to the pylorus, where the thickening is greatest, and I suppose the disease oldest, there is a shallow elongated excavation which looks to me strongly suggestive of the primary disease having been a gastric ulcer. My view of the case is that such has been the history of the disease; that when he first came under notice a gastric ulcer existed which for the time got better, and then a cancerous growth developed in its

Digitized by Google

floor. The growth consists of what I should call a glandular cancer, that is to say of acini lined by cubical epithelium. I have not had time to examine carefully the records of our 'Transactions' for similar cases, but there are cases of cancer with perforation and one of cancer cicatrising which may be of this sort, but I do not remember any case brought forward with this point made concerning it, although I have, in the course of some years in the *post-mortem* room at Guy's Hospital, seen several cases in which the appearances were all in favour of such a view. I believe from what I have seen that malignant disease of the stomach not uncommonly originates in chronic ulcers. *April 16th*, 1889.

---

6. *Lymphadenoma of the stomach and intestines.*

By G. Newton Pitt, M.D.

[With Plates IV and V.]

The specimens were removed from Joseph B—, aged 48, who was admitted under Dr. Pye-Smith on February 9th, 1888, with cough and shortness of breath; and towards the end he was under my care. His family history was good. His health up to nine months ago, with the exception of a venereal attack twenty-four years previously, was good.

In November, 1887, at the Westminster Hospital, Mr. Bond removed a myxoma the size of a small egg, which had been growing for fourteen years from the inner canthus of the right lower lid. On admission now, there is again a small nodule in that region, and one the size of a small nut in the left sac of seven years' standing. He has lost flesh greatly during the last four months.

Condition on admission.—There is deficient movement, breath-sounds and tactile vocal fremitus at the left apex with deficient resonance, and breath-sounds at the base, which were taken to indicate pressure on the left bronchus. The tonsils are very much hypertrophied and elongated, meeting in the middle line, the pro-

Digitized by Google

jecting portion of one of them was removed, soon after he came in. Urine sp. gr. 1015, no albumen.

February 27th.—Very troublesome diarrhœa and pyrexia for some days.

March 2nd.—Pleuritic rub audible in front on the left side about the eighth space.

3rd.—There is dulness behind up to the eighth rib, and in axilla up to seventh. Blood-stained serum was removed by a morphia syringe from the ninth space behind.

14th.—Patient has had severe attacks of pain in the left side.

21st.—He has gradually become weaker, and bronchial breathing and bronchophony have been audible over the left base for some days.

25th.—Pupils unequal, the right being contracted.

April 3rd.—Fourteen ounces greenish pus were aspirated in the ninth space in posterior axillary line.

7th.—Left chest dull up to seventh rib behind, with diminished breath-sounds. In the axilla there are râles and bronchial breathing.

17th.—The patient has now become extremely emaciated, and has for some time been profoundly anæmic. He is frequently very excited for some hours at night; he battles with the curtains of his bed, fancies he is starved, and crams newspaper or anything else handy into his mouth, but in the morning he is again quite rational.

23rd.—As the patient was emaciating so rapidly, and was suffering with diarrhœa, it was thought desirable to attempt to drain the chest. Under an anæsthetic an incision was made in the eighth space behind, two or three ounces of pus came out, and then the cavity bled freely, the blood welling out to the amount of fifteen ounces or more. The pulse became more rapid, respiration ceased, and he died.

While the patient was in the hospital the temperature varied from 99°—100° but once reached 102·6°.

The clinical features of the case were always obscure, but at first all that could be made out was evidence of pressure on the left bronchus, and it was discussed whether this could be associated with the tumour of the eyelid which had been removed.

The abdomen was carefully examined, but no evidence of anything abnormal was made out. During the last month of his life

Digitized by Google

attention was concentrated on his chest, and the abdominal condition was probably not so carefully examined as previously, at any rate there was not the faintest suspicion of any evidence of abdominal disease until the *post-mortem* examination. It was supposed that the empyema was secondary to some malignant growth at the root of the lung; and this was probably the case.

One of the noteworthy features of the case was the profound anæmia, but when first examined there was no evidence of any abdominal disease.

Post-mortem examination.—Body extremely emaciated.

The left lung is densely adherent to the chest wall, over the upper part anteriorly, and over the whole of the posterior part near the spine, and to the diaphragm on its under surface. There is a localised encysted empyema at the outer part near the apex, containing two to three ounces of pus. There is another occupying the axillary and antero-external regions, bounded behind by adhesions along the posterior axillary line, and containing a little pus. The parietal pleura in this region is not thickened. There is a third empyema in the back which had been opened. This contains six ounces of blood-stained pus without any clot. The parietal pleura is thickened, irregular, velvety to the finger, and very vascular. The hæmorrhage had come from the pleura. The costal layer of pleura is thickened and forms a fibroid layer one twentieth to one eighth of an inch thick; in places this is white in colour and vascular on the surface. The left lung is carnified, there is excess of fibrous tissue near the surface, and along the trabeculæ. The tissue is œdematous, friable, and contained less air than normal. In the upper lobe are some small recent irregular cavities one quarter to one half of an inch across, corresponding to the distribution of the compressed bronchus.

Between the bifurcation of the trachea are large swollen glands, one of which contained a calcareous nodule. There is one gland immediately beneath the left bronchus, which is infiltrated with growth. The bronchus is compressed and its lumen diminished by a nodule of growth projecting on its mucous surface. Microscopically this appeared to be sarcoma rather than lymphoma; but the section had been badly hardened, and I could not be certain.

The right lung is emphysematous at the anterior margin, especially of the inferior lobe. There is pus in the larger bronchial tubes.

Digitized by Google

Digitized by Google

DESCRIPTION OF PLATE IV.

Illustrating Dr. Pitt's case of Lymphadenoma of the Stomach and Intestines. **(Page 80.)**

***A.*—Pylorus.**
***B.*—Cardia.**

Digitized by Google

Digitized by Google

Digitized by Google

Digitized by Google

DESCRIPTION OF PLATE V.

To illustrate Dr. Pitt's case of Lymphadenoma of the Stomach and Intestines. (Page 80.)

FIG. 1.—Lymphadenoma of the mucous membrane of the intestines. The cæcum and ileum are laid open. A glass rod projects from the orifice *B* of the large tumour (*C*), representing the vermiform appendix; the ileo-cæcal valve *A*, and an adjacent Peyer's patch are seen to be the seat of extensive adenoid growth.

FIG. 2.—Portion of the mucous membrane, with the nodules of lymphoid growth on the solitary follicles and Peyer's patches. There was a similar condition throughout the intestine.

Digitized by Google

Fig. 1.

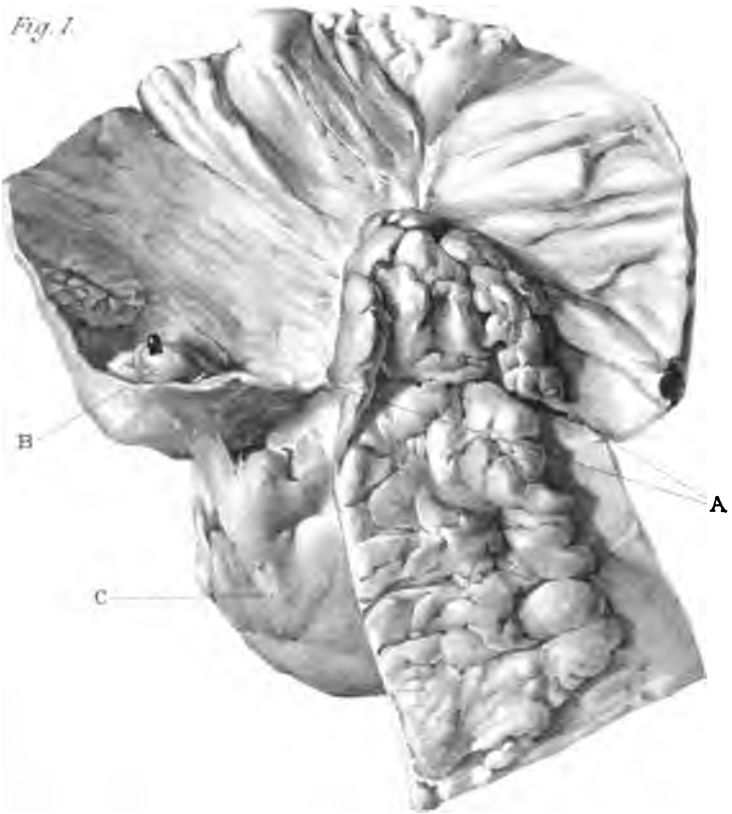

Fig. 2.

Digitized by Google

Digitized by Google

The left and upper part of the pericardium is $\frac{1}{12}$ inch thick, and presents an appearance of dense fibroid tissue similar to the pleura.

Only one gland is affected in the thorax.

Heart normal.

There is marked hypertrophy of the tonsils, the left is two and a half inches, and the right two inches long; the enlargement extending chiefly down the pharynx. There are three lymphoid masses one third to one half inch across at the base of the tongue. There is no lymphoid overgrowth in the naso-pharynx. The œsophagus is healthy.

There are enormous masses of lymphoid overgrowth on the mucous wall of the stomach, forming large sessile tumours. At the cardiac end, two inches from the œsophagus, are large masses, both sessile and polypoid, one of which is two and a half inches broad, two inches long, and one inch thick. Others occur as raised vermiform overgrowths, ramifying over the surface, of the thickness of a little finger.

Over the greater portion of the body of the stomach there is also a less extensive lymphoid growth, occurring as small raised flat patches of varying sizes. On the larger curvature, one and a half inches from the pylorus, is a flat mass of growth one and a quarter inches across, raised one third of an inch, with a cupping of the surface, which also occurs to a less extent in several of the other growths.

The parts least affected are the anterior surface, the mucous membrane for two inches to the left of the œsophagus, and that close to the pylorus.

The growths are all creamy white in colour, very soft and succulent, and the largest masses are breaking down at their base. The mucous membrane is rather hyperæmic between the growths; the surface is not ulcerated.

There is an area of mucous membrane in the duodenum, extending for one and a half inches, sharply bounded by the pylorus above, which is closely covered with numerous raised lymphoid growths, about one third of an inch across, irregularly stained slaty black from blood-pigment. The rest of the duodenum is comparatively healthy, and shows only a few soft, raised, flattened patches. The whole of the small intestine is dotted over with many thousands of raised lymphoid growths, about the size of large peas,

Digitized by Google

scattered about singly. There are flat plaques of growth in the Peyer's patches, which are raised about one sixth of an inch. Many growths are ulcerated on the surface and many are stained with blood-pigment. Eighteen inches above the cæcum are two raised patches; one three by one and a half inches, and the other one and a quarter inches by three quarters of an inch. There are large masses of growth along the edges of the ileo-cæcal valve.

The mucous surface of the cæcum is dotted with pigment spots. The orifice of the vermiform appendix is occupied by a pigmented polypoid mass the size of a large chestnut, and on the serous surface is a soft succulent tumour, two and a half by two and a half inches by one inch, which has grown in connection with the vermiform appendix.

On section the surface is lobulated, and in it the wall of the vermiform appendix can be traced for one inch.

Throughout the colon there is an abnormal amount of pigment about the follicles, but there is no lymphoid overgrowth.

The peritoneum is healthy. The mesenteric glands are universally swollen and enlarged, averaging one half by one quarter by one quarter of an inch. Some of the lumbar glands are enlarged.

The spleen weighs 25½ oz., was soft, and shows a general hypertrophy of the Malpighian bodies, which averages one twelfth of an inch; they are white and denser than usual. The liver and kidneys are healthy.

Microscopically the growths in the stomach and elsewhere were found to consist of a dense collection of small cells in an adenoid reticulum, which was with difficulty discoverable.

One especial point of interest was the thick, extremely vascular lining of the costal pleura, which led to a fatal hæmorrhage when opened. It appeared probable that this was due to a lymphoid growth in the wall. The large tumour round the vermiform appendix is very similar to the condition present in Case 1, but must be a very rare occurrence.

It is by no means clear why the lymphoid growth is very scanty at the pyloric end of the stomach, a region where carcinoma is most common, and where one often sees in children a slight overgrowth of the normal lymphoid tissue, which, according to Watney, is more abundant at this spot.

The lymphoid growth also is very marked in the first part of the

Digitized by Google

duodenum, and is sharply limited above by the pylorus, in this manner also sharply contrasting with the growth of carcinoma.

Cases of lymphadenoma of the intestinal tract seem to fall into two great groups,—those in which the growths commence in the mucous and submucous coats, and form tumours projecting into the lumen of the bowel, and those in which the growth forms a diffused sheath, extending along the subserous surface, and but occasionally reaches the mucous and submucous coat. They seem to correspond to the two groups of lymphoid tissue; the follicles and lymphatics of the mucous membrane, and the lymphatics of the muscular and subserous coats.

The former, to which this case belongs, do not alter the calibre of the bowel, and but rarely ulcerate. Their seats of election appear to be the lymphoid areas of the vermiform appendix, the ileo-cæcal valve, Peyer's patches, and the solitary follicles of the small intestine, more rarely the duodenum, the cardiac end of the stomach, and the tonsils. The œsophagus and large intestine have entirely escaped in some cases.

In the latter group, the growth forms a sheath, which invades the muscular coat, paralyses it, and hence leads to dilatation; the growth where it reaches the surface of the bowel is apt to ulcerate, probably because its vascular supply is more defective than in the first group of cases, where the muscular coat is uninjured. In most cases of this group we find the growth has spread from the mesenteric glands. It does not especially affect the solitary and agminated glands. Severe diarrhœa is a prominent symptom.

Of the first group a few cases only have been recorded by the following authors:

1. *Dr. Carrington.*—This case is almost identical with mine. Woman, aged 55, with enlarged cervical glands, and a history of wasting for six months, was admitted under Dr. Goodhart, and without presenting any abdominal symptoms, died after some months with lymphoid growths, forming flattened tumours in the stomach, on the solitary glands and Peyer's patches throughout ileum. Large mass of growth round vermiform appendix and ileo-cæcal valve. Large spleen.

2. *Briquet.*—Man, aged 43, with general enlargement of lymphatic glands. The gastric mucous membrane was very much thickened by masses of lymphoid overgrowth. There were nodules of growth throughout the large and small intestine.

Digitized by Google

3. *Dr. Coupland.*—A woman, aged 24, with an abdominal tumour, jaundice and emaciation, who died of intestinal obstruction. *Post mortem* there were soft vascular growths two inches across, beneath the mucous membrane of the stomach, near the pylorus, and also two growths in the duodenum, one being the size of a Tangerine orange with an ulcerated surface; there were also growths in the retroperitoneal glands.

4. Langhans, in 'Virchow's Archiv,' vol. liv, refers to a case of Wunderlich's, published in 1866, in which the follicles of the stomach and small intestine were enlarged to the size of coffee beans, and both tonsils and Peyer's patches were hypertrophied. Near these nodules of growth there was also a marked soft juicy infiltration of the mucous membrane in patches, where normally lymphoid tissue is scanty. The stomach, upper part of the duodenum, ileo cæcal valve, vermiform appendix and rectum were especially affected. The patient suffered during life with diarrhœa.

Wunderlich, in his paper, also refers to cases recorded by Craigie, Rokitansky, Lambl and Cossy, in which there was lymphoid overgrowth, forming nodules in the intestinal mucous membrane.

5. *Dr. Hadden.*—Man, aged 54, with abdominal tumour and emaciation. A large lymphoid tumour invaded the mesentery and retroperitoneal glands. The spleen was large. There was one small nodule in the stomach and a general hyperplasia of the solitary and agminated glands throughout the intestine, forming near the cæcum enormous masses. There was no ulceration.

6. Probably under this group should also be included a second case of Dr. Hadden's—

A girl with enlarged glands and leucocytosis. *Post mortem* the solitary follicles of the small intestine were found to be enlarged, and hæmorrhages had taken place into them. There was a general lymphadenoma of the glands.

7. Dr. Chvostek reports a case of lymphadenoma with large glands in the axillæ and small white nodules of growth in the solitary follicles and one in the stomach.

Cornil and Ranvier, however, speak of having met with several cases of lymphoid growth in the mucous and submucous tissues of the alimentary canal, and Friedreich refers to lymphoid tumours, the size of a dollar, in the mucous membrane of the stomach.

Digitized by Google

Under the group of cases where the lymphoid growth affects the mesenteric glands and has grown round the intestine along the subserous coats, forming it into a rigid, more or less dilated tube, I should include cases reported by—

8. *Dr. Coupland.*—Woman, aged 25, with a history of intractable diarrhœa for months. The tonsils were normal. There was a large growth in mesenteric glands, which also extended as a sheath in the wall of the small intestine, which was ulcerated in places; there were also small nodules in the colon.

9. *Dr. Moxon.*—Man, aged 30, with anasarca, distended abdomen, and diarrhœa. There was a large lymphoid growth in mesentery, which surrounded, but did not compress, the small intestine.

10. *Dr. Taylor.*—Boy, aged 6, with anasarca, mass to be felt in the abdomen, with frequent motions. A mass of lymphoid growth invaded the mesentery and surrounded the small intestine for nine inches. The affected wall is much thickened, the cavity dilated, and the surface ulcerated.

11. *Dr. Arnott.*—Boy, aged 4, with abdominal tumour, which was fatal in one month. The mass grew in the large omentum, surrounded the colon in one place, and partially so in another, the mucous surfaces of these growths being ulcerated. The microscopic structure was lymphoid tissue.

12. *Dr. Murchison.*—Man, aged 24, with abdominal pain, distension, and emaciation. The growth invaded the mesenteric glands, where it formed a large tumour; it also involved the wall of the duodenum for eight inches, forming a ring one to two inches in thickness in one part, in which the muscular coat was lost. The calibre of the bowel was not diminished, nor the surface ulcerated.

13. *Dr. Bergeron.*—Boy, aged 12, with abdominal tumour, profound debility and emaciation, diarrhœa, and colic. The retroperitoneal and mesenteric glands were enlarged, and the mesentery thickened. The ileum, 30 c. m. above the cæcum, was surrounded by a ring of growth for 10 c. m., but which had not led to any contraction of the calibre. The surface was mammillated, and had ulcerated in two places.

Digitized by Google

14. *Dr. Barth.*—Man, aged 21; five months abdominal pain and diarrhœa. Appearance suggestive of chronic Bright's disease; very anæmic. Blood 70 per cent. red cells; white, normal. There was a mass of thickened intestine which during life had been mistaken for the spleen. The walls of almost the whole of the small intestine are thickened, especially in the duodenum; the cavity is dilated, the inner surface is irregularly ulcerated and ecchymosed and thrown into nodules on the surface. Valvulæ conniventes not thickened. The colon was healthy.

15. *Dr. Ketsch.*—Man, aged 32, with headache, weakness, extreme anæmia, and no physical signs of disease. The small intestine, with the exception of the duodenum, was more or less thickened by patches of lymphoid growth, which in places surrounded the bowel. There were twelve ulcerated patches, the edges of which were raised, and their bases dotted with lymphoid tissue. The wall of the colon was infiltrated but not ulcerated.

16. *Dr. Fagge.*—There is a specimen in Guy's museum of a small intestine with lymphadenomatous growth infiltrating the mesentery, and in places surrounding more or less completely the bowel. At these spots the bowel is dilated and the growth sometimes ulcerated. The child had been under his care at the Evelina Hospital.

17. *Dr. Norman Moore.*—Woman, aged 41, with abdominal tumour, which *post mortem* was found to be located in mesenteric glands, while the wall of the duodenum was surrounded, thickened, and the mucous surface ulcerated.

18. *Mr. Silcock.*—Boy, aged 4, with abdominal pain and tumour. A lymphoid growth was found in the mesentery the size of a cocoa-nut, which had also invaded and surrounded some feet of the upper part of the ileum, which was coiled up. The lumen was dilated and the inner surface ulcerated.

1. Carrington, 'Path. Trans.,' vol. xxxv, p. 386.
2. Briquet, 'Cruveilhier's Atlas,' (liv. xxxiv, plates 2 and 3).
3. Coupland, 'Path. Trans.,' vol. xxviii, p. 127.
4. Langhans, 'Virchow's Archiv,' vol. liv; and 'Arch. der Heilk.,' vol. vii.
5. Hadden, 'Path. Trans.,' vol. xxxix, p. 128.
6. Hadden, 'Path. Trans.,' vol. xxxvii, p. 261.
7. Chvostek, 'All. Wien. med. Zeitung,' 1877, p. 14.

Digitized by Google

8. Coupland, 'Path. Trans.,' vol. xxix, p. 363.
9. Moxon, 'Path. Trans,' vol. xxiv, p. 101.
10. Taylor, 'Path. Trans.,' vol. xxviii, p. 135.
11. Arnott, 'Path. Trans.,' vol. xxv, p. 150.
12. Murchison, 'Path. Trans.,' vol. xx, p. 192.
13. Bergeron, 'Union Médicale,' 1867, ii, p. 555.
14. Barth, 'Progrès Méd.,' 1879, vii, p. 784.
15. Ketsch, 'Bull. de la Soc. Anat.,' 1873, p. 558.
16. Fagge, 'Catalogue Guy's Hosp. Mus.'
17. Norman Moore, 'Path. Trans.,' vol. xxxiv, p. 99.
18. Silcock, 'Path. Trans.,' vol. xxxv, p. 348.

March 19th, 1889.

---

7. *Diffuse sarcoma of the stomach.* (*Card specimen.*)

By H. Handford, M.D.

The specimen was taken from the body of a man, aged 74, who was under my care in the General Hospital, Nottingham, in May, 1886, complaining of rapid loss of flesh and strength, and of swelling of the legs. He had not suffered from vomiting, but had almost constant nausea. A hard mass could be felt in the right lower part of the epigastrium. It did not move with respiration, but the abdominal walls were raised from it during expiration. There was very obstinate constipation. He suffered from œdema of the lower extremities and ascites, and died three weeks after admission.

At the inspection, sixty hours *post mortem*, the abdomen was greatly distended, and there were three or four pints of straw-coloured fluid in the abdominal cavity. The stomach occupied its normal position, but was fixed to the posterior wall of the abdomen, and was quite immovable. The small intestines were much distended, and many coils of them were found *in the epigastrium in front of the stomach*. The great omentum was shrunken and atrophied, indurated from infiltration with new growth, and presented no sign of the presence of fat. By this condition of the omentum the transverse colon had been dragged upwards and fixed in contact with the greater curvature of the stomach. The cæcum was enormously distended; the ascending colon partly dis-

Digitized by Google

tended and partly collapsed. No reason for the abrupt change from great distension to collapse could be discovered. The transverse colon was collapsed, about an inch and a quarter in diameter, and much indurated by infiltration with new growth, which had evidently extended to it through the omentum. The lower half of the circumference was much less thickened than the omental half. The stomach walls were very much indurated, and reached a thickness of from one third to one half of an inch. The infiltration was the greatest at the pylorus and at the cardiac end, but stopped abruptly at the sphincters, neither the duodenum nor the œsophagus being at all affected. The walls were so rigid that on opening the stomach it did not collapse, but gaped like an india-rubber bottle. The mucous membrane was rough, uneven, and in places slightly eroded, but nowhere distinctly ulcerated. There were no secondary growths in any of the viscera, except one nodule in the cortex of the left kidney. The mesenteric glands were enlarged, and the vena cava and aorta were embedded in a mass of confluent glands, which matted together the pancreas, stomach, duodenum, and transverse colon. The pancreas itself appeared not to be affected.

On microscopic examination the most striking feature was a very extensive cellular infiltration, affecting especially the submucous and muscular coats and the deeper parts of the mucous membrane. The gastric follicles, though embedded at their deeper parts in a small-celled infiltration, were not otherwise much altered. This comparatively slight affection of the mucous membrane in all parts of the stomach, together with the great thickening of the submucous layer, and the very extensive infiltration of the muscular coat, made it evident that the growth must have originated in the submucous layer, and certainly not in the mucous membrane. Besides the small-celled infiltration there were portions consisting of round nucleated cells, varying in size, and many irregularly spindle-shaped cells, with an abundant, indistinctly fibrillated intercellular substance. In fact, the tissue resembled granulation tissue, or a granulation tissue (mixed) sarcoma. Had it not been for the secondary growth in the kidney (which was unfortunately not preserved and not examined microscopically) it might readily have been considered, notwithstanding the very great thickening, that the condition was a chronic inflammatory one. Nowhere did the cells present an epithelial appearance, nor was any alveolar

Digitized by Google

structure to be found. The appearance and arrangement of the tissue elements of the new growth, together with its apparent origin in the submucous (mesoblastic) layer, make it probable that the growth was a sarcoma.

Sections of the transverse colon presented exactly the same appearance as the stomach, except that being involved from the periphery the mucous layer was still less affected. In a few places the cells had undergone a colloid degeneration. This form of degeneration is common to both carcinomata and sarcomata, but is more frequent in the former, though there is ground for thinking that many so-called colloid cancers are really sarcomata. The advanced age of the patient probably influenced considerably the atypical course of the growth. The absence of a sharply-defined tumour and the infiltrating character of the growth were its chief characteristics. It is true that this tendency to diffuse infiltration is specially common in the so-called colloid cancers. And, further, in old people cancer of the stomach is said to be specially marked by the absence of localised outgrowth, the tendency to diffuse infiltration, and the cicatricial structure of the growth. It is by no means certain, however, that either of these groups are true carcinomata, originating in tissues developed from epiblast or hypoblast, consisting essentially of epithelial elements, and presenting an alveolar structure.

It is probable that the present specimen is of the same nature as the one shown at the meeting of the British Gynæcological Society on April 10th, 1889, by Dr. R. T. Smith, and described as "fibroid induration of the stomach, intestines, peritoneum, and pelvic viscera;" and also the same as the cases described under the heading of "gastric induration," by Fagge, who says, "Probably it is impossible to distinguish cases of this kind from those of diffused sarcoma." Indeed, where the stomach walls reach a thickness of from half an inch to an inch and a half, as mentioned by Fagge, it is difficult to look upon the case as other than one of new growth. In the present case the secondary growth in the kidney made it clear that we had to do with a malignant growth.

May 21st, 1889.

Digitized by Google

8. *Ulcers of intestine and stomach from a case of chronic Bright's disease.* (*Card specimen.*)

By R. G. Hebb, M.D.

E. L—, female, aged 9, was admitted into Westminster Hospital on January 10th, 1889, under Dr. Sturges. Was in her usual health until six months ago, when she became languid, complained of headache and vomited of mornings. Gradually became worse and lost flesh. Mother first noticed that her urine was thick at the beginning of 1888; was not so before. Frequent micturition, which continued till admission. Had "consumption of the bowels" when 1½ years old, diphtheria at 2, scarlet fever at 2½, and measles at 5 years. Quite recovered from the scarlet fever. Family history *nil*. When admitted was pale and had slight anasarca. The urine was highly albuminous and contained blood; passed 20 to 22 oz. daily. Constipation. Her condition remained stationary till February 23rd, when she became orthopnœic. Pericarditis was now noticed. The vomiting became worse and her legs swelled. March 5th, vomited blood. On the 7th profuse diarrhœa set in. On the 11th complained of great pains in the abdomen. Died March 15th. The urine always contained ⅛ to ¼ albumen, and at last became solid on boiling. The temperature was never above normal.

Post-mortem examination.—Body extremely emaciated, surface and viscera pallid. Brain 40 oz., normal. Lungs, chronic pleuritis of both sides. Bronchitis. Œdema. Heart with pericardium weighed 8½ oz.; the pericardial sac contained excess of fluid, and there was slight recent pericarditis. Hypertrophy of left ventricle, the wall measuring from four to five eighths of an inch in thickness. Endocardium normal. Liver 21 oz. Consistence normal, colour brownish, mottled all over with bright yellow points about the size of a pin's head. Spleen, 2½ oz., firm, red; kidneys, right 1⅜, left ¼ oz. Left, in condition of simple general atrophy; right, pale, mottled with yellow, and consists apparently of two pyramids with large inter-pyramidal cortex; subcapsular cortex thin; surface irregular but not granular. The unevenness of surface is coarsely irregular and yellow in colour. Pelvic viscera normal. Stomach of fair size; walls thick. On the lesser curvature are two ulcers, one about the size of a shilling, the other less than a three-

Digitized by Google

penny piece; the former is about one inch from the valve, and its floor consists of muscular fibres, and in part peritoneum only. The smaller one is seated on the pyloric ring and implicates the mucosa only. In the duodenum close to valve is a third ulcer about half the size of the last. All these have sharp punched-out edges. About six feet of the small intestine, chiefly upper ileum, are affected with ulcer-sloughs principally situated in Peyer's patches. The coats have sloughed in many of these places as far as the peritoneum, which forms the floor of the ulcers. Their colour is bright yellow, and they are surrounded by a zone of hyperæmic mucosa. There is one ulcer on the ileo-cæcal valve, but the lower part of the ileum is not affected, nor is the colon anywhere. There was no perforation, but outside the ulcers local peritonitis. There was no effort at repair. The mesenteric glands were enlarged.

April 2nd, 1889.

---

9. *Two cases of obstruction of small intestine by a ring formed by adhesion between contiguous appendices epiploicæ.*

By E. C. Perry, M.D.

These specimens illustrate what appears to be a very unusual form of intestinal obstruction. The notes of the cases are briefly as follows:

Case 1.—Ann H—, 48, married, was admitted on September 3rd, 1888, into Guy's Hospital under the care of Dr. Perry for acute abdominal pain and persistent vomiting. Her previous health was said to have been good. On August 29th she was suddenly seized with acute abdominal pain. She took two of Beecham's pills, which moved the bowels twice. Vomiting came on later in the day, and has continued up to admission (five days). A medical man who saw her on August 31st, ordered enemata, which brought away a little fæcal matter. She has passed nothing since, and the abdomen has increased in size since the onset of the symptoms.

On admission, the patient is collapsed, with abdominal face, is complaining of abdominal pain, and is constantly vomiting. The

Digitized by Google

vomit is yellow in colour, and is not stercoraceous. The abdomen is moderately distended, and somewhat tender to pressure. No tumour can be made out by manipulation, and examination *per rectum* detects only a few scybala. There is prolapse of the uterus, but no hernia. The pulse is 100 per minute and very small, and the temperature is 98·4°. The urine contained a trace of albumen.

Ether was administered, the stomach thoroughly washed out, and the usual incision made for laparotomy. The cæcum and large intestine were found to be collapsed, and two bands which were adherent to the abdominal wall on the left side were divided, but as the surgeon was not sure that the obstruction was due to them a coil of small intestine was stitched to the edges of the abdominal wound. A fine aspirator needle was then introduced through the external incision into the bowel, and a pint of yellow fluid like the vomit was withdrawn. The patient rallied slightly from the operation, and though no opium was given was free from pain. The following morning the pulse was hardly perceptible, and as there was still some distension of the abdomen the intestine was opened, but three hours later the patient died, twenty-four hours after the first operation.

Post-mortem inspection.—There was an incision about four inches long in the median line, beginning below the umbilicus, and around its edge a piece of small intestine had been firmly stitched. The abdominal wall was about an inch and a half thick, and the subcutaneous fat abundant. Further examination showed recent lymph on coils of intestine lying round the wound; and there was also lymph on the mesentery of most of the small intestine. The omentum was partly adherent to the anterior abdominal wall just above the symphysis pubis, and lying beneath the spleen was found a ligature including a small piece of omentum; the other ligature was not found. The stomach was moderately distended and contained about half a pint of yellow fluid similar to the vomit and intestinal contents. The duodenum and jejunum were also moderately congested and distended, but the congestion was nowhere extreme. The jejunum was found to have been opened four feet below the duodenum. Beyond this point the intestine preserved the same character of moderate congestion and distension to within nine inches of the ileo-cæcal valve, where a loop five or four inches long had slipped between two adjacent appendices epiploicæ which were united by fine thin adhesions at their tips. The pair of

Digitized by Google

appendices were situated ten inches from the lower end of the rectum, and lay about two inches to the left of the vertebral column at the level of the fifth lumbar vertebra. Beyond the loop was a length of four inches of empty ileum, and then was reached the ileo-cæcal valve and large intestine; the latter was small and contracted, but not entirely empty, for it contained a few hard scybala. The gut in the loop was obstructed, but not strangulated, for there was no mark of constriction upon it where it passed through the aperture formed by the adherent appendices. The pair of appendices adjacent to the pair which caused the obstruction were united by their edges.

There was a depressed pigmented scar on the inner side of the right thigh just above the knee, and extensive scarring behind the right knee. At the middle of the dorsum of the tongue was a deeply depressed cicatrix, and beneath it on section much fibroid tissue.

The lungs were slightly œdematous, with considerable areas of collapse; there was no vomit in the air-passages. The heart weighed 7·5 oz., and was healthy. The kidneys weighed 9 oz. and were very slightly granular. The liver, spleen, and adrenals were normal. There was prolapse of the uterus, the cervical canal of which was somewhat dilated and measured nearly two inches in length. At the fundus were two small intramural fibroids as large as peas, one of which was calcified. The ovaries and Fallopian tubes were normal.

Case 2.—Anne L—, aged 48, single, was admitted to Guy's Hospital, under the care of Dr. Pavy, at midnight, on October 19th, 1888. She was quite well until October 12th, when she had some pain in the abdomen. The next afternoon her bowels were freely opened, two hours after which she began to vomit and has continued to do so ever since. The medical man who was called in thought she had lead colic, the house having been recently painted throughout, and he therefore administered opium, calomel, and castor-oil enemata, but nothing succeeded in moving her bowels.

On admission the patient was collapsed, her face drawn, surface of the body cold, and the pulse almost imperceptible. The abdomen was slightly tumid, but without rigidity or local tenderness. The pain complained of was felt at the lower end of the sternum shooting through to the back. There was no visible peristalsis nor

Digitized by Google

any tumour to be felt, and the abdomen was uniformly resonant. Though the condition of the patient was desperate, operation was advised as giving the only chance of relief. Ether was administered and the usual median incision made. On passing his hand into the cavity of the pelvis, the surgeon felt what appeared to be a band low down on the left side. An attempt was made, by enlarging the incision, to bring the band into view, but this could not be done, and it was therefore torn through with the fingers. A piece of small intestine pulled up from the pelvis showed, upon its surface, a mark of recent constriction; below this point the gut was much contracted. The wound was closed, but the patient never rallied nor regained complete consciousness, and she died about two hours after the operation.

Post-mortem inspection.—On opening the abdomen the intestines were found distended, but there was no sign of peritonitis. Douglas's pouch contained about an ounce of blood-stained fluid. The large intestine was empty, except for a few scybala and some tenacious mucus, and the ileum was in a similar condition for the last forty-one inches above the ileo-cæcal valve. At this point the gut showed a transverse mark of constriction, and the next thirty-one inches were black and moderately distended; and then another pressure mark was seen, and two or three inches beyond it the bowel lost its dark colour, becoming dull red and more distended, a condition which continued throughout the rest of the intestinal tract. It was evident, therefore, that a large loop of ileum had been constricted and the passage of fæces through it obstructed. On slitting open the loop the mucous membrane was observed to be extremely congested, and the agminated and solitary glands were very prominent, but there was no ulceration and no sloughing, even at the ends of the loop where the pressure marks were found; in fact it appeared quite possible for repair to have taken place if the patient had survived the shock of the operation.

Careful search in the peritoneal cavity showed no band or other cause of obstruction still existing. The ovaries, tubes, broad ligament, uterus, mesentery, omentum, and vermiform appendix were minutely scrutinised, and nothing abnormal discovered. What was actually seen was a long mesenteric attachment to the sigmoid and upper part of the rectum, and about twelve inches from the lower end of the rectum on the left side, just below the brim of the pelvis a pair of appendices epiploicæ, with their adjacent sides

Digitized by Google

deeply congested, came into view, and their tips showed a rent in the serous covering as though they had been separated from each other. The case therefore seemed to have been one in which the tips of two adjacent appendices had become adherent to each other, and through the aperture thus formed a coil of intestine had slipped and become obstructed.

The stomach contained about a pint of black fluid resembling the contents of the intestine, and the same kind of material was found in the bronchi. The uterus contained a small intramural fibroid, and there were small cysts in the ovaries; the heart and other viscera were healthy.

So far as I can learn, it seems to be rare for intestinal obstruction to be occasioned by adherent appendices epiploicæ, and still more rare for it to be produced by appendices adherent to one another. Mr. Treves, in his monograph on intestinal obstruction, mentions only three cases in which the appendices were concerned; and since the date of his book a specimen taken from a girl aged 15, the subject of tubercular peritonitis, has been added to the College of Surgeons Museum (2691 A). In that case a band consisting of one of the appendices epiploicæ from the sigmoid passed to the mesentery, and beneath it a coil of ileum thirty inches in length became strangulated. The other cases are the following:—One reported by Mr. Hulke, in which an appendix epiploica from the sigmoid was adherent to the pelvic peritoneum near the right sciatic notch, forming a band beneath which a loop of bowel was strangulated; another of which the specimen is in the Museum of the College of Surgeons, where an appendix from the transverse colon became adherent to the great omentum in such a way as to produce obstruction of the part of the colon from which it arose; while the last case reported to this Society by Mr. Holmes[1] in 1861 almost exactly resembles the cases brought here this evening. It is described as an internal strangulation of the small intestine, near the ileo-cæcal valve, by the pressure of a ring formed, apparently, by the union of two contiguous appendices epiploicæ from the sigmoid flexure of the colon. Mr. Holmes remarks that the appendices were very long and broad, and that some of them were perforated at their base so as to present the incipient condition of such a ring as had embraced the intestine. There could therefore be little doubt, he thinks, that

[1] 'Trans. Path. Soc.,' xii, 211.

Digitized by Google

this ring was either a single appendix perforated at its base, and dilated by the passage of the gut through it, or formed by the union of two neighbouring appendices; and he concludes in favour of the latter hypothesis.

Possibly it may be a normal condition for appendices epiploicæ to be united along their adjacent edges. They may also become adherent by inflammation, and whether naturally coherent or cohering as the effect of inflammation the thin membrane which unites them may become perforated, and a piece of intestine find its way through the opening so made. On the other hand the tips only of the appendices may have become attached to each other as the result of a slight degree of adhesive peritonitis. As bearing on this point, I may remark that the adherent appendices sprung in each case from the sigmoid flexure of the colon, and were therefore in the immediate neighbourhood of the pelvis; that the specimens shown are from women, in one of whom the adhesion of the omentum to the anterior abdominal wall was good evidence of old peritonitis, and that in Mr. Holmes's case, where the patient was a man, he had suffered from a double inguinal hernia. It has been suggested that as small false diverticula may project into appendices epiploicæ, and are apt to lodge little fæcal masses and foreign matters of various kinds, inflammation might thus be set up in the pouch, and spread to the appendix, causing a limited peritonitis and an isolated adhesion. This explanation, though ingenious, will not apply to the present cases in which no distension diverticula are found. *November 20th*, 1888.

---

10. *On congenital abnormalities of the lower ileum.*

By Leopold Hudson.

[With Plate VI.]

I desire to draw the attention of the Society to some of the malformations of this part of the small intestine, and to show three specimens illustrating them.

The first (fig. 1) is one of a hammer-shaped Meckel's diverticulum, obtained from the body of a man aged 33, who was admitted into the Middlesex Hospital under the care of Dr. Douglas Powell

Digitized by Google

Digitized by Google

DESCRIPTION OF PLATE VI.

To illustrate Mr. Hudson's paper on Abnormalities of the Ileum. (Page 98.)

FIG. 1.—A Meckel's diverticulum terminating in a hammer-shaped dilatation, seen from its mesenteric aspect.

a. Small intestine.
b. Mesentery.
c. Mesentery of diverticulum.
d. Diverticulum.
e. Saccular eminences.

FIG. 2.—A Meckel's diverticulum, terminating in three rounded prominences. (After Lebert.)

a. Small intestine.
b. Diverticulum.
c. Saccular eminences.

FIG. 3.—Membranous diaphragm of crescentic shape in lower ileum.

a. Small intestine.
b. Slight external narrowing.
c. Crescent-shaped diaphragm, with small aperture.
d. Mesentery.

FIG. 4.—

a. Small intestine proximal to stricture.
b. Small intestine distal to stricture.
c. Mesentery.
d. Site of perforation.
e. Dilated gut, immediately distal to the stricture containing sessile polypi.

Digitized by Google

Fig. 2

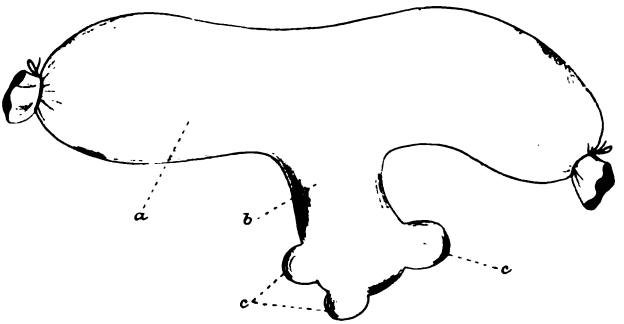

Fig. 1

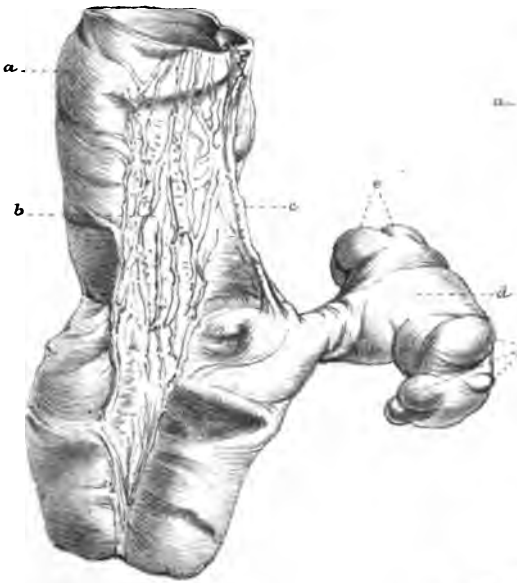

Fig. 3

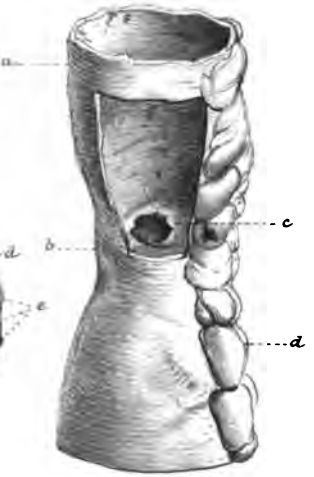

Fig. 4

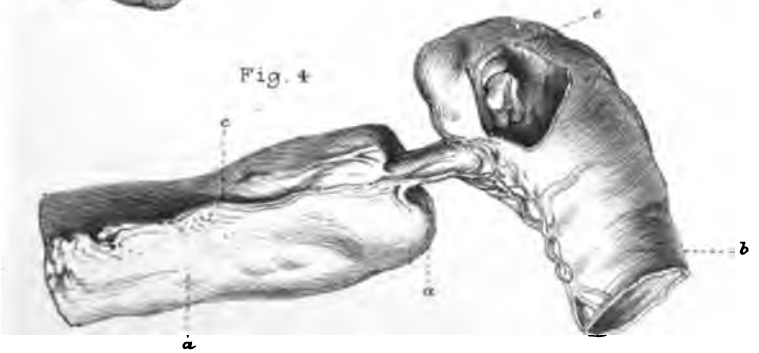

West, Newman lith

Digitized by Google

Digitized by Google

with typhoid fever, and died of peritonitis from perforation of the ileum seventeen inches above the ileo-cæcal valve.[1]

Projecting from the ileum exactly thirty-six inches above the valve is a diverticulum an inch and a quarter in length and presenting at its extremity two lateral groups of saccular dilatations, which take the form of small rounded knobs; collectively they measure transversely an inch and three quarters. The intestinal wall over these eminences does not appear to be thinner than elsewhere. The diverticulum communicates freely with the lumen of the gut, and along its side there runs a small fold of mesentery for a distance of two inches; this, when held to the light, shows linear traces of obliterated vessels, together with some pervious channels. The umbilicus is normal, and no other abnormal structures were discovered in the body. The specimen is shown as being an unusual form of a common malformation. Fig. 2 is a copy of an illustration of a very similar diverticulum from Lebou's work.

The second specimen was obtained from a man aged 62, who had been in the Middlesex Hospital under Dr. Cayley's care, and who died of fatty myocarditis and pulmonary emphysema.[2]

The ileum, thirty-six inches above the ileo-cæcal valve, is seen to present a slight external narrowing, and within, corresponding to this, is a crescent-shaped diaphragm, which possesses an aperture a quarter of an inch in diameter. The horns of the crescent closely approximate to one another, and the partial septum thus formed is thin and membranous (fig. 3). There is no external adhesion opposite to it, nor is there any sign of thickening or cicatrix in the investing peritoneum; the mucous membrane lining the tube at, as well as above and below, this stricture, presents perfectly normal characters. The intestine above is very slightly, if at all, dilated, and not hypertrophied, whilst that below is normal.

The third specimen, taken from a boy aged 8, who had likewise been under Dr. Cayley's care, is one of more marked stenosis of the gut. The patient was admitted with a history of long-standing abdominal illness, and died of perforative peritonitis.[3]

At the autopsy there was found, at a point thirty-eight inches above the ileo-cæcal valve, an intussusception which was obviously *post mortem*, being easily reduced, and showing no trace of adhesion

[1] *Vide* 'Middlesex Hospital, *Post-mortem* Reports,' 1888, No. 209.

[2] Ibid., No. 243.

[3] Ibid., No. 53.

Digitized by Google

or even roughening of the serous surfaces. When reduced the condition was found which is illustrated in fig. 4. The gut for three quarters of an inch is so strictured that it can barely admit a probe, and it has been formed at the expense of the part distal to the mesenteric attachment. The intestine proximal to this point is distended, its walls greatly hypertrophied, and its lumen filled with offensive, fluid, stercoraceous material. There is a minute perforation immediately proximal to the stricture, which has been the starting-point of the peritonitis. Immediately distal to the stricture the gut presents a small dilatation, and in this are found two sessile polypi; there is a third polypus twenty-eight inches, and a fourth eighteen inches from the valve, whilst a fifth, with a long, slender stalk, is attached to that structure itself. The intussusception before reduction measured three and a half inches in length, and its head was formed by the stricture, which had become invaginated into the gut distal to it. The mesenteric glands are quite normal, and there is no trace of old thickening or cicatrix in the peritoneum in the neighbourhood of the stricture. The mucous membrane in the gut proximal to the stricture presents a supple scar of a small healed ulcer, but this is situated half an inch from the commencement of the contraction. The viscera were all carefully examined, but presented no further sign of abnormality.

It appears to me that all these three specimens owe their cause to what Mr. Bland Sutton[1] has described as faulty coalescence. The abnormality existed in each at the same place, about a yard above the ileo-cæcal valve, and corresponding, therefore, in position with the site of the vitelline duct, which had undergone, in the first case, insufficient, and in the second and third excessive, closure

A sufficient number of specimens has been placed on record to enable a fairly complete pathological table of the congenital defects of this region to be drawn up, and they can be most conveniently divided into two groups, according to the embryological classification above suggested.

In the first group would be included (1) cases in which the ileum opens freely at the umbilicus, and the chief part of the evacuation of the bowels is discharged by this fistula. Many of these are on record, and some have been cured by plastic operation.

[1] Hunterian Lectures, "Evolution in Pathology," 'Lancet,' vol. i, 1888, p. 358.

Digitized by Google

(2) Cases with a small fistulous opening at the umbilicus, admitting a probe, and occasionally allowing the passage of fæces and flatus; the chief quantity, however, being passed *per vias naturales*. An instance is recorded by Mr. Bernard Pitts, where such an umbilical discharge commenced when the child was three weeks old, and ceased spontaneously at the age of seven years.[1]

(3) A tubular prolongation of the ileum connected with the umbilicus, either directly or by a longer or shorter fibrous cord. Instances of the former condition are related by Mr. Nathaniel Ward,[2] who found in a baker-boy an intestinal diverticulum, five inches in length, proceeding from the small gut, thirty-four inches from the cæcum, to the linea alba, about one inch below the umbilicus, and by Dr. Wilks,[3] who discovered in a girl aged 10 a diverticulum ilei, hollow from its origin at the gut to its termination as a blind end at the umbilicus. Examples of the condition in which the diverticulum is connected with the umbilicus by a cord are numerous, a particularly good specimen being in St. Bartholomew's Hospital museum.[4]

(4) A fibrous cord connecting otherwise normal intestine or mesentery with the umbilicus. Dr. Mahomed[5] relates a case where in a boy of 18, a fibrous band was found passing from the middle of the abdominal wall, midway between pubes and umbilicus, to the mesentery of the ileum, terminating in a large branch of the ileo-colic artery. The specimen was reported on by Messrs. Wood and Hulke, who considered it to be a persistent omphalo-mesenteric vessel. Mr. Treves, in his work on 'Intestinal Obstruction,' gives several instances of these diverticular ligaments.

(5) Meckel's diverticulum, of variable length and shape, either terminating in a rounded extremity or in the less common fashion illustrated by my first specimen.

(6) Slight saccular pouching of the intestine in this region. A good example of this exists in Guy's Hospital museum.[6]

In the second group would be included instances of excessive coalescence, which may be arranged as follows:

[1] 'Path. Soc. Trans.,' vol. xxxiii, p. 145.
[2] Ibid., vol. vii, p. 205.
[3] Ibid., vol. xvi, p. 126.
[4] Specimen No. 2168.
[5] 'Path. Soc. Trans.,' vol. xxvi, p. 117.
[6] Specimen No. 1819 (45).

Digitized by Google

(7) Slight constriction of the gut, with more or less obvious diminution of its calibre and but few consecutive changes above or below. My second case well illustrates this.

(8) Marked stricture causing secondary changes, due to distension of the gut above, and producing signs of obstruction. The third specimen I have shown is an example in point.

(9) Complete occlusion of the gut by a septum formed of mucous membrane, the muscular and serous coats remaining continuous. Mr. Davies-Colley [1] has placed on record the account of a dissection of a girl child, who died four days after birth, and in whom the small intestine was found much dilated down to about nine inches from the cæcum; here it became suddenly very small, the rest of the ileum and all the large intestine being much contracted and flattened. There was no band or diverticulum connected with the point of constriction. On opening the bowel it was found to be completely divided by a septum, lined with mucous membrane, thus forming two blind extremities, which overlapped each other for about a sixth of an inch. After referring to Theremin's paper,[2] in which seven instances of similar malformation of the lower ileum are related, Mr. Colley suggests that the position of the septum favours the supposition that it depends upon some abnormality in the obliteration of the ductus vitello-intestinalis.

(10) Complete solution of continuity of the ileum. Mr. Bland Sutton has met with such a case, and Dr. Hobson [3] gives the result of an autopsy on a premature male child, who died, aged 3 days, as follows: Sixteen inches above the cæcum was a break in the continuity of the small intestine, the bowel above and below ending off in a conical form, with no sign of a continuation between them; the gut above was expanded, while that below was much contracted.

The first four varieties I have enumerated, in which there is a connection between the intestine and the abdominal wall, deserve to be especially remembered from a surgical point of view, for they are a fertile source of intestinal obstruction. It will be observed that throughout these two groups there is a common pathological feature, defective closure of the vitelline duct; when this closure, with consecutive atrophy of accompanying structures has fallen

[1] 'Path. Soc. Trans.,' vol. xxix, p. 115.

[2] 'Deutsche Zeitschrift für Chirurgie,' 1877.

[3] 'Path. Soc. Trans.,' vol. xxxvi, p. 217.

Digitized by Google

short of the normal, then fistula, diverticulum or band results, but when, on the other hand, there is excessive closure, then stricture, septum, or complete solution of continuity is found.

February 19*th*, 1889.

---

11. *A case of columnar epithelioma of the ileo-cæcal valve, complicated by a post-cæcal abscess, and with secondary growths in the mesocolic glands, liver, and lungs.*

By Angel Money, M.D.

James P—, a married man, aged 60, was admitted under my care into University College Hospital on November 24th, 1888, and he died on December 4th, 1888.

He complained of violent pains in the right leg from the hip-joint to the knee, and of a gnawing pain in the right groin; he also alluded to the parched state of his mouth. He was very despondent and dyspeptic for twelve months three years ago. His mother died of epithelioma of the uterus at the age of sixty-five.

From 1856 to 1887 he was troubled with a skin disease, probably eczema. He had jaundice in 1852–53 for six weeks. He had "syphilis" at the age of eighteen years. Twelve months ago, he began to waste away, but his appetite was good; he has also lost sexual power for the same time. In June, 1888, after eating heartily at supper, he was awakened in the middle of the night with violent pains in the belly, and at 5 a.m. he vomited severely; the vomit was green coloured. Diarrhœa ensued and lasted two days. Whenever he takes solid food these symptoms repeat themselves. The pains in the right thigh began on November 1st, 1888, and have steadily increased in severity; he soon noticed a difficulty in turning over on his side; sleep was prevented by the pain, which was not, however, constant; he was rendered lame by these new symptoms.

On admission he was greatly emaciated; his temperature was 98·2°; he lay in bed on his right side; if on his back his knees were generally drawn up. The belly was retracted; a large vein passed from Poupart's ligament on the right side to the costal

Digitized by Google

margin. Pain, tenderness, and muscular rigidity were all noted in the right iliac fossa. The glands in both groins were palpable but not much enlarged. A large, hard, nodular mass, apparently fixed and continuous with the pelvic contents, was felt midway between the umbilicus and the right superior iliac spine.

Palpation of rectum detected a large cavity with smooth walls; just within reach of the index finger a nodular growth, as large as a haricot bean, attached to the right side of the pelvis, could be felt. The prostate gland was normal. Neither liver nor spleen could be felt. The liver dulness began at the seventh rib, and extended to the costal margin. The bowels were generally constipated; a stool passed on the 25th was semi-liquid, and well coloured with bile; a few scybalous nodules were also seen.

Patient could only take liquid food. The muscles were excessively irritable to percussion. The right femoral pulse was more prominent than natural at Poupart's ligament. Nothing noteworthy in the lungs or circulatory system or nervous system except signs of general debility. Tapping the sartorius muscle sent it into a tetanic condition. Pinching the ulnar nerve caused contraction of the flexors of the fingers and hands, just as if they were stimulated by an electric shock. Morphia was used to quell the pain. There was no albuminuria. The urea measured 2·8 per cent. Gaseous distension of the abdomen, retching and vomiting, griping pains, restless nights, drowsiness, diarrhœa of liquid stools of neutral reaction, and containing triple phosphates with few scybala, were the symptoms noted in hospital.

Autopsy.—Some adhesions in left pleura along vertebral groove. Two ounces of clear serum in pericardium. Peritoneum adherent to colon, and hard lumps felt therein. Omentum of a deeply stained yellow colour, puckered in many places, especially at free border; adherent to ascending colon by its right border, and also to the peritoneum behind. No ascites. The ileum and cæcum glued together by adhesions. Four gall-stones in the gall-bladder, which was adherent to hepatic flexure of colon. A puckered and scarred area existed in the right lobe of the liver, close to the longitudinal fissure. A large gland was seen on the side of the common bile-duct, which was dilated. The caput cæcum coli was so adherent to the iliac fossa that the bowel was torn in removing it; the segmoid flexure was drawn over to the right side and fastened to cæcum. The liver had two growths in its right lobe,

Digitized by Google

one at the surface and one in the interior, and its sections had a nutmeg appearance, like that seen in true heart disease. The heart was much wasted, flabby, and distinctly brown coloured.

A large abscess was laid bare behind the cæcum, and through it has bared nerves; it measured five inches by two and a half; the bone was not bare. A cancerous growth with congestion existed in the middle of the back of the right lower lobe; glands of root of lung not affected. No tubercles. Kidneys slightly granular on surface, and consistence a little increased; a few cysts in right kidney. Mesenteric glands were large and hard. Pancreas and other organs presented no cancer. Both segments of the ileo-cæcal valve were greatly thickened and congested, and also the part of the cæcum immediately adjacent, but not the ileum. The growth was microscoped; it was cylindrical epithelioma. The same characteristics were noted in the growth in the bowel, in that of the mesenteric glands, and in that of the liver.

February 5th, 1889.

---

12. *Two anomalous vermiform appendices.* (*Card specimen.*)

By Frederick Walker Mott, M.D.

Case 1.—J. T—, aged 51, who died of chronic Bright's disease. The cæcum was unusually small, and the vermiform appendix, as generally happens in such cases, of unusual length, measuring seven inches. It turned up behind the cæcum, forming a sigmoid band and terminated in a peculiar pouch one and a half inches long in the anterior part of the iliac fossa. This pouch has been described as the infra- or retro-cæcal fossa. Mr. Treves termed it the fossa iliaca subfascialis. There was apparently a small artery running along the pouch, and this would make me conform to Mr. Treves's opinion as being the correct one.

Case 2.—M. A. L—, aged 44, died after an operation for obstruction in the sigmoid flexure. She was found at the autopsy to have died from perforation of the cæcum and consequent peritonitis. The cæcum, although greatly distended, was much smaller than is usual in cases of obstruction of the large intestine, and there were

Digitized by Google

several perforations in its wall. The vermiform appendix measured seven and a quarter inches and turned up beneath the cæcum and the mesocolon crossing the second part of the duodenum, so that its tip rested on the front of the right kidney. It was fixed here by adhesions of old standing. When the vermiform appendix is long the cæcum is small, as a rule, consequently it is possible that in this case the perforation occurred owing to the cæcum being unusually small and therefore incapable of much distension. The wall of the cæcum where it was perforated was not thicker than writing-paper. *November 20th*, 1888.

---

13. *Perforated cæcum from a case of volvulus of sigmoid flexure. Vermiform appendix measuring seven inches.* (*Card specimen.*)

By Frederick Walker Mott, M.D.

The specimen was obtained from a woman who was admitted into Charing Cross Hospital for intestinal obstruction. Abdominal section was performed and the obstruction removed; the cæcum was not examined, and the woman died a few days after from peritonitis owing to the perforation. The vermiform appendix measured seven inches and took the following course: It first turned up behind the cæcum and mesocolon, then crossed the second part of the duodenum; finally it was firmly attached to the front of the right kidney by the tip. *March 6th*, 1889.

---

14. *Ulceration of the cæcum followed by almost complete occlusion of the ileo-cæcal valve.* (*Card specimen.*)

By Frederick Walker Mott, M.D.

Child, aged 4, suffered with diarrhœa since it was 8 months old. For a few months before death it suffered with all the symptoms of intestinal obstruction of a partial nature, vomiting,

Digitized by Google

peristaltic movements of the intestines with great distension and uncontrollable diarrhœa. The specimen shows the greatly distended ileum, and the small opening in the remains of the valvular opening. The vermiform appendix is matted on to the thickened cæcum, the mucous membrane of which is entirely destroyed by old ulceration, and if the two halves are closed up the lumen is seen to be almost abolished by the cicatrization.

May 20th, 1889.

---

15. *Ulceration of the cæcum, followed by almost complete occlusion of the cæcal valve.* (*Card specimen.*)

By Frederick Walker Mott, M.D.

J. W—, aged 4, admitted into Charing Cross Hospital January 24th, 1889, under Dr. Bruce. The friends gave the following history:

The child had suffered from attacks of diarrhœa since he was 8 months old.

The mother noticed a month ago that the stomach was larger than usual, and the child complained of pain, for which a doctor was called in. It was sick sometimes once, sometimes twice a day. The mother applied hot flannel, and the medicine which was ordered by the doctor was given to it. It had had no solid food for a month. The mother did not say the child had passed any blood in its motions.

Condition on admission.—Very considerable distension of the abdomen, with diarrhœa and vomiting. No physical signs in the lungs; temperature 100·6° Fahr. (above which it never rose while the patient was in hospital). Occasionally he looks free from pain, but there is an anxious pained expression of face generally, with considerable wasting of body. As the patient lies on the right side there is some dulness and slight fluctuation in right flank. If the abdomen be watched peristaltic movement of the intestine can be observed; this is accompanied by colicky pain. The appetite was variable; often the child was voracious. The patient was treated with various remedies to check the diarrhœa without much avail;

Digitized by Google

the vomiting and diarrhœa continued nevertheless. The patient remained in the hospital till April 1st, getting daily weaker, but without the diarrhœa in any way ceasing. It should be mentioned that at no time was any blood noticed in the stools. On April 28th the diarrhœa ceased and his condition became much worse. An enema of soap and water was given (half a pint); this brought away a considerable quantity of black fæces. After this Enema Opii was given, to relieve the child's pains. The patient had several attacks of convulsions, and died April 29th.

Autopsy.—Body emaciated. No disease of lungs or heart; abdomen small, intestines greatly distended, and especially at the lower part of the ileum. The vermiform appendix was found matted to the greatly thickened wall of the cæcum, and this part of the gut was evidently obstructed. On slitting up the intestine no ulceration was found until we came to the last Peyer's patch in the ileum; then it was discovered that the only communication between the ileum and the cæcum was a small hole not measuring more than a quarter of an inch in its longest diameter, and this aperture was blocked by a fleshy polypoid mass like a granulation. Whether this was the remains of the ileo-cæcal opening or a new hole, the result of ulceration, I cannot say. The whole of the wall of the cæcum is greatly thickened, quite three quarters of an inch thick in the upper part, and on slitting it up the bowel is seen to be greatly narrowed, not measuring more than two inches and a half in circumference. It is the seat of old ulceration for about five inches below the ileo-cæcal opening; the mucous membrane is quite destroyed, and stretching across longitudinally are fleshy processes very like the trabeculæ of the heart. It appears as if the ulceration had affected the whole cæcum, including the cæcal side of the ileo-cæcal valve. There were several caseous mesenteric glands, but no other sign of tubercular or scrofulous disease.

The process probably started when the child was 8 months old, by a chronic ulcerative process, which led to the chronic intestinal obstruction for which he was admitted. The case was difficult to diagnose, and the only diagnosis that was made by Dr. Bruce was chronic intestinal obstruction. It was fortunate that no operative measures were tried. *May 21st*, 1889.

Digitized by Google

Digitized by Google

Fig. A.



Fig. B.

Mintern Bros. lith

Digitized by Google

DESCRIPTION OF PLATE VII.

To illustrate Dr. Ormerod's case of Ulcerative Colitis. (Page 109.)

A. Colon (filled with horsehair) showing numerous perforations, one of them very extensive.

B. Interior of colon, showing:

(α) The commencement of the ulceration as small round points, with some larger ulcers in the neighbourhood.

(β) The transverse strings of tissue, undermined by ulceration.

Digitized by Google

Digitized by Google

16. *Ulcerative colitis with extensive perforation.*

By J. A. Ormerod, M.D.

[With Plate VII.]

The mounted specimen is from the descending colon and sigmoid flexure. It shows the extensive perforation that has taken place. Thus there is a large hole extending some five inches in the axis of the gut, and involving quite half its circumference; across it are stretch-strings of tissue, probably representing the circular muscular coat. There are other holes of various sizes, the smallest being the size of a large pin's head.

The ulceration, as seen from the inside, is very irregular; the mucous membrane forms patches and tags, and is often undermined so as to leave strings adherent at both ends. At some points an early stage may be seen, viz. small shallow ulcers with a sharp thin edge, sometimes undermined like a typhoid ulcer. The smallest of them are quite superficial, and no bigger than a large pin's head; they appear to spread both in depth and by a process of undermining at their periphery. Even when they have perforated the edges are still sharp, and there is practically no attempt at repair.

The *post-mortem* was made by Mr. Bowlby, who has kindly allowed me to utilise his account of it. A large quantity of liquid fæces were found in the peritoneal cavity; the small intestines were distended and slightly adherent by quite recent lymph. The front wall of the transverse colon was so completely destroyed that the inner surface lay open and exposed. The descending colon and upper part of the sigmoid flexure were also laid open, and the cæcum was perforated in several places. Thus the only parts of the bowel which were not laid widely open were the ascending colon, the splenic flexure, the lower part of the sigmoid flexure, and the rectum.

On removing the large intestine and opening it up the mucous membrane of the rectum was found to be destroyed over large areas, the remnants standing up from the ulcerated surface like small polypi. Five inches up the bowel this ulceration stopped, and then followed another five inches of normal mucous membrane; then commenced the small, sharp-cut, circular ulcers above described, scattered indiscriminately; these (passing further up) in-

Digitized by Google

creased in thickness and depth, assuming an oval shape transverse to the axis of the gut. Still further up irregular ulcers were formed by coalescence, but still with a tendency to be transverse. Finally the wide perforations appeared.

The small intestines, the mesenteric glands, and the other organs of the body were all perfectly healthy, the liver only being a little fatty. There was no tubercle anywhere.

The patient was under the care of Dr. Gee and Mr. Willett in St. Bartholomew's Hospital. She was a barmaid, aged 20, temperate, non-syphilitic, with a good personal and family history. She had always lived in England. For eighteen months she had complained of passing *per rectum* blood, and what appeared to be sloughs. During five weeks at the end of 1888 she was in Dr. Gee's female ward, her symptoms being pain in the abdomen and passage of blood *per rectum*.

On January 1st, 1889, Mr. Willett removed two small external piles; he also discovered and touched with the galvano-cautery an ulcer an inch and a half up the rectum. She did not improve. The temperature rose every night (on one occasion to 103·6°); diarrhœa began; tubercular ulceration of the large intestine was diagnosed.

On January 23rd symptoms of subacute peritonitis appeared, and she died, exhausted and emaciated, on the 29th.

May 7th, 1889.

---

17. *Two cases of cancer of the large intestine.*

By Raymond Johnson, M.B., B.S.

I am indebted to Mr. Marcus Beck for permission to exhibit these specimens.

Case 1.—Cancer of transverse colon, from a woman aged 64, under the care of Mr. Beck, at University College Hospital. The specimen consists of part of the transverse colon with a short piece of the lower ileum adherent to it. Surrounding the whole circumference of the colon in its right half for an extent of two inches is a ragged ulcerated growth, which has contracted the

Digitized by Google

lumen of the bowel to the size of the little finger. In the centre of the ulcerated surface an opening large enough to admit the little finger leads from the posterior part of the colon into the ileum, at a point five feet distant from its termination. The ileum is quite firmly united to the colon so that no leakage had occurred. On laying open the ileum, the fistulous opening in it is seen to be surrounded by an extension of the growth over an area the size of a penny. Examined microscopically, the growth has the characters of a columnar epithelioma. The spleen contained two wedge-shaped areas of deep congestion, and a similar patch was found in the right kidney. The base of the right lung was consolidated, and its pleural surface covered with inflammatory exudation.

The patient gave a history of gradually increasing distension of the abdomen for two years, with occasional dull pain at lower part, and obstinate constipation. On admission there was uniform tympanitic distension of the abdomen, with well-marked peristalsis in the coils of small intestine. No tumour could be felt either through the abdominal wall or by the rectum. Bowels acted only after enemata; no vomiting. The case was thought to be one of fæcal accumulation, with paralytic distension of the large intestine, and separation of the recti muscles. An abdominal belt was applied, and large enemata given with some relief. Three days before death diarrhœa set in, the motions being watery and pale yellow in colour. On the same day the temperature rose to 101°, and there was some dulness at both bases, with fine râles obscuring the breath-sounds. The specimen is interesting as showing the actual extension of the growth from one part of the gut to another, the two having been previously firmly cemented together by a local peritonitis. There can be no doubt that the colon and not the ileum was the starting-point of the disease, for the disease in it is much more extensive, and again, the history of the symptoms pointed strongly to obstruction of the large intestine. The character of the diarrhœa during the last few days of life can be explained by the passage of the liquid contents of the ileum through the fistulous opening into the colon. The character of the opening, however, points to a much longer duration. Possibly the opening itself, or the colon below it, was previously blocked by the masses of hard fæces which the enemata brought away. The immediate cause of death, as indicated by

Digitized by Google

the sudden onset of fever, the consolidation of the base of the right lung, and the recent infarctions in the spleen and right kidney, was probably septic absorption from the ulcerated surface of the growth.

Case 2.—Cancer of the cæcum. The specimen is from a female aged 50. It consists of the cæcum together with the termination of ileum and part of the ascending colon. The wall of the cæcum is infiltrated throughout with new growth; its cavity is much contracted, and is surrounded by the ulcerated inner surface of the growth, which in the recent state varied in colour from dark red to a dirty green. The wall of the cæcum is thickest above and around the ileo-cæcal opening, which is contracted to the size of a No. 8 catheter; its surface is in parts nodular from the extension of the growth under the peritoneum. The new growth terminates abruptly above at the junction of the cæcum with the ascending colon, the mucous membrane in this situation being much thickened and congested. Two inches and a half above the cæcum the colon has been opened by Amussat's operation. The lower part of the ileum is distended and thickened, but not involved in the growth. The vermiform appendix is healthy, and its opening into the cæcum pervious. A cancerous gland as large as a walnut lies on the inner side of the cæcum. The mesentery of the last few inches of the ileum is studded with nodules of new growth, varying in size from a millet seed to a pea. There was a small secondary deposit in the left lobe of the liver. The microscope shows the tumour to be a columnar epithelioma, although in many places the cells have almost lost their characteristic arrangement and shape, and almost completely fill the spaces in the abundant fibrous stroma. The patient had suffered from loss of flesh and pain in the lower part of the abdomen for six months; troublesome constipation for two months; occasional vomiting for three weeks; increasing distension of the abdomen for two weeks, the bowels only acting after enemata. On admission to University College Hospital on October 30th, 1888, there was uniform tympanitic distension of the abdomen, and visible peristalsis in the coils of intestine. In the right iliac fossa some ill-defined nodules could be felt. Nothing abnormal could be felt *per rectum* or *per vaginam*. On the twelfth day after admission Mr. Beck performed right lumbar colotomy, but the colon was not distended, and no fæces escaped on opening it. On passing the finger down-

Digitized by Google

wards in the gut a hard irregular mass was felt in the position of the cæcum, and a piece of large drainage-tube was introduced into an opening which could be felt in the centre of it. Two days later, no relief having followed the operation, the ileum was secured to the edges of an incision in the right linea semilunaris. Thirteen hours later the patient became collapsed, and was seized with severe abdominal pain. The gut was opened, and a considerable quantity of fæces escaped. She died collapsed twenty-one hours after the operation.

It is rarely that cancer affects this part of the intestine, and in recorded cases appears to be either limited to the ileo-cæcal valve, or, as in the present case, most advanced in that position. Mr. Treves, in his 'Intestinal Obstruction,' mentions only eight examples of stricture of the ileo-cæcal valve, five only of which were cancerous. Of 101 consecutive cases of cancer of the large intestine occcurring at University College Hospital, I find that the seat of the disease was as follows:—Rectum and sigmoid flexure 94, descending colon 1, splenic flexure 2, transverse colon 1, hepatic flexure 2, ileo-cæcal valve 1. In this last case the growth was a cauliflower-like excrescence limited to the valve, and formed the front of an intussusception which had reached as low as the middle of the sigmoid flexure. The specimen is in the museum of University College, and is figured in Mr. Treves's work.

The character of the symptoms in this case is interesting. Mr. Treves finds that stricture of the ileo-cæcal valve produces no distinctive symptoms, and that the latter are "practically identical with those associated with stenosis of the small intestine." In the present case, however, the symptoms pointed strongly to chronic obstruction of the large intestine, the pain was slight, and had no relation to the taking of food, and vomiting was only occasional during the latter half of the illness, and indeed for three days after admission, a fortnight before death the patient wss taking full diet, and no vomiting occurred. From the character of the symptoms, and the ill-defined nature of the mass felt in the right iliac fossa, it was hoped that right colotomy would relieve the obstruction. *February 5th*, 1889.

Digitized by Google

18. *Parts after Allingham's inguinal colotomy.* (*Card specimen.*)

By G. R. Turner.

The specimen shows the double-barreled appearance of the artificial anus, a very well-defined spur separating the upper from the lower opening. There is no prolapse, nor was there any during life, though the mesentery is by no means a short one.

The malignant disease of the rectum, for which the colotomy was performed in October, 1888, extends from within an inch and a half of the anus up to the top of the uterus; there is, however, no adhesive peritonitis. Secondary deposits in lungs, liver, and retroperitoneal glands. *April 16th*, 1889.

---

19. *Retro-cæcal hernia of the appendix cæci.* (*Card specimen.*)

By L. A. Dunn, M.B., B.S.

The specimen shows the cæcum (which has been stuffed out and turned up) and the portion of peritoneum upon which it lies (stretched out on wire); at the angle of reflection of the peritoneum, on to the cæcum, is seen pouch passing upwards and backwards, large enough to hold the top of the thumb one inch by half inch; this contains the appendix cæci coiled up, which is directed upwards and to the right.

The duodeno-jejunal fossa was unusually deep in the same subject, which came from the dissecting room at Guy's Hospital.

February 19th, 1889.

Digitized by Google

20. *Some hernial sacs and their contents.*

By C. B. Lockwood.

Mr. Lockwood showed a number of hernial sacs to illustrate peculiarities in the construction and contents of hernial sacs. Two of the specimens show conditions which predisposed to the formation of infantile herniæ. In one, which was obtained from an adult, the tunica vaginalis extended upwards, as far as the internal abdominal ring, where it was closed. Immediately behind the upper part there was a small peritoneal pouch, similar to, but smaller than, the true sac of an infantile hernia. The second specimen was of the same nature, except that the true hernial sac was longer, and inextricably confounded with the fibres of the internal cremaster; also, the lower part of the processus vaginalis in this case, had been shut off, to form a closed tunica vaginalis. An interesting point in the history of this specimen was that the infant from which it had been taken had been operated upon by Mr. Cripps, and the front sac—that formed by the upper part of the processus vaginalis—opened. No hernia was found, although some fluid was evacuated. The patient died, as it subsequently appeared, from an intussusception of the small intestines. In neither of these cases was any gut found in the hernial sac.

The first of these specimens illustrates one of the varieties of infantile hernia, that in which the processus vaginalis is closed, and in which the true hernial sac descends behind it. In a second variety, the true hernial sac also descends behind the processus vaginalis, but the latter remains patent, and in communication with the peritoneum. The second case illustrates a third variety in which the true hernial sac descends behind the processus vaginalis which, again, as in the first variety, is shut off from the peritoneum, but in which there is in addition a tunica vaginalis. There is also a fourth variety of infantile hernia which is the same as the last mentioned, but in which the upper part of the processus vaginalis retains its original communication with the peritoneum.

The next specimen was one in which there was a retroperitoneal hernia of the vermiform appendix into a retro-cæcal fossa, a large oblique inguinal hernial sac on the right side, and near it a large isolated peritoneal pouch above the tunica vaginalis; and by the

Digitized by Google

inner side of the hernial sac, and on the left side small acquired inguinal and femoral pouches. In this case when the abdomen was opened the vermiform appendix was quite out of sight, being completely hidden away in the fossa subcæcalis. The hernial sac was of the ordinary kind, but the extra blind sac seemed quite independent of it. There was no prolapse or elongation of the mesentery. The retroperitoneal hernia of the appendix had probably been produced by the descent of the cæcum, either during the course of development or during the displacement of the peritoneum, which accompanies the formation of large hernial sacs. The isolated sac is hard to account for, but probably was of the same nature as the sac of an encysted hydrocele. A very large plica vascularis ran upwards from the inner side of the mouth of the right hernial sac towards the mesentery, and lent support to the view that that hernia was of congenital origin.

Another specimen was shown in which the cæcum lay in the mouth of the sac of an inguinal hernia, and in which the vermiform appendix ran downwards, attached to the hinder wall of the hernial sac exactly opposite the spermatic vessels. The lower end of the vermiform appendix had a small mesentery. It seemed as if, in this case, the vermiform appendix had been dragged down in the formation of the sac, and the cæcum had followed; although it is to be remembered, that the gubernaculum might have displaced both the sac and the appendix. A ventral hernia, formed by the protrusion of an appendix epiploica, through the abdominal wall at the lower part of the left linea semilunaris was also shown. The appendix epiploica seemed to be enveloped by a thin layer of peritoneum, to which it was adherent. It was at first thought to be a mere subperitoneal lipoma. Its origin seems quite inexplicable. There was no external wound, and as the appendices appear late, it could hardly have been due to a developmental defect.

Finally, the sac of a femoral hernia was shown, which was extremely thin and contained a laminated calcareous mass, about one third of an inch in diameter. *November 20th*, 1888.

Digitized by Google

21. *Lumbar hernia.*

By J. HUTCHINSON, jun.

THIS is the first specimen of this variety of hernia as yet shown at the Pathological Society, and its rarity may therefore warrant me in going into some detail with regard to its anatomy. There have been singularly few dissections of lumbar hernia, and, so far as I can ascertain, this is the only one existing in the London museums. It was obtained, through the kindness of Dr. Stephen Mackenzie, from an elderly man who died in the London Hospital of cerebral disease. I need not enter here into the details of his condition, except as regards the hernia, which had existed for a considerable time, and which gave him but little trouble, since he was able to reduce the intestine by taxis with ease. The note made by the house physician some weeks before his death states that "there is a swelling in the left lumbar region about over Petit's triangle, which is soft and freely movable, and by pressure can be made to disappear. It is resonant on percussion and gurgles when reduced. Impulse on coughing. On removing the hand the swelling returns.

"There is no definite outline to the tumour, and no pain associated with it."

I was able to confirm this description by examination of the patient, the rapid increase in size when the patient coughed, the resonance of the tumour, and the ease with which reduction could be effected, proving that the hernia contained intestine. It is quite obvious from the specimen—and one of the most interesting points in connection with it—that every time reduction was made the sac of peritoneum must have returned with the intestine. At the *post-mortem* I examined as to this point, and found that it was easy by moderate pressure to push the peritoneal pouch into the centre of the fatty mass, the aperture allowing two fingers to enter it. Apart from the few cases of *reductio en masse* a reducible hernial sac is rarely met with in any of the ordinary positions at which ruptures occur. But occasionally it happens that with only moderate taxis both sac and intestine are pushed back into the abdominal cavity. In the lumbar region the peritoneum is much laxer in its attachments to the abdominal wall than in the inguinal and femoral

Digitized by Google

regions, no doubt to some extent owing to the constantly varying size of the colon and spleen, and it is fairly certain that a considerable amount of gliding movement or lateral displacement may take place during life of the peritoneum in this region. This looseness of its attachments is taken advantage of by surgeons during the operation of excision of the kidney through a lateral incision of the abdominal wall.

The size of the protrusion when the intestine was not present in its centre was roughly that of a goose's egg, measuring three inches vertically and two inches across. It was slightly lobulated, and lay in the subcutaneous tissue of the left loin, reaching from the iliac crest nearly to the last rib, and overlapping by its lower and front border Petit's triangle, which is well seen in the specimen. I may therefore be excused for having thought, when I examined the patient, that the protrusion was really through this triangle, whereas it was really above and to the inner side of it. The site of the aperture may be indicated by the accompanying woodcut. It

WOODCUT 2.

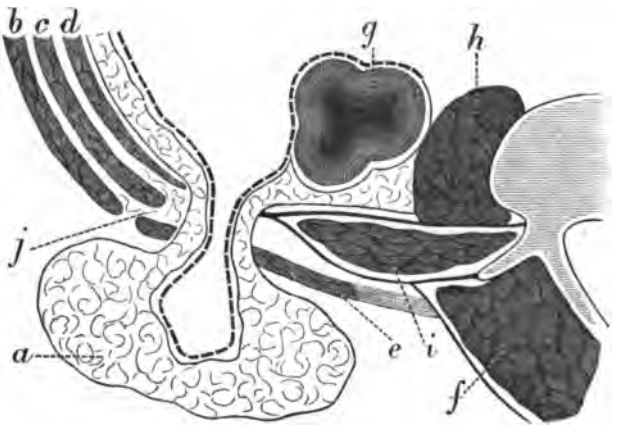

a. The hernia, wall of fat continuous with the sub-peritoneal layer. (The dotted line indicates the peritoneum.) *b*. External oblique muscle. *c*. Internal oblique. *d*. Transversalis. *e*. Latissimus dorsi. *f*. Erector spinæ. *g*. The colon. *h*. Psoas. *i*. Quadratus lumborum. *j*. Apex of Petit's triangle.

must be understood that after death the whole of the protrusion was composed of subperitoneal fat which had undergone local

Digitized by Google

hypertrophy. The man was rather emaciated, and this bore out what I found in several of the cases of fatty hernia in the inguinal and femoral regions,[1] that the adipose tissue was not present in excess except in the region of the hernia.

The methods of production of lumbar hernia are in some cases obvious enough, and are indicated in a series of cases which I collected and published in the 'British Medical Journal' of June, 1889. Sometimes the hernia develops in the track of a sinus or wound, sometimes the lumbar wall appears to be weakened by a severe sprain or contusion. But as to the origin of the cases of spontaneous lumbar hernia we are still in doubt, and I venture to think that in several of the recorded examples the original protrusion was formed of subperitoneal fat, which insinuated itself between the bands of aponeurosis. More than one case has for a time presented the features of a fatty tumour, the presence of intestine being recognised later. At any rate in the present case this method of formation cannot be questioned.

It was impossible to say at the *post-mortem* which part of intestine had been present in the hernia, though from its position it is very probable that the colon had, as has been suspected in several of the recorded cases.

It may be noted with regard to the relation of lumbar hernia to Petit's triangle that, owing to the close apposition of the external oblique and latissimus muscles, no such space exists in a fair proportion of adults (one in four males, according to Leshaft). The triangle is practically constant in females, but lumbar hernia does not occur so often in them as in men. Without doubting the occasional protrusion through the triangular space of a hernia, I venture to assert that the two are not in such constant relation as is generally supposed. *May 7th*, 1889.

[1] See 'Path. Trans.,' 1887.

Digitized by Google

22. *Ectopion of the cæcum with other malformations, and prolapse of intestine through the ileo-cæcal valve.*

By William Henry Battle.

E. M. T—, a female child, aged 12 hours, was admitted into St. Thomas's Hospital on June 27th, 1888, and died two days later.

The child, which was ill-developed, though supposed to have been born at the full time, presented a most unusual malformation of the abdomen in the middle line.

The recently ligatured stump of the umbilical cord was attached to the summit of a large hernial protrusion, which was not covered by skin, but tissue resembling that of the cord. Below this there was a transverse band of true skin, immediately below which a twisted finger-like protrusion, situated at the upper limit of a bulging, somewhat fiddle-shaped projection of mucous membrane, which extended to the symphysis pubis. Below the symphysis was a small red body of somewhat triangular shape, which could be pushed upwards along the vagina. There was no anus. The pelvis was small and ill developed, and no bone could be felt at the pubes. The mucous membrane referred to was somewhat congested and pitted, and there were evidences of incomplete transverse folds.

The finger-like projection was covered with vascular mucous membrane, and from an opening at its extremity feculent matter exuded, especially when the child strained, as it did a good deal; it appeared to be in pain.

During the course of the next hour or two this projection had much increased, soon became more than double its original length, and coiled in corkscrew curls; the child was crying and straining, and the protrusion became more and more dark and congested. As there was evident distress, and it was not possible to reduce the prolapsed intestine from without, I thought it better (having been requested by Sir W. Mac Cormac to act for him) to open the abdomen and reduce it by traction from within. An incision was made round the right side of the hernial protrusion a little beyond the edge of the skin, and the sac opened. It was found to contain

Digitized by Google

small intestine, one loop of which passed out of the abdomen at the base of the projection; by traction on this the whole of the protrusion was withdrawn, there being merely the opening of a mucous canal to indicate its site. The incision was then continued round the other side of the sac, and with the stump of the umbilical cord it was removed and vessels ligatured. It was considered better to close in the mucous surface below, so the skin margin was lightly pared, and after the opening of the bowel above had been sutured separately the sides were drawn together with silk sutures, as were those of the umbilical opening. No evidence of the presence of a bladder was seen, and though careful search was made for the ureteral openings none were found. The body which resembled uterus could be readily pushed above the pubes, but as readily returned through the vulva.

The temperature after the operation was 95°. On the 28th it rose to 100·2° at 8 p.m., and fell to 98·4° at midnight.

There was thin fæcal discharge from the bowel opening, and the child took milk well; there was no vomiting. The distension of the abdomen diminished, and there was no evidence of pain. It died suddenly at 5.15 am. on the 29th.

At the *post-mortem* examination, made by Dr. Hadden, which I do not give in full detail, there was found to be some recent peritonitis, the coils of small intestine being adherent one to another, and some of them highly congested. The large intestine was absent, excepting the cæcum and the upper part of the rectum; this latter was sausage-shaped, about three quarters of an inch in length, and ended in a *cul-de-sac* in the hollow of the sacrum; it was joined by a small pervious cord to the cæcum. No trace of the right kidney or ureter was found; the left kidney was large, and the ureter apparently of greater size than natural. The pelvis, calyces, ureter, and bladder contained a little fluid with yellow gritty material (urates). The bladder, which was very small, lay in front of the upper part of the rectum. Both adrenals were present and of a large size. In the upper part of the pelvis there was a central oval body, and on each side, passing from it, two impervious cords, which were attached to the tissues of the vulva on each side. This oval body had a minute cavity in its interior, and was probably a malformed uterus. The foramen ovale was patent. All the other organs were normal. There was a spinal meningocele of small size, and a deformity of the right foot, the foot being flexed and inverted.

Digitized by Google

The operation in this case was only undertaken as a palliative measure, to relieve pain and reduce the prolapse.

The rarity of this form of ectopion is shown by the fact that it is not alluded to in our text-books, nor in many of the works which deal specially with the subject of malformations.

Erichsen,[1] in his work on the 'Science and Practice of Surgery,' under the heading of "Absence of Anus, opening of Rectum into other Canals," says: "In a case in which I was once consulted there was imperforate anus and rectum, and the bowel protruded as a red fleshy tube, discharging meconium, and about four inches in length, from the anterior abdominal wall, just below the umbilicus, and immediately above an extroverted bladder."

Ahlfeld, in his 'Atlas,'[2] illustrates a somewhat similar condition, combined with extroversion of the bladder. In these the bladder is easily distinguished by the presence of the openings of the ureters on each side, and by the different markings of the mucous membrane exposed.

Much resembling those by Ahlfeld is an illustration in Förster's work, also entitled "Die Missbildungen des Menschen," Taf. xxii, No. 7. There was here malformation of the anterior abdominal wall and some of the abdominal organs, without evidence of the usual cloacal invagination of the surface at the anus, the large intestine ending below in a *cul-de-sac*. In this case the bladder was very minute, even if present. In the illustrations of this malformation by Ahlfeld and Förster the mucous membrane of the bladder is continuous with that of the cæcum; and the openings of the vermiform appendix, large intestine and ureters can be easily discerned on the surface of the protruding mass, whilst the small intestine projects through the ileo-cæcal valve like a finger. In this case also, with the exception of the ileo-cæcal opening, no orifice was visible on the mucous membrane, and the malformed uterus could be pushed up immediately behind the symphysis pubis in the position of the bladder. *May* 21*st*, 1889.

[1] Ninth edition, vol. ii, p. 916.

[2] 'Die Missbildungen des Menschen,' plate xxxiv, figs. 16 and 17.

Digitized by Google

23. *Diffuse calcification of the liver.*

By J. H. Targett, M.S.

James P—, aged 62, was admitted into the Devon and Exeter Hospital under the care of Dr. Davy on January 4th, 1884. His family history was good, and there was no evidence of any hereditary disease. He had always enjoyed good health until seventeen years ago, when for the first time in his life he was ill, and was treated in the hospital for "enlargement of the liver" and great pain in the epigastrium. He recovered and resumed his occupation (farm labourer), but ever since there has been a "tumour" in the epigastric region, which he could feel, but was not tender, nor the source of any inconvenience. He kept at his work till six months ago, when he began to suffer from occasional pain in the right side, which gradually grew worse. Six weeks before admission into the hospital he was found to be suffering from empyema in the right chest, and enlargement of the liver.

On admission patient is a tall, thin man, very feeble in his movements, with flushed cheeks, pulse strong, temperature normal. The epigastric, and upper part of the umbilical, region is occupied by a swelling of stony hardness, which moves up and down with respiration, and is apparently part of the liver. The surface feels uneven, though not distinctly nodular; no tenderness on pressure except at a spot one inch above the umbilicus, and just below the lower edge of the swelling. The anterior border of the liver can easily be felt under the ribs; it is thickened and unusually hard, but does not reach to the edge of the ribs. The body being thin, the fingers can be passed for nearly an inch between the ribs and the hard edge of the liver. Hepatic dulness in the right mammary line commences at the fifth space, and becomes absolute at the sixth rib. The veins over the upper part of the abdomen and lower part of the chest are enlarged and varicose. Heart normal. There is dulness over the back of the right chest below the angle of the scapula, and other signs of pleuritic effusion at the right base. Left chest normal. The angles of the ribs on the side are more prominent than on the left.

The right chest was aspirated and 7 oz. of thick pus withdrawn.

Digitized by Google

The temperature ranged from 98·4° to 99·4°, and the patient seemed to improve considerably.

January 28th (twelve days after aspiration), he had a rigor, and temperature rose to 101·6°, but it fell to normal next morning, and continued so till February 8th, when he was very ill, had a second rigor, and the the temperature went up to 104°. It continued high till February 10th, and then returned to normal. No cause was found to explain these rigors and pyrexia. The chest signs were improving, and the patient himself seemed much better than on admission. But when the pyrexia occurred he would get extremely ill, though each time he recovered under the use of brandy mixture.

From February 10th till April 1st the patient was so much stronger that he was able to be up and about the ward.

On April 1st, without any apparent cause, the temperature suddenly ran up to 104·4°; he became comatose, pulse 130, and remained unconscious till his death on April 4th. The temperature during these days was always high, the patient became slightly jaundiced, and there was a puffy swelling of the nose and face which quite altered his appearance (erysipelas?).

Autopsy made twenty-four hours after death.—On opening the abdomen a smooth white shining mass was found occupying the epigastric region, which proved to be the left lobe of the liver. The diaphragm was firmly adherent to the upper surface of the liver, and the adhesions contained vessels of considerable size. There were similar vascular adhesions between the omentum and liver; in fact, owing to the tough adhesions to all the neighbouring structures, the liver was with very great difficulty removed. The empyema on the right side extended from the fourth rib to the diaphragm; it contained a little thick pus, but there was no connection between it and the liver. Heart normal. Kidneys large and very much softened; their structure apparently normal. Spleen enlarged to four or five times its natural size, and was very soft. The liver weighed 66 oz. Its surface was everywhere rough from adhesions to surrounding parts. The left and Spigelian lobes were much enlarged, but there was very little increase in size of the whole organ. The capsule was much thickened, especially over the left border of the liver, where it measured one third of an inch in thickness. Sections of the organ could only be made with a saw. It was then found that the greater portion of the liver-substance was replaced by fibrous tissue, and this was uniformly infiltrated

Digitized by Google

with calcareous deposits. These deposits on section were hard, reddish-brown masses, irregular in shape and varying in size from a pin's head to areas three quarters of an inch in diameter. In the specimen exhibited the calcareous masses were so thickly aggregated at the right border of the liver that all trace of liver-substance had disappeared. There was much thickening about the portal fissure, and from it broad seams of fibrous tissue extended into the substance of the liver. The main vessels and ducts appeared normal.

Microscopical examination.—The liver was hardened in spirit, and the calcareous portions subsequently softened in lactic acid. The most affected parts consisted entirely of fibroid tissue, with a few spindle-cells and new vessels. The matrix of the decalcified portion was fibrous in structure, and was permeated with canals, which were no doubt vascular. There was no true osseous tissue. Sections from parts more healthy in appearance showed changes like those of monolobular cirrhosis, the lobules being surrounded by broad strands of fibrous tissue, in which were many groups of small round cells. One particularly noticeable point was the amount of new tissue in the centres of the lobules, spreading outwards between the rows of liver-cells, which were much atrophied from pressure. The small vessels were abundant and healthy. No evidence of parasites.

Chemical examination of the calcareous nodules showed that they were composed of phosphate and carbonate of lime and a large proportion of organic matter. No cholesterin or bile-acids.

Remarks.—Unfortunately the clinical report of this case is so incomplete that there is little beyond the naked-eye and microscopic characters of the liver upon which to found an opinion of its nature. The thickening of the capsule, together with the amount of fibrous tissue in the interior of the organ, are in favour of the primary change being syphilitic. But there is no caseation, nor the ordinary gummatous deposit, and very little of the contraction which syphilitic scar-tissue produces. I have been unable to find an account of such pathological changes as this specimen exhibits in any work on diseases of the liver, or in the Transactions of this Society. *April 16th*, 1889.

Report on Mr. Targett's case of calcification of liver.—The liver when handed to us had been preserved in spirit, and sections had

Digitized by Google

been made clean through it vertically from right to left. The length of these was eight and a half inches, the depth three and a half inches. The external and upper surface of the organ, to which a portion of the diaphragm was firmly adherent, was irregular and very hard, and in some places calcareous plates could be felt, quite superficially placed. The under surface presented a large round mass, squeezed off, as it were, from the rest of the organ; its surface was smooth and soft. On examining the sections of the organ the capsule, except over the prominence which has been mentioned, was found to be greatly thickened, and in many places calcareous masses lay in it close to the surface. From the latter inwards, to a minimum depth of one inch, and to a maximum depth of two inches and a half, extended tissues, which had taken the place of the true liver-substance. They consisted of a loose connective tissue with calcified masses, some reaching three quarters of an inch in length, embedded in it. They were not evenly distributed through the connective tissue, but in certain regions, where the latter was coarser than elsewhere, they too were aggregated more thickly. Towards the margins of the organ the whole section was occupied with this new tissue. Besides the thickened capsule and the deep zone of connective tissue and calcareous nodules, there existed liver-substance not grossly altered in appearance. In one section the latter occupied almost one third of the whole surface.

The specimen suggested an old inflammatory process, extending from without inwards, and presenting areas of greater and lesser intensity. The microscopical preparations which Mr. Targett had made were taken both from the region where the connective tissue and calcified masses predominated, and from the least altered parts of the organ. The former presented nothing but extensive, rather coarse, connective tissue, which was calcified in some parts of the section and not in others. There was no evidence of the formation of definite gummata or of any other characteristic pathological process, nor were there any traces left of hepatic structure.

The sections from that part of the organ which presented the least alterations to the naked eye showed extreme cirrhosis. The connective tissue was very dense for the most part, but in many places there was considerable infiltration of leucocytes. The connective-tissue strands sometimes surrounded several lobules, sometimes only one, and generally there was a very free growth of it within the lobules, which had given rise to atrophy of the liver-

Digitized by Google

Digitized by Google

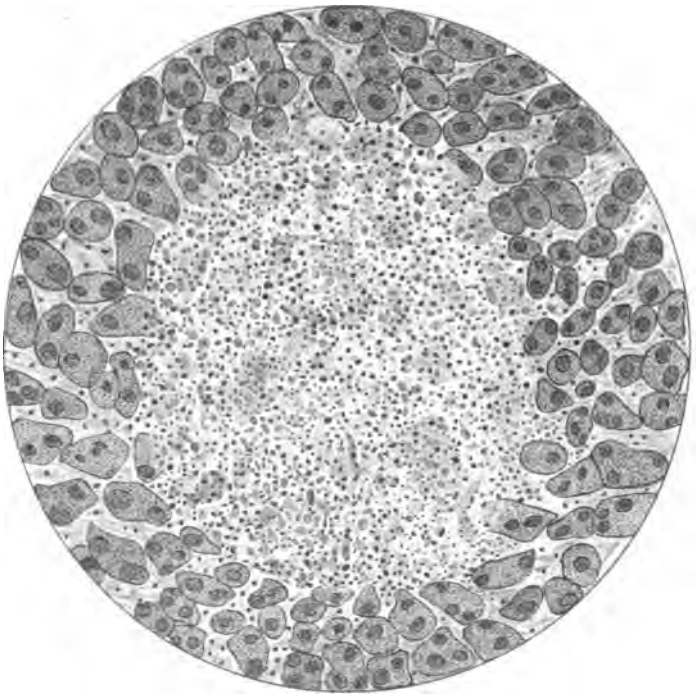

Fig 1

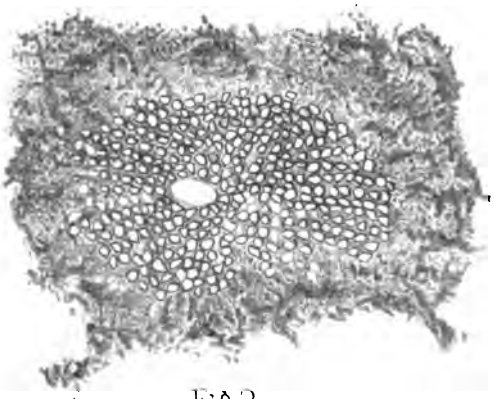

Fig 2

Digitized by Google

DESCRIPTION OF PLATE VIII.

FIG. 1.—To illustrate Dr. Handford's paper on the Liver in Enteric Fever. (Page 129.)

So-called lymphoma. The liver-cells have almost disappeared from the central area, which is occupied by a dense infiltration of small cells.

FIG. 2.—To illustrate Dr. Mott's paper upon Pernicious Anæmia. (Page 127.)

Section of the liver in pernicious anæmia, stained with ferrocyanide of potassium solution, rendered acid by HCl. The free iron has been converted into Prussian blue, and is seen for the most part in the portal zone.

Digitized by Google

Digitized by Google

cells. In some positions one found nothing more than a few isolated and atrophied liver-cells in the midst of connective tissue. There was no formation of new bile-ducts.

The case appears to us to be one of chronic perihepatitis, extending inwards along the connective-tissue framework of the liver. The widespread calcification of the connective tissue is, so far as we know, a very rare condition. One of us has published a case in the 'Transactions' of this Society (vol. xxxiv, p. 118) which in some respects resembles the present specimen, though the disease proved fatal at an earlier stage, and there was no calcification of the new connective tissue. In this case there was clear evidence, in the presence of small caseous islets, that syphilis was the cause of the affection. In Mr. Targett's case there is no such evidence, but we think, nevertheless, that it probably is of syphilitic origin.

SEYMOUR J. SHARKEY.
FREDERIC S. EVE.

---

24. *Free iron in the liver in pernicious anæmia.* (*Card specimen.*)

By FREDERICK WALKER MOTT, M.D.

[With Plate VIII.]

SECTIONS of the liver from two cases of pernicious anæmia occurring in males, aged 45 and 48 respectively.

The organs were hardened in alcohol, and sections were cut with the freezing microtome and then placed in a solution of ferrocyanide of potassium acidulated with hydrochloric acid. In a very few minutes the sections stained a deep blue colour as if they had been injected. Sections placed in solution of sulphocyanic acid stained a blood-red colour.

Microscopically the iron was seen in the form of blue granules (converted by the reagent into Prussian blue) in the cells and capillaries of the portal zone. In one case I have no clinical details, but the other is fully reported in the 'Lancet,' March 16th, 1889. The pathological significance of this free iron in the liver is to be found in the fact that, in all probability, pernicious anæmia is a

Digitized by Google

disease characterised by excessive destruction of red blood-corpuscles. This destruction is said to commence in the spleen, but it is possible that it may be the blood itself which is at fault, the hæmoglobin tending to separate from the corpuscles and pass in a free state into the plasma. Certainly many observers, C. J. Bond and others, have shown that in pernicious anæmia there is a tendency for the hæmoglobin to crystallize out. Given a certain amount of free hæmoglobin in the blood from excessive hæmolysis or dissolution of red corpuscles, the situation in which this hæmoglobin is changed will be the portal system. In health, we know that the liver is continuously forming bile-pigment from blood-pigment. It is said, moreover, that the plasma of the blood of the splenic vein contains a considerable amount of free hæmoglobin, and that this is converted into bile-pigment. The latter, however (bilirubin), is free from iron. If is probable that the blood may contain free hæmaglobin from the disintegration of corpuscles, which is decomposed in the portal circulation into free iron and a pigment. A fact which I have pointed out, and which one of these cases illustrates, supports this view, viz. that the urine in such cases is generally of a high colour. From this I am led to believe that the possible explanation of the pathology of the free iron in the liver is that the hæmoglobin is liberated from the corpuscles in the spleen, and perhaps elsewhere in the body, that it is taken to the liver, and by the action of the cells or some abnormal ferment decomposed, to form bilirubin or some other allied pigment, such as hydro-bilirubin, which contains no iron, this latter being left behind and accumulating as the disease progresses. The pigment escapes from the body as urobilin in the urine. This is supported by the observation of Caseneuve, who found that the urobilin is increased in all diseases, when there is an increased disintegration of red corpuscles. It may be, the peculiar lemon colour of the skin and canary yellow colour of the fat is, in some way, associated with the presence of free pigment in the blood. *February 5th*, 1889.

Digitized by Google

25. *Hepatitis in enteric fever.* (*Card specimen.*)

By H. Handford, M.D.

[With Plate VIII.]

Much interest has recently been excited by numerous cases of hepatic cirrhosis where no history of alcoholism, syphilis, or biliary obstruction could be traced. It is being shown that cirrhosis of the liver is not very uncommon in children and young adults. In some instances it is due to alcohol, little as it might be suspected; but there remains a considerable residuum in which no cause can be traced. Tubercle will not account for them, though in a few isolated cases it has been supposed to lead to cirrhosis of the liver. (I think it much more probable that in such cases there has been antecedent or coincident alcoholism.) It has been suggested that in a portion of this unexplained residuum scarlatina has been the etiological factor. I think I have good grounds for suggesting that enteric fever may also account for some of them. At least, I can say this, that after examining a considerable number of specimens during the past three years, I have found definite changes in the liver in the form of parenchymatous and interstitial hepatitis constant in all fatal cases. Of the pathological anatomy of the non-fatal cases we know nothing except by inference, but we may safely infer that the changes are the same in kind, though, as a rule, less in degree than in the fatal ones.

In 1872 Botkin (quoted by Thierfelder in 'Ziemssen's Cyclop.,' vol. ix) advanced the hypothesis that the acute infectious diseases may originate chronic inflammatory processes in the parenchymatous organs, because he had found in a number of cases commencing interstitial inflammation of the liver in persons dying of cholera or of typhoid fever.

And Klein, in 1877 ('Path. Soc. Trans.,' xxviii, 439), described an acute interstitial hepatitis as present in eight cases of scarlatina which he had examined.

Howard ('International Journal of the Medical Sciences,' October, 1887, p. 358) suggests that although "no instance has been recorded in which cirrhosis of the liver was shown to be a *direct*

Digitized by Google

sequence of scarlatina, cholera, or typhoid fever, yet, as it is established that in the kidney the poison of scarlet fever does frequently set up acute inflammation of the parenchyma and interstitial tissue which often becomes chronic, why may not the liver occasionally suffer a similar chronic inflammatory process?"

Cornil and Ranvier say, "In typhoid fever, in the middle or end of the second week, a state of softening of the liver is often observed." And elsewhere, "The liver and kidneys are almost invariably affected by parenchymatous inflammation."

Murchison says, "The liver is occasionally hyperæmic. . . . . The organ was softer than natural in thirty-two out of seventy-three cases examined by Louis, Jenner, and myself (Murchison). This softening is often associated with an indistinctness of the outlines of the lobules, while the microscope shows that the secreting cells are loaded with pigment and oil-granules, or are undergoing disintegration. In advanced stages of the disease Hoffmann has found many of the hepatic cells of large size and containing several nuclei. Frerichs has met with cases in which the liver was in a state of acute atrophy. Louis and Frerichs each record a case where the liver contained a number of circumscribed pyæmic deposits."

Clinically, I have never met with jaundice, marked tenderness to pressure over the hepatic region, or any definite symptom of derangement of the liver beyond a very variable degree of deficiency of bile in the stools. Enlargement of the liver is very inconstant. Though frequently present in older patients, it is generally not noticeable in younger ones.

Post mortem I have not found any constant naked-eye change. The softening described above has not attracted my attention, except perhaps in cases that have died of perforation where decomposition has advanced rapidly. But it is a change difficult to determine, and I am by no means prepared to say it is not present.[1]

The liver has been hardened for microscopic examination in Müller's fluid, in chromic acid solution, and afterwards in methylated spirit, and in absolute alcohol. By each process good results have been obtained. Sections have been cut after freezing and stained with logwood, picro-carmine, and alum-carmine. The latter has given much the best results.

[1] Most of the cases have been under my own care; for a few I am indebted to my colleagues. In all cases I have been present at the *post-mortem*.

Digitized by Google

In two cases marked fatty infiltration has been found: one a young woman, aged 23 and the other a lad aged 19. Possibly it was a mere coincidence, though no cause other than the long acute illness could be traced. It is also possible that the fatty infiltration of the liver was an indication of a previously feeble vitality which increased the probability of a fatal termination to the fever.

Pigmentary degeneration of the hepatic cells has usually been met with more or less, but in one instance to a very marked degree, general in distribution, and not confined to the region of the hepatic vein.

General, advanced, parenchymatous degeneration I have never found in some eight or ten cases examined. In all cases a majority of the liver-cells would stain sharply and well. A slight degree of diffuse parenchymatous degeneration is frequent. But the most characteristic change, though, so far as I have observed, not quite a constant one, is the presence of small rounded areas that stain imperfectly, that are infiltrated more or less thickly with leucocytes, and that are surrounded by a dense ring of cellular infiltration. The liver-cells in these rounded patches are in a state of cloudy swelling or have undergone more advanced degeneration. The margins of the cells are indistinct and the nuclei do not stain at all. In other similar patches, which I take to be in a more advanced stage, the liver-cells cannot be distinguished at all, the cellular infiltration is more dense and mingled with leucocytes are irregularly-shaped cells and spindle-cells. In fact, the tissue resembles the very early stage in the formation of cicatricial tissue. In yet a third variety there exist simply rounded aggregations of leucocytes, the smaller patches hardly distinguishable from commencing miliary tubercles, and the larger ones from the early stages of miliary abscesses. The two former I look upon as different stages of a process which probably owes its origin to capillary embolism or thrombosis, and the latter as a septic hepatitis due to the absorption of septic particles from the intestine. One or all of these three conditions have been described under the term *lymphoma,* among others by Fraenkel and Simmonds,[1] who have given a very imperfect illustration of it.

The question of the multiplication of the nuclei of the liver-cells which Hoffmann has observed is a difficult one. For in health many cells contain two nuclei, and unless the section is very uniformly

[1] 'Die aetiologische Bedeutung des Typhus Bacillus,' Hamburg, 1887.

Digitized by Google

only one cell thick, the nuclei of underlying cells are apt to be attributed to the cells lying above. But after long examination of many sections I believe that multiplication of the nuclei does occur.

The most constant and perhaps the most important change is interstitial hepatitis. I have found it present in some degree in every instance. From being of such recent origin it has not passed the cellular stage, and no increase of fibrous tissue is found. It consists of a rich cellular infiltration, chiefly along the lines of the blood-vessels, especially the portal group (hepatic artery and portal vein); but it also manifests itself both as a scattered infiltration and in the form of dense groups of small cells amongst the liver parenchyma. I have found it to a most marked extent in a boy of 10, and in a lad of 19. This, together with its constancy, would show that it is not an accidental, coincident cirrhosis. Notwithstanding the descriptions of Koch, Eberth, Gaffky, and Fraenkel and Simmonds, I am not satisfied that any specific typhoid bacillus has yet been found. Should one be demonstrated beyond all question, it is not unlikely that it may be shown to be the cause likewise of these forms of hepatitis. In the absence of that, however, one can only suggest as the cause the absorption of ptomaines from the diseased intestine, or of some septic organism that produces irritation, but does not lead to suppuration and abscess.

In conclusion, I would repeat that well-marked and characteristic changes, both parenchymatous and interstitial, are constantly found in the liver in enteric fever; but that there is no evidence to show whether they may go on to the production of cirrhosis, though it may be inferred that in some cases they do.

Microscopic sections, illustrating all the appearances described, were shown at the meeting. *May* 21*st*, 1889.

Digitized by Google

26. *Syphilitic liver, in which the left lobe is much larger than the right.* (*Card specimen.*)

By FRANK PENROSE, M.D.

THE liver was taken from a man aged 42, who was admitted into St. George's Hospital under Dr. Cavafy on December 19th, 1888, for cirrhosis of liver and ascites, and for bronchitis and laryngitis.

On admission he gave a history of syphilis eighteen years previously, also of having been a heavy beer drinker. Ten days after admission pericardial friction was heard. Shortly after this the ascites generally increased, he got abdominal pain and intractable diarrhœa, and died March 10th, 1889.

The interest of the specimen is in the inequality in size between the right and left lobes of the organ, the latter being so much larger than the former. During life the liver was noticed to be enlarged, but no stress was laid upon the inequality of the two lobes. *March 19th*, 1889.

---

27. *Internal rupture of liver.* (*Card specimen.*)

By J. H. TARGETT, M.B., M.S.

HISTORY.—Eliza D—, aged 7½. Was knocked down and run over by a van, the wheel of which passed between the legs, and obliquely across the abdomen to the right hypochondriac region. Some vomiting the next day. Temperature rose to 106° at death, which occurred forty hours after admission.

Post-mortem.—Separation of symphysis pubis and laceration of vagina. No hæmorrhage or effusion into the peritoneal cavity. On the under surface of right lobe of liver, near its posterior border, was a sausage-shaped collection of blood or hæmatoma. It was entirely subcapsular, there being no laceration of the peritoneal coat anywhere. On section the liver-substance showed a great number of large hæmorrhages from laceration of its

Digitized by Google

structure, and many of these followed the course of vessels in the portal fissures. With the exception of the hæmatoma above described there was nothing on the surface of the liver to suggest the condition found on section. Other viscera normal. No fracture of ribs or spine.

A similar case recorded in 'Trans. Path. Soc.,' 1886, p. 266.

November 6th, 1888.

---

28. *A case of cirrhosis of the liver, probably originating in phlebitis of the portal vein.*

By JAMES F. GOODHART, M.D.

THIS case, of which microscopical sections are shown, is interesting from its history. I cannot say that the histological appearances are other than those of an ordinary cirrhosis. The specimen came from a young married lady of 21 years. She has been known all her life by Mr. Hooper, her medical attendant, and he is certain that neither alcohol nor syphilis have anything to do with the disease. She had always had good health. I pressed her upon the question of ague and every other malady I could think of of importance, and she had suffered from none. She had married eighteen months before I saw her, and six months later "she had a bad miscarriage at about three months, followed by slight septic poisoning with pyrexia for a few days, which yielded to intra-uterine injections of perchloride of mercury." I now quote from Mr. Hooper's very lucid report. "She did not again come under my notice till eight months later. She got fairly well again, but ever afterwards felt sick, and this at all times, not after food. In May, 1888, she suddenly vomited an enormous quantity of blood, and for a week her life was despaired of; she, however, rallied from the urgent symptoms, and jaundice and ascites followed, and on the then examination of the abdomen a very large spleen was found occupying the epigastric and left hypochondriac regions, and the area of liver dulness was considerably diminished. Under treatment the ascites slowly diminished, and the splenic enlargement somewhat." I saw her in October, 1888. The ascites and

Digitized by Google

jaundice were now no more, but there was a large spleen extending well over into the epigastrium, and unless some of it were liver there was no hepatic dulness of any kind.

I was rather disposed to think that there had been some old disease shrivelling up the right lobe of the liver, and that what Mr. Hooper considered spleen might be hypertrophied left lobe of liver and spleen, and with the history of septic troubles and hæmatemesis, jaundice, and ascites, I was inclined to guess at some gastric ulcer with portal thrombosis. The case was very obscure. She was subsequently seen by a distinguished surgeon in the Midland Counties, who suggested a hydatid of the left lobe of the liver, and advised operation. She went on after this for some eight months, that is, for nineteen months after her miscarriage. She improved in health, gained in weight, and seemed to be slowly progressing, when she suddenly had another violent attack of hæmatemesis, under which the splenic tumour shrank back into the left hypochondrium, and from this she succumbed.

The *post-mortem* examination showed nothing but cirrhosis of the liver and a swollen spleen. The stomach was quite healthy, but the liver was reduced to about half its natural size, and was a well-marked specimen of an extreme hobnail liver. It was pale, very tough, and seamed throughout by fibrous bands. The portal vein trunk was not examined.

I bring the case forward, in the absence of any probability either of an alcoholic or syphilitic cause, as one possibly dependent upon some clotting in the portal vein, and dating from her miscarriage. It seems a reasonable hypothesis, and one that my colleague, Dr. Wooldridge, will, at all events, have no difficulty in accepting as true, but I cannot say that there is anything more than circumstantial evidence. The microscopic specimens I have submitted to my colleague, Dr. Perry, and I believe Mr. Targett also has seen them, and they are unable to say that there is anything peculiar or exceptional in the nature of the cirrhosis. To my thought, possibly a biassed one, that there might be perhaps, and particularly in the spleen, some undue thickening of the walls of the branches of the veins, but I have a further object in bringing the case forward, and that is to say how rare in my opinion it is in its departure from the common modes of production by alcohol and syphilis. In the present day we hear of all sorts of causes of cirrhosis: there is the biliary cirrhosis, the cirrhosis due to tubercle, to heart disease,

Digitized by Google

to malaria, and so on; but I believe all these descriptions arise from a confusion between patches of cellular proliferation as seen by the microscope and naked-eye or bedside cirrhosis,—two very different things; and I venture to assert, upon the strength of thirteen years in the *post-mortem* room at Guy's, that bedside cirrhosis, other than due to alcohol, or syphilis—and alcohol much more often than syphilis—is so rare that I could not bring forward more than two or three cases. *April 16th*, 1889.

P.S.—I am, however, prepared to concur in the remarks made at the meeting at which the specimen was exhibited by the President and Dr. Crooke that as regards the cirrhosis of childhood there is enough uncertainty about some cases to make it probable that there is yet more to be learnt about it, and that some of the exanthemata originate histological changes which may quite possibly lead up to a confirmed cirrhosis. But it has never yet been possible to trace the disease from a source of this kind.

---

29. *Cirrhosis of liver in a child.* (*Card specimen.*)

By J. H. Targett, M.B., M.S.

History.—George G—, 8 years, was admitted into hospital in a very collapsed state, having been kicked in the abdomen by a horse. He died in a few hours.

Autopsy.—Extensive ruptures in the spleen; the peritoneal cavity contained 36 oz. of blood. Liver weighed 30 oz. Its surface had a typical hobnailed appearance, and on section the strands of fibrous tissue, dividing the liver-substance into areas, were well marked. It was not so tough as the ordinary cirrhotic liver of the adult, nor was it bile-stained. All the other viscera were healthy. The spleen when freed from blood-clot weighed 10½ oz.

Microscopically the structure of the liver was that of a multilobular cirrhosis. There was an abundance of richly cellular tissue surrounding two or more hepatic lobules, and the older portions of this tissue had already become fibrous. There were no intralobular changes, and no evidences of syphilis or tubercle.

The only history that could be obtained was to the effect that the patient was an illegitimate child, and worked as an errand boy for stablemen. *December 4th*, 1888.

Digitized by Google

30. *Pericellular cirrhosis of liver?* (*Card specimen.*)

By J. A. Ormerod, M.D.

The hepatic cells are seen as scattered, irregularly-shaped bodies, embedded in what appears to be a finely fibrillated connective tissue. This latter is uniformly distributed, and not in any way limited to the area of the portal vein.

From an infant aged 6 months, under Dr. Boodle, of Cirencester, who also made the *post-mortem*. No suspicion of stroma or syphilis in parents. Mother was weakly, but suckled the child. Child died of progressive asthenia, accompanied by enlargement of abdomen of two months' duration.

Post-mortem.—Liver reached half way between umbilicus and pubes; was pale, firm, smooth; on section presented a uniform lemon-yellow colour; no trace of normal liver structure seen. No iodine reaction. A little thin pale fluid in gall-bladder.

Slight localised peritonitis between spleen and diaphragm. Kidneys very pale; normal under microscope. Nothing abnormal in the organs. *April 16th*, 1889.

---

31. *Primary carcinoma of liver.* (*Card specimen.*)

By Leopold Hudson.

The liver weighs 225½ oz., and was removed from the body of a woman 53 years of age, under the care of Dr. Coupland, in the Middlesex Hospital.

The primary malignant mass was situated in the extreme left lower part of the right lobe, abutting on the ligamentum teres, and was as large as a closed fist. Numerous secondary growths of various sizes were distributed throughout both lobes. There were also secondary deposits in right lung, left kidney, and glands of small omentum. The body was very obese and jaundiced, the lungs engorged and œdematous, and the heart dilated and fatty.

November 6th, 1888.

Digitized by Google

32. *Melanotic sarcoma of liver.*

By NORMAN MOORE, M.D.

A SECTION through a liver which has been enormously enlarged by the infiltration of a melanotic sarcoma. The entire liver weighed sixteen pounds when removed from the body. The section shows large nodules of a black colour and circular in outline, which are separated from each other by strong white septa. In some parts the growth is diffuse and of a grey colour, but nowhere can any trace of liver-tissue be discerned.

Similar growths were found in the mesenteric glands and in both kidneys.

The peritoneum showed numerous minute specks of the same growth, and there was one in the skin of the left axilla of pin-head size. There was no new growth within the chest and none in the spleen.

From a printer's warehouseman, aged 48, who was under my care in St. Bartholomew's Hospital; his father died from a tumour. He himself had suffered for many years from indigestion and constipation. Three years before admission his right eye was removed on account of a melanotic tissue growing from the choroid. Four months before his death he had pain in the right side of his abdomen, accompanied by nausea and retching, and in three months he lost a stone in weight. During life the liver dulness reached as high as the fifth rib, and his abdomen was occupied by a hard tumour which extended almost as far as Poupart's ligament on the right side, whilst on the left side it reached the level of the anterior superior spine of the ilium. His temperature was never raised.

The case is interesting as an example of the duration of this form of growth.

Sir William Lawrence described a case in which, three years after removal of a similar growth in the eye, the sarcoma recurred in the liver and pancreas; and another case in which he operated illustrates also the frequency with which these growths occur in the liver. *March 19th*, 1888.

Digitized by Google

33. *Tubercular excavation of liver.* (*Card specimen.*)

By F. Wethered, M.D.

The specimen was removed from a man aged 21, who was in the Victoria Park Chest Hospital, under the care of Dr. Thorowgood. His illness commenced with slight cough, dyspnœa, loss of flesh, and night sweats, his family history being free from phthisis, and his previous health good. While in the hospital his temperature was persistently high, he complained of no pain, his cough was very slight and expectoration scanty. The liver dulness reached from just below the right nipple to three fingers' breadth below the costal margin; there was some tenderness; râles were heard over both lungs. The patient gradually sank from asthenia, after an illness of five months.

After death the liver was found to weigh 64 oz. It was firmly adherent to the diaphragm and surrounding parts. The capsule was much thickened, and the surface studded with small white granules, the largest of which was about the size of a pea. On slicing the organ it was found to contain similar nodules; the smallest of these were solid, but the larger ones soft in the centre and stained a light green. Some of these caseous abscesses were as large as a chestnut, they had thick uneven walls and were filled with semi-fluid caseous débris coloured a deep green. The bile-ducts were patent, but no communication between them and the cavities could be made out. Sections exhibited a typical tubercular structure, and tubercle bacilli were found in them.

There was a considerable extent of peritonitis, especially on the right side of the abdomen. The mesenteric glands were enlarged, those about the crura of the diaphragm being caseous. Recent miliary tubercle was found in both lungs, but there were no signs of old mischief.

This condition, though rarely met with in the adult, is, in less degree, comparatively common in children. In them, as in the present case, there was evidence of general tuberculosis of more recent date, but no older lesions. The case is apparently one of primary tuberculosis of the liver. Microscopic specimens are shown. *May 7th*, 1889.

Digitized by Google

34. *Carcinoma of gall-bladder and bile-duct. (Card specimen.)*

By J. Griffiths, M.B.

Considerable thickening of walls of gall-bladder, and thickening, with narrowing of bile-duct, just above the entrance into it of the cystic duct. In structure it is an ordinary carcinoma. The patient suffered from jaundice, dyspeptic symptoms, clay-coloured stools, and delirium a few days before death.

February 5th, 1889.

---

35. *A case of primary cancer of the pancreas causing biliary obstruction.*

By W. Henry Kesteven.

Patient, a male aged 60 years, engaged in commercial pursuits. He was a temperate man and had passed a healthy life. Nine months previous to his death he was attacked with jaundice, preceded by severe abdominal pain. The symptoms which were noticed during his illness were briefly as follow. Hepatic dulness much extended, but varying in extent, at one time reaching the umbilicus, but never diminishing to more than an inch and a half above that level. The dulness extended laterally over the left hypochondrium and fairly over the edge of the left lumbar region. There were several recurrences of the abdominal pain, occasionally a tendency to diarrhœa, the motions being the colour of wet modelling clay. The jaundice was persistent, the urine always deeply stained with bile, but generally normal otherwise, with the exception of a short period, two months after the commencement of the illness, when it was suddenly found to contain large quantities of sugar. This, however, quickly yielded to dietetic treatment. The presence of the sugar was accompanied by an increased dryness of the skin, and thirst.

Digitized by Google

About ten weeks before his death albumen first made its appearance in the urine, though only in small quantities, and remained until the end. There were, however, no casts discoverable.

Dryness of the skin to a more or less extent was present throughout, the skin at times enfoliating in flakes. Constant crops of pustules and extreme irritation of the skin, were the cause of much trouble until allayed with sodium bicarbonate in solution with glycerine.

Hæmorrhoids became very large and painful, and were relieved by subcutaneous injection of carbolic acid and glycerine.

He had a severe attack of abdominal pain about six weeks before his death, and a day or so after this the gall-bladder became perceptible below the edge of the liver; it had not been so previously. Thereafter it slightly increased in size, but not in tenseness. Twenty-four hours before his death the motions resumed the normal colour, or a close approach thereto, being deeply stained with bile. At one time he had a sharp attack of pleurisy on the left side, affecting the whole of the posterior aspect of the pleura. A fortnight before his death he developed a large elliptically-shaped superficial abscess at the lower margin of the left axilla, which showed a tendency to spread over the scapular region. Probably this was simply another indication of the interference with the nutrition of the skin, shown also by the dryness and irritation mentioned above.

Post-mortem examination twenty-seven hours after death.—The body much wasted, the skin all over of a deep brownish-yellow colour. The wound where the abscess had been lanced was gaping and dry; there were large hæmorrhoids. Absence of fatty matter beneath the skin; costal cartilages ossified; heart normal, valves bile stained. Left lung closely adherent to the costal pleura all over. Right lung normal; liver much enlarged, reaching to about one inch of the umbilicus.

Gall-bladder protruding an inch below the lower edge of the liver. On raising the liver, the gall-bladder was found to be considerably distended, measuring about four inches in the vertical and two inches in the transverse diameter. It contained a clear straw-coloured fluid. The hepatic duct, and the common duct were dilated to the size of a forefinger; the cystic duct was also dilated, but not to the same extent, as though it had not been so long subjected to the action of the distending force. The hepatic

Digitized by Google

and common duct formed one continuous uniform tube. On tracing this to the duodenum it was lost in a hardened, but not much enlarged, head of the pancreas.

The common duct, the mass above described, and a small portion of the intestine were dissected out and removed for further examination. This showed that the common duct and the pancreatic duct were both apparently obliterated by the growth in the head of the pancreas, but upon laying the duct open, and tracing it carefully with a small director, it was found to be pervious, and to allow the passage of the director into the duodenum.

The kidneys were deeply congested, and bile stained. The intestines and the spleen seemed normal.

The mesenteric glands were also healthy, nor could any trace of hyperplasia be elsewhere detected. Microscopical examination of the growth in the head of the pancreas showed that it was carcinoma.

This case presents two or three points of interest.

First, it shows the difficulty of deciding, during life, as to the nature of such an obstruction to the flow of the bile, and consequently the difficulty in coming to a decision as to operative interference in such cases. Dr. George Harley has lately published[1] a most valuable paper in which he indicates the signs by which obstructions to the biliary stream may be localised, and these indications are well illustrated in this case. But it also shows that something more than localisaton is necessary before operative interference can be decided upon. The hardened head of the pancreas was not detected, or suspected during life nor was it detectable as the liver masked it completely, and it was a matter of congratulation, when the cause of the obstruction was discovered, that abdominal section had not been performed during the life of the patient. The only thing that could have been done would have been to make a communication between the gall-bladder and the duodenum (cholecystotomy), and this could only have been palliative even if the patient had survived the operation.

Secondly, the case proves that cancer may exist primarily in the pancreas. This I am informed by Dr. Wilks was in times past a matter of dispute, but several cases have now been published,

[1] 'Illustrated Medical Times,' October, 1888.

Digitized by Google

among others three by Dr. Norman Moore in the seventeenth volume of 'St. Bartholomew's Hospital Reports,' and one by Dr. Kidd in the 'Pathological Society's Transactions' for 1883.

Finally, may not the diabetic symptoms which made their appearance during the illness be of some significance as bearing on the question, which has lately been mooted, of the connection of the pancreas with that disease? *November 20th*, 1888.

Digitized by Google

V. DISEASES, ETC., OF THE GENITO-URINARY ORGANS.

1. *Kidney from a case in which albuminuria was hereditary.*

By W. H. Dickinson, M.D.

[With Plates IX and X.]

I propose to bring before the Society a kidney which has especial, and I may say in one respect unique interest, for it is the only one which, so far as I know, has been minutely examined of those belonging to a family in which albuminuria has been hereditary certainly for four generations. I will briefly sketch the morbid pedigree so far as I have been made acquainted with it. Some of the persons referred to have been under my own observation; as to the rest, I have been indebted for information to other members of the family and to their medical attendants. I may say that I have alluded to this remarkable piece of family history in my book on albuminuria; but the particulars I am about to adduce are in some respects more complete, and are crowned with the final observation which alone makes them proper for the consideration of the Pathological Society.

The first generation, of which the record is explicit, consists of a brother and four sisters. The brother died suddenly, after long wasting, "of kidney disease in some shape," at the age of 34. Of the four sisters two died at the respective ages of 49 and 48, each having had albuminuria for many years.

The brother left six children, two sons and four daughters, which constitute the second generation. Of the six four became the subjects of albuminuria. The second son died with it at the age of 26, having had it since the age of 12. The eldest daughter died of it at 39, having had it since 16; the second daughter, still alive, has it; the third daughter died of albuminuria complicated with diabetes.

All the sisters left children, two of the four transmitting albuminuria. The eldest sister left six children, of which more here-

Digitized by Google

after; the third left five, one of which has albuminuria. These constitute the third generation.

Of the six children of the eldest sister five became albuminuric, the second son only escaping; the eldest son has it; the third son had it in an intermitting form from early boyhood, but lost it before the age of 23; the fourth son had it from 17 to his death at 25. Of the two sisters one displayed the disease at the age of 9 months, and died with it at 33; the other displayed it at 6 months, and has it at the age of 19.

The disorder presented itself in the fourth generation in the person of the only child of the elder sister, whose urine was found to be albuminous within 5 hours of birth,[1] and so remained.

[1] The presence of albumen in the urine at birth, or soon after, does not appear to be exceptional, or necessarily an indication of disease. In the case in question more importance must be attached to the continuation of the albuminuria than to its occurrence at the early period of life at which it was first observed.

Mr. Leonard Remfrey, Obstetric Assistant at St. George's Hospital, kindly undertook at my request to inquire into the condition of the urine of new-born children in this particular. He found the inquiry beset with difficulty, but with perseverance and the occasional use of a catheter was eventually able to procure samples passed during birth or within a few minutes of it in seventeen cases. The quantity passed seldom exceeded two drachms.

Mr. Remfrey thus states his results:—"All the specimens are colourless, looking like water. Reaction various, generally neutral; sometimes faintly acid or alkaline. Sp. gr. not determined. In none of the cases of albuminous urine has that of the mother been found to contain albumen. All the tests have been made with cold nitric acid, except when otherwise stated.

Condition of Urine at Birth, as ascertained by Mr. Remfrey, in seventeen cases.

Sex.	Albumen.	Sex.	Albumen.
Male.	Trace.	Female.	Trace.
Male.	Trace.	Female.	Trace.
Male.	Large trace.	Female.	One tenth (by boiling).
Male.	Trace, two hours after birth contained yellow lithates.	Female.	Large trace.
		Male.	None.
Female.	None.	Male.	Trace; urine opalescent, contained epithelium in large quantity.
Female.	Much.		
Female.	None.		
Female.	Faint trace.	Male.	Decided trace.
Male.	Large trace, a few granular casts.	Male.	Trace.

Thus of the total of seventeen observations, fourteen gave the reaction of albumen with nitric acid in the cold. This test is of course not absolutely con-

Digitized by Google

This pedigree is not yet complete in its morbid relations; to make it so I must revert to the first generation and to the brother suspected of albuminuria, but not convicted of it, from whom all the subjects of albuminuria in the succeeding generations hitherto mentioned are descended. The wife of this ancestor was not free from the suspicion of possessing herself, or at least transmitting, an independent strain of renal disease. Her father had "died young from some form of kidney illness." After the death of her first husband, the ancestor in question, she married again, and had a daughter, who has had albuminuria more or less for twenty years; this daughter has a son, who is also albuminuric. It is therefore probable that the morbid proclivity under notice may have descended upon the second and subsequent generations from two sources.

It is possible that this morbid tendency may have existed for a longer time than is recorded. The family is an ancient one. Portraits have been preserved from as far back as the time of Edward IV, and I am informed that they generally display, whether from time or disease, a peculiar transparent pallor, like that which prevails among the living members. I can imagine one of this gallery of pallid ancestors addressing another, *mutato nomine*, in words which were used at a scene in which one of them bore a part—

> "Look I so pale, Lord Dorset, as the rest?
> Aye, my good lord; and no man in the presence
> But his red colour hath forsook his cheeks."

As regards nine of the members of this family group I am able to annex particulars which will illustrate the nature of the disease. These will be briefly given, the case which eventuated in a *post-mortem* examination, of which the results are before the Society, being related in somewhat fuller detail.

The numbers refer to the position of the individual in the generation as regards seniority, and correspond with those in the annexed genealogical table.

Second generation. 3. *Female.*—Had albuminuria since the age of 16, and possibly earlier. Dropsy of the legs first appeared

clusive, but the quantity of urine generally obtained did not suffice for an exhaustive examination as would otherwise have been employed.

Mr. Remfrey states that the specimens, with one exception, were obtained through the kind co-operation of Dr. Daniell, House Surgeon of Queen Charlotte's Hospital.

Digitized by Google

during pregnancy, at the age of 26, and continued afterwards intermittently. Up to the age of 29 the urine passed at night was said to be free from albumen; afterwards the urine was albuminous at all times. Latterly the patient became blind as the result of albuminuric retinitis, and died with uræmic symptoms at the age of 39.

Second generation. 5. *Female.*—When between 40 and 50 suffered much from bronchitis, while under treatment for which the urine was found to contain albumen, and subsequently sugar. The patient was gouty. I saw her about two years after the albumen had been discovered. The urine then contained 4 per cent of sugar, albumen only to opacity. Numbers of vegetable spores were seen, such as were found in numbers 4 and 6 of the third generation. Before the diabetes became manifest the patient had had much anxiety and been disturbed by nocturnal illusions. There was occasional swelling of the ankles at night; no signs of over arterial tension. The symptoms of diabetes latterly preponderated over those of albuminuria. Death occurred under circumstances with which I was not fully acquainted.

Third generation. 3. *Male,* aged 31.—Formerly had albuminuria rather severely, but for the last nine years, during which the urine has been frequently examined, no albumen has been found, nor any sugar. Spores like those of the yeast-plant have sometimes been seen, and often amorphous lithates, uric acid, and oxalate of lime. He is a strong man, rather pallid, but apparently in perfect health, with no excess of arterial tension nor any evidence of renal disease.

Third generation. 4. *Male.*—Albuminuria first detected at the age of 17, after some excess in drink, from which time it continued until death at the age of 25. He was generally pallid. There was usually no dropsy, though occasionally a trace of œdema was found on the tibiæ. The heart's dulness was somewhat increased; the sight remained clear. About two years before death he went to travel, suffered shipwreck, with much exposure, and was severely attacked with malarial fever. On reaching home he had a return of this, the temperature going up to 103·5°; this was immediately succeeded by acute pulmonary symptoms, apparently of the nature of congestion or inflammatory œdema, agonising dyspnœa, with crackling sounds and dulness, chiefly at the left base. He sank rapidly, remaining conscious to the last.

The urine was usually pale and abundant. On one occasion

Digitized by Google

when it was measured it amounted to 5½ pints in the twenty-four hours. The specific gravity ranged from 1007 to 1024; the albumen from a trace to one third, excepting on one or two occasions, when none could be found. The albumen was generally more in the evening than the morning. The urine was usually acid, sometimes highly so; once or twice it was alkaline, and was once found to be ammoniacal and to contain triple phosphate. No sugar was ever found, though torulæ often were. Numerous casts were found, granular, epithelial, and hyaline (see Illustration). Blood-corpuscles were occasionally seen. No crystals were found, excepting once triple phosphate, probably the result of changes outside the body.

The corpse was extraordinarily pallid. There was no œdema. Only the abdomen could be examined. The spleen was hard, and o about twice the normal size, probably from malarial disease. The two kidneys weighed together just over 9 oz., the right 4, the left 5. The smaller was preserved entire, and is now before the Society; the larger was used for examination.

The capsule was much thickened, but with force came off cleanly, displaying a surface in a typical condition of granulation like that of the ordinary contracted granular kidney. The prominences were of light buff colour divided by delicate vessels. The section was characteristic; both cortices and cones of a light buff colour; the cortex somewhat diminished, so that the cones approached the surface somewhat more nearly than in health, but not so closely as is sometimes seen. The cortex was streaked with opaque yellow lines, which to the naked eye looked like what they afterwards proved to be, distended tubes. The cones were also pale in colour; in the central part of the organ they had the appearance of having been narrowed by pressure of the intermediate cortex. The whole organ was remarkably tough and fibrous in feel. One or two small cysts were seen. There was some excess of fat about the pelvis. To the naked eye the kidney had exactly the appearance of that form of the granular kidney which succeeds upon scarlatinal or some other form of nephritis. There was no lardaceous reaction.

Under the microscope, the epithelium was generally free from fatty change. There were many elongated fibre-cells.

The organ was examined in section by Dr. Delépine and myself, with the following results. I have also to thank Dr. Delépine for one of the sections, and the drawing which is now reproduced. The

Digitized by Google

Digitized by Google

PLATE IX.

To illustrate Dr. Dickinson's paper on Hereditary Albuminuria. (Page 144.)

Digitized by Google

Hereditary Albuminuria.

Trans. Path. Soc. Vol. XL. Pl. IX.

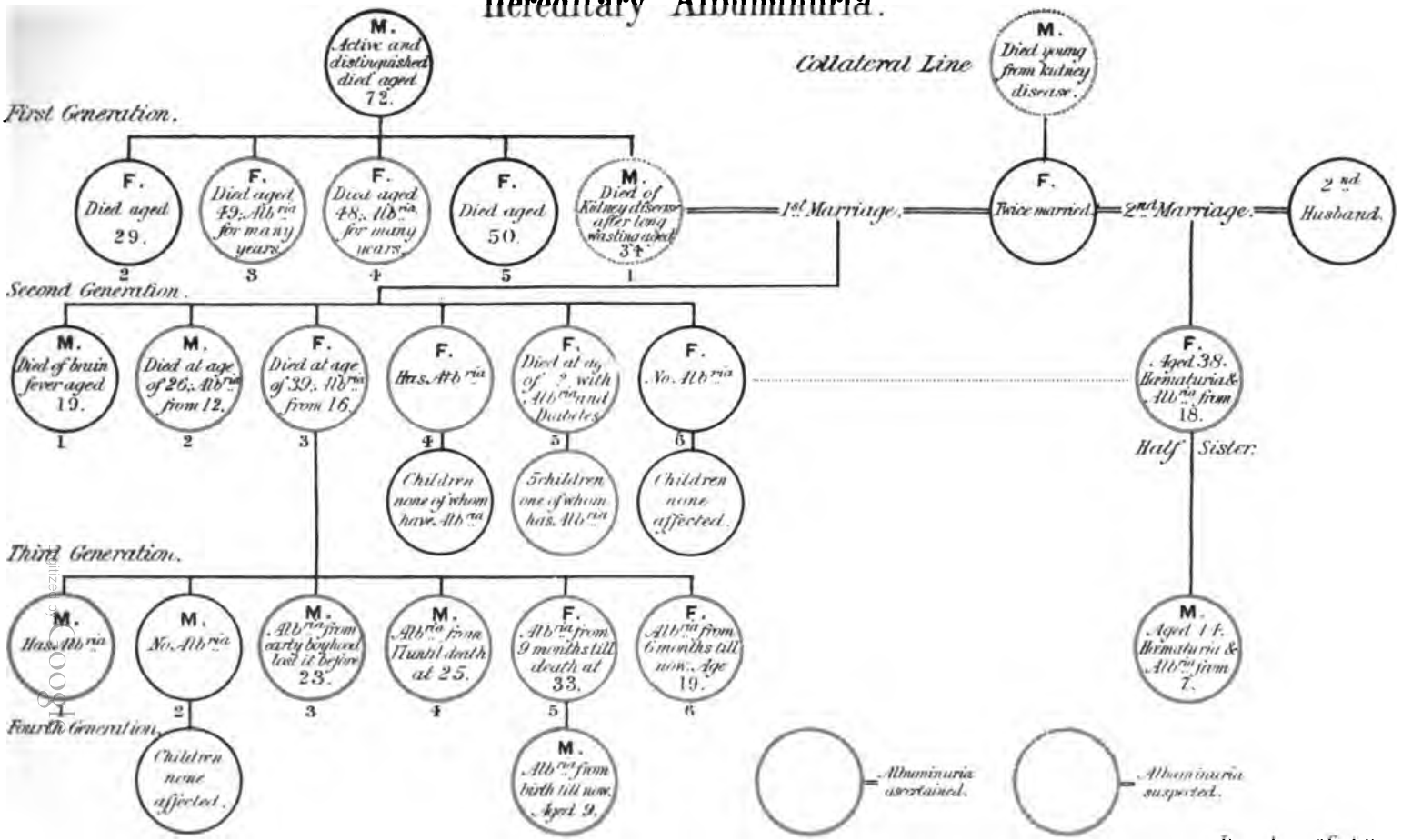

Digitized by Google

Digitized by Google

DESCRIPTION OF PLATE X.

To illustrate Dr. Dickinson's paper on Hereditary Albuminuria. (Page 144.)

FIG. 1.—Second generation. Half-sister. Dark granular casts and blood-corpuscles.

FIG. 2.—Third generation. 4. Male. Granular, epithelial, and hyaline casts. Blood-corpuscles and vegetable growths. This relates to the case of which the *post-mortem* examination is related.

FIG. 3.—Third generation. 6. Female. Granular and epithelial casts. Blood-corpuscles. Vegetable growths.

FIG. 4.—Third generation. Half-sister's son. Casts chiefly epithelial. Blood-corpuscles.

FIG. 5.—Fourth generation. Male. Fine granular cast.

Digitized by Google

Fig. 1.



Fig. 2.

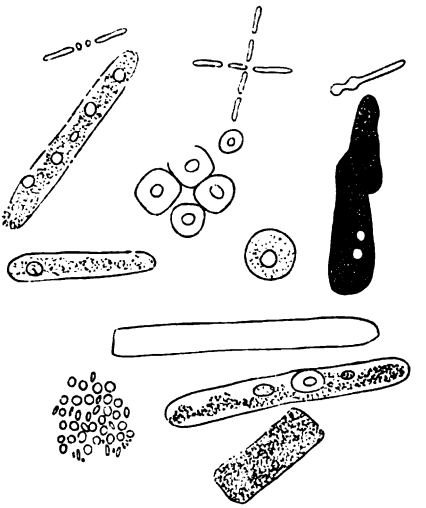

Fig. 3.



Fig. 4.

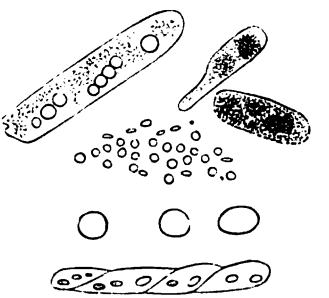

Fig. 5.

Digitized by Google

Digitized by Google

Digitized by Google

DESCRIPTION OF PLATE XI.

To illustrate Dr. Dickinson's paper on Hereditary Albuminuria. (Page 144.)

Section of kidney from the case in which albuminuria was hereditary. The section has been made at right angles to the surface which forms the upper edge of this drawing. This shows:

1. A universal profusion of delicate nuclei belonging to the interstitial tissue.
2. Tubes in various states: some shrunk, others obstructed with casts or otherwise, some natural, more particularly a round group in the lower part of the engraving towards the right side.
3. Malpighian bodies, some of which are in a state of atrophy.
4. Thickened arteries.
5. Calcareous masses embedded in the kidney, as described in the text.

Digitized by Google

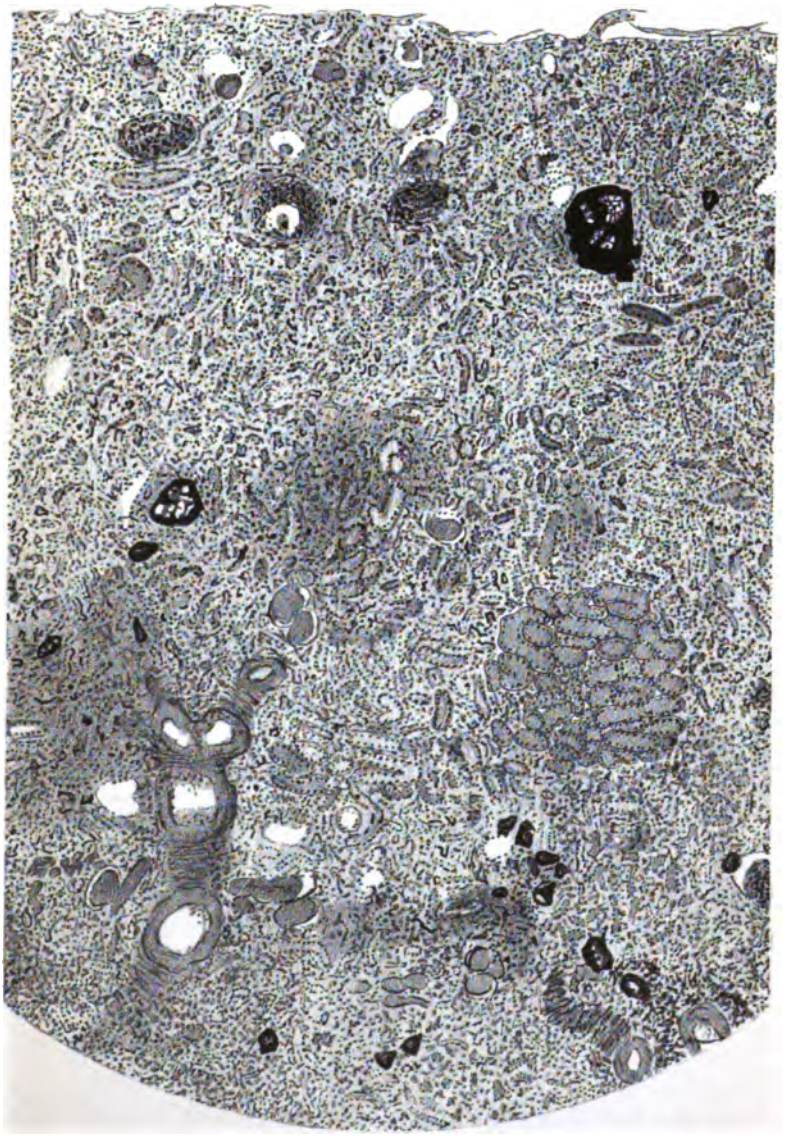

S. Delépine del.

West, Newman lith.

x 40

Digitized by Google

Digitized by Google

results were these. In some places, especially under the capsule, which was abnormally thick, was much vascular injection. Of the more persistent changes, the most conspicuous was a great general increase of the interstitial fibrous tissue at the expense of the Malpighian bodies and tubes. The older fibroid tissue was increased; beside which there was a general profusion of delicately nucleated fibroid tissue apparently of more recent growth. The Malpighian bodies were diminished in number, and many of them atrophied and contracted. The tubes were wanting or obscured in many parts, while in others, particularly in the cones, they were dilated, and occupied by casts which formed conspicuous objects. These were sometimes hyaline and translucent, often strongly marked, and of a coarse granular character. Besides these tubal casts were a large number of small concretions many of which were intratubal in position, and so nearly resembled the casts in texture and size that it was difficult to draw an abrupt demarcation between them. Other concretions were larger and less obviously associated with the tubes, so that it was a matter of inference rather than observation that they had taken their origin in changes within them. Some of the concretions were but little acted on by acids, and were evidently organic; others were as obviously calcareous. Dr. Delépine satisfied himself and me that some dissolved in hydrochloric acid with effervescence, and were probably carbonate; others dissolved in nitric acid without effervescence, and were probably phosphate or oxalate.

The arteries were generally thickened, as is usual with the granular kidney. The only exceptional point in the morbid anatomy was the abundant collection of concretions. There could be little doubt that these were of tubal origin, though with many all traces of their anatomical position were lost. They sometimes presented themselves as rounded groups of opaque dots which appeared to be in the interstitial tissue. It is probable that these concretions were secondary to other changes rather than the primary mischief. Dr. Delépine suggests that they may have been consequent upon the atrophy of the Malpighian bodies, and consequent want of wash in the affected tubes.

Third generation. 5. *Female.*—Was for many years the subject of albuminuria, and died with uræmic symptoms at the age of 33.

Third generation. 6. *Female,* aged 19.—Has had albuminuria since she was an infant at the breast. Has a remarkably pale

Digitized by Google

delicate complexion. Has been generally free from dropsy excepting occasional traces of œdema on the tibiæ. The cardiac dulness has been thought to be somewhat increased, and the pulse rather tense. The retinæ have been examined and found to be normal. Eczema of the skin has been occasionally present. From its first detection albumen has been constantly found in the urine, occasionally only a trace, but as a rule in tangible quantity ranging up to two fifths, the amount being greater latterly than in earlier years, and usually greater in the evening than the morning. The presence of fungoid vegetations frequently suggested search for sugar, generally with a negative result; once reduction of copper gave evidence of a small amount. The quantity of the urine was not noticeably abnormal; the specific gravity varied from 1007 to 1026. It was generally acid, free from crystalline deposit, excepting once or twice when it was alkaline, probably from decomposition, and displayed triple phosphate. Large granular and epithelial casts (see Illustration) were often found, and occasionally blood-corpuscles.

Fourth generation. ***Male,*** aged 9 years.—Within five hours of birth the urine was found to contain albumen to the amount, as I was informed, of about one twelfth. The urine remained albuminous, the albumen varying from a cloud to one eighth; the specific gravity from 1020 to 1027. The urine was generally pale and highly acid. Uric acid was often deposited in considerable quantity. Blood-corpuscles were occasionally found, and once a well-marked, finely granular cast. Sugar was always absent. There was never any œdema or any recognised constitutional symptom of renal disease.

Collateral Branch.

Second generation. ***Half-sister,*** aged 38.—Became subject to attacks of hæmaturia at the age of 18, and has since repeatedly passed blood with the urine, and often albumen, when there was no blood. The albuminuria has not been constant. On some occasions no trace of albumen could be found; at other times the albumen was considerable and the blood often enough to give a strong colour. The urine was more bloody and albuminous during pregnancy, and it was thought to be made worse by cold. It frequently contained lithates, and often large granular casts (see Illustration). There has never been any œdema or constitutional sign of renal disease

Digitized by Google

unless pallor be so regarded. The habitual health was regarded as vigorous.

Third generation. Half-sister's son, aged 14.—Only son of half-sister. I first saw him at the age of 7, when I learned that he had been liable to attacks of hæmaturia for several years. These, in which the urine became deeply smoky and displayed abundant blood-corpuscles, came on at irregular intervals, and were often preceded by severe rigors and attended with pain in the loins and over the pubes. Intermittent hæmaturia was suggested by the rigors, but negatived by the uniformly corpuscular character of the blood. The bladder was sounded for stone, with a negative result, and a hypothesis of tubercular disease of the kidney, which was advanced by one of his advisers, was set aside by the persistent absence of pus in the urine and the progress of the case. The attacks were not brought on by exercise. It was thought that cold sometimes induced them, but more often they were without ostensible cause. The albumen was generally slight, often only a trace, excepting when the blood was present. The urine was often lithatic, and sometimes displayed crystals of uric acid and of oxalate of lime. Large epithelial casts, as shown in the plate, were sometimes found. There was usually no dropsy, though once or twice under the attacks the face and eyelids became puffy. The boy had formerly a delicate and anæmic appearance, but of late has gained more of the aspect of health.

The general clinical resemblance in the group of persons affected makes it probable that the complaint in all was of the same nature though not always to the same degree. I show outlines of casts from five of seven individuals whose urine I have examined, besides which there is a general resemblance in history and symptoms. The albuminuria shows itself early, in one case at 9 months, in another at 6, in a third at birth. The disorder is of long duration, often lasting from childhood to middle life; the symptoms of it have usually been long in abeyance or little conspicuous, pallor and perhaps an occasional trace of œdema being in many cases for long the only ostensible results. In one instance, in which the uræmic characters were strongly declared, the disorder was complicated with repeated pregnancy. Although usually persistent there is at least one case in the group in which the albuminuria after lasting many years, passed off.

If we may apply to the rest the morbid anatomy of the one case

Digitized by Google

in which it was displayed, it would seem that the disorder is a chronic form of diffuse nephritis which affects the tubes and Malpighian bodies, and usually (but perhaps not invariably, if we may judge by the one instance of recovery) the interstitial tissue.

As to the cause of the renal inflammation, or irritation, we may first ask whether any habitual state of urine, or urinary diathesis, which could underlie and bring about the organic change is to be traced as a family possession. Such an inquiry is discouraged at the outset by the early period of life at which the albuminuria has presented itself, in one instance at least so early that it was manifest that the conditions on which it depended must have existed before birth. Of the seven cases in which I had occasional opportunities of examining the urine, sugar was present in two, in one to the amount of diabetes, in one only a trace, and that but seldom. In all the urine was generally acid, in one highly so. Uric acid crystals were sometimes present in three, amorphous lithates in three, crystals of oxalate of lime in two. In none were there any phosphatic deposits, save once or twice when triple phosphate was found, the urine beiug then ammoniacal probably from decompositions. Blood-corpuscles were often present in four instances, in two abundantly. Diabetes was therefore not to be regarded as a general antecedent, nor did the urines generally display any such frequency or constancy of crystalline deposits as to suggest any calculous process as the general origin of the renal change. Gout was a marked concomitant in one case. I am not aware that it was so in others. The effect of alcohol was not to be entirely excluded from all, but the frequency of the disease in females and in early life absolutely excluded this as a general cause of the disease. What then was it due to? The facts appear to convey no other suggestion than that of hereditary tendency, bearing directly on the kidneys; some special susceptibility or vulnerability belonging to these organs as part of their original formation. It is known that the granular kidney is sometimes a matter of inheritance, and were this a clinical society I could adduce other examples, though none so striking.

I ventured some years ago to refer to this group of persons as exemplifying the hereditary transmission of the granular kidney, though at that time there had been no *post-mortem* within my knowledge. What was then only a surmise now becomes a pathological fact, and as such I thought it might be worthy of the notice of this Society. *May 7th*, 1889.

Digitized by Google

2. *Two cases of unilateral nephritis with atrophy of the kidney induced by pressure,* (1) *on the ureter, and* (2) *on the renal blood-vessels.*

By George F. Crooke, M.D.

Although claiming nothing new or original in the cases which I have the honour of submitting to the Society to-night, still I venture to think there is much that is interesting from a pathological point of view, because we have presented to us remarkable instances of disease extrinsic to the kidneys themselves, performing, so to speak, experiments for us, the results of which are histologically analogous, if not identical with the changes found in that form of disease known intrinsically as the granular contracting kidney.

The changes in the affected kidneys were produced by mechanical pressure, which in one case was limited in all probability to the excretory duct of the kidney, while in the other it was exerted on the blood-vessels as well.

But while the result in both was the same, viz. atrophy and contraction of the kidney, microscopic investigation reveals differences in the histological appearances which I thought would be interesting to lay before the Society, and which are demonstrated in the specimens placed under the microscopes in the next room.

Before proceeding to discuss these, it will be necessary to furnish you with some particulars of the cases from which the kidneys were taken, and this I will now do as briefly as possible.

The first case was that of a young girl aged 16, in whose right broad ligament a cystic tumour had been developing for some time. When admitted, the tumour had attained a large size, causing considerable distension of the abdomen. She had a well-marked cloud of albumen in the urine, and in some collected after death a few granular casts were found.

In other respects she seemed quite well, complaining only of the discomfort and inconvenience caused by the tumour. In fact she had continued to perform household work at home up to the day of admission.

Ovariotomy was performed, and a large unilocular cyst evacuated, its pedicle ligatured, and the tumour removed. The operation was quite easy and in every way favorable.

Digitized by Google

A day or two after, acute bronchitis set in and she died a week after the operation, more or less cyanosed. At the autopsy, the operation wound was nearly healed, but there was found general purulent peritonitis, which, as regards subjective symptoms during life, was quite latent; for up to the last the patient made no complaint of pain, even on palpating the abdomen. Still it was suspected from the distended state of the abdomen and fixation of the walls. There was diffuse bronchitis in both lungs, old pleural adhesions on the left side, pulmonary collapse and emphysema; pedicle of the tumour was found tightly ligatured, stump healthy and granulating.

The right kidney weighed 2¾ oz., was uniformly contracted, its capsule a little thickened and adherent, surface slightly granular. On section the appearances resembled those of a small white kidney; the proportion of cortex to medulla was one fifth to three fifths of an inch. Consistence rather tough; no visible thickening of the arteries, and no sign whatever of dilatation of the pelvis or ureter.

Briefly, the histological changes are as follows: (1) Marked dilatation of the convoluted tubules in the subcapsular portion of the cortex, the majority of which are distended with a clear coagulated exudation and show pressure atrophy of their epithelial lining; (2) dense small-celled infiltration of the intertubular stroma. Occasionally a Malpighian capsule is seen similarly dilated and filled with exudation, all trace of the glomerular capillaries being lost.

Irregular patches of interstitial thickening and infiltration are found closely distributed in the deeper parts of the cortex, but here a number of oval and spindled nuclei are met with, indicating a process of organization and contraction of the interstitial proliferation. These patches include a number of atrophic tubules.

Glomeruli.—Many show nuclear proliferation in and about the capillary tufts, but there is a marked absence of glomerular degeneration.

Blood-vessels.—The larger arteries show slight irregular thickenings of the intima, the smaller interlobular branches some thickening of the muscular coats, and nuclear increase of the muscle-cells; but the arterial changes are far less prominent than in the next case. The medullary stroma is likewise thickened.

The left kidney weighed nearly 5 oz., was generally flaccid and

Digitized by Google

paler than normal. Capsule stripped readily, leaving a smooth surface. Microscopically there is cloudy swelling and granular degeneration of the epithelium of the convoluted tubules, but the stroma is unaffected.

Heart small but normal; left ventricle five tenths of an inch thick, weight 8 oz.

The points in this case to which I would direct your attention before proceeding to the next, are: absence of any sign of dilatation of the ureter and pelvis of the kidney; predominance of the changes in the intertubular stroma leading to atrophy of the parenchyma and contraction of the kidney, and, comparatively speaking, absence of marked degenerative changes in the glomeruli and blood-vessels. Absence of compensatory enlargement of the opposite kidney.

The second case was that of a young man, aged 21, admitted with abdominal symptoms so urgent that the surgeon who was called to him decided, after consultation, to perform laparotomy and explore the region of the cæcum. It was noticed that he had a solid growth of the left testicle. At the autopsy this proved to be a chondrefying sarcoma; early peritonitis with sanguineous exudation into the abdominal cavity was found. A huge sarcoma hæmatodes involved the outer half of the right lobe of the liver, and had caused rupture of Glisson's capsule, between which and the liver-substance there was interposed a large flattened blood-cake. Occupying the position of the left kidney was a large mass, which extended inwards in front of the spine, covering the abdominal aorta and renal blood-vessels, and reached below as far as the brim of the pelvis, covering the common and external iliac and the ureter. It was removed *en masse*, together with the structures in relation to it, and was bisected from behind along its posterior rounded border.

It was found to be the kidney with a large sarcomatous growth in the hilus, surrounding the pelvis and blood-vessels, and constricting the lumen of the ureter at the lower end of the kidney, which was just beginning to be invaded by the growth. The calyces were dilated and contained some turbid urine, and the larger divisions of the renal artery were thickened.

Regarding the appearances of the kidney itself, it was generally anæmic, the cortex was yellowish grey in colour, the structure pattern of the kidney was obscured, and the medullary cones were

Digitized by Google

of a pale red colour; the larger branches of the renal arteries between them looked much thickened; still the kidney was by no means much atrophied or shrivelled,

Weight of growth with kidney attached 36½ oz.

Heart 11 oz.; left ventricular wall soft and flaccid; no valvular lesions, no hypertrophy.

In studying the histological changes in this kidney we must commence with the blood-vessels, especially the renal artery, its branches and terminations.

The larger branches have undergone considerable thickening, involving all the coats; thus we have marked endarteritis, hypertrophy of the muscular coat, as well as considerable increase in the periarterial fibrous connective tissue. These changes can be followed out in the smaller and even in the terminal branches (afferent arterioles), some of which appear so thickened as to be practically obliterated (endarteritis obliterans).

The alterations in the glomeruli, which are the direct sequence of the above, consist in hyaline fibroid degeneration of a large number throughout the cortex, so that under a low-power view they at once attract attention.

Next come thickening of the intertubular stroma, which contains in places a number of round and spindle-shaped nuclei, and contraction of the tubules, the epithelium of which is broken up into a number of small, irregularly-shaped, nucleated fragments.

A general view under a low magnification of all the above changes taken together reminds one forcibly of the histological picture of the arterio-sclerotic form of the contracting kidney, and indeed is hardly distinguishable from it.

The right or corresponding kidney in this case weighed 5 oz.; capsule stripped well, leaving a reddish-grey surface. On section it was generally anæmic, the cortex being of a yellowish grey-white colour, the medullary cones a pale red. Microscopically the changes were limited to the parenchyma, and consisted mainly in swelling and granular degeneration of the epithelium of the convoluted tubules. The stroma looked quite normal.

If we come now to contrast these two cases, the differences in the histological appearances seem to correspond with differences in their histogenesis. The first case is purely one of irritative interstitial nephritis going on to contraction, the result of a mechanical impediment to the excretion of urine by compression of the excre-

Digitized by Google

tory duct. But how are we to explain the absence of dilatation of the ureter and of evidences of hydronephrosis?

It is possible that, as the cystic tumour grew out of the pelvic into the abdominal cavity, pressure on the ureter was gradually suspended, so as to allow it to resume its normal size. The effects, however, on the kidney were probably progressive, the interstitial cell-proliferation passing on to organisation and contraction.

Regarding the second case there can, I think, be little doubt that the vascular changes played a most important *role*, and the lesion, as a whole, may be referred to disturbances in the circulation, and to the interference with the proper blood supply to the kidney by the pressure exerted by the growth on the blood-vessels around their origin and in the hilus. Hence the explanation of the large number of glomeruli found in a condition of hyaline fibroid degeneration. Similar cases in man have been reported by Burdon Sanderson,[1] Greenfield,[2] and others.[3]

I have still a third case, kindly given me by Dr. Carter, senior physician to the Queen's Hospital, Birmingham, of an aneurysm of the abdominal aorta pressing on the renal blood-vessels on one side, and causing atrophy of the kidney. Though I have not yet had the opportunity to work the case up, I hope at some future time to do so.

Another point worthy of attention is the resemblance of the histological changes described in the above cases to those obtained by various pathologists in their experimental investigations on nephritis induced by ligation of the ureter and renal artery.

By ligature of the ureter Charcot and Gombault[4] induced an interstitial nephritis with atrophy and contraction of the kidney. Straus and Germont,[5] although modifying the operative procedure

[1] "Constriction of Ureter by Growth," 'Path. Trans.,' vol. xxiii, p. 159.

[2] "Two cases: one of Atheroma of the Renal Artery, leading to gradual occlusion of the vessel, with atrophy of the Kidney; the other of sudden occlusion of the vessel by Thrombi, resulting in a general necrobiosis of the Kidney in a case of Ovarian Tumour," 'Path. Trans.,' vol. xxvi, p. 135.

[3] West: "Obliteration of the left Ureter by Omentum adherent to the Brim of the Pelvis, with subsequent atrophy of the left Kidney and complimentary hypertrophy of the right," 'Path. Trans.,' 1881, vol. xxxiii, p. 203. "Occlusion of both Ureters; death by Syncope," Bell, 'Lancet,' 1883, ii, 1040. "Anuria from compression of Ureters by Cancerous Disease," Minot, 'Boston Med. and Surg. Journal,' 1884, cx, p. 217.

[4] 'Arch. de Physiologie,' 1881.

[5] "Histological Lesions in the Kidneys in Rabbits following Ligature of the Ureter," ibid., 1882, pp. 386—411.

Digitized by Google

by adopting antiseptic precautions, arrived practically at the same result. They noted that glomerular and vascular changes were comparatively speaking of minor importance to the parenchymatous and interstitial, viz. dilatation of tubules, degeneration and atrophy of epithelium, interstitial changes, with consequent atrophy and collapse of the kidney substance. Grawitz and Israel,[1] Talma[2] and Von Werra[3] and Csokor[4] experimented by ligaturing the ureter on one side, for periods varying from a few hours to several days, and then observed the effect on the kidney. The first changes consisted in an acute hæmorrhagic parenchymatous nephritis, which terminated either in the chronic or in an interstitial form, attended with contraction and atrophy of the kidney. In a drawing given of a section of such a kidney of a rabbit, where the experiment had been performed some months previous to death, the details delineated by Grawitz and Israel resemble those found in our second case. There are numbers of degenerated glomeruli seen midst a thickened fibroid stroma, containing atrophic and shrivelled uriniferous tubules.

Whether the acuter changes were ever present in the first case is a question that hardly admits of a definite answer. Certainly I have noted in some parts, where the intertubular stroma has undergone much thickening, a number of round and spindle-shaped nuclei that would seem to favour this assumption.

Lastly, there are other facts to which I would draw attention, viz. the absence in both cases of compensatory hypertrophy of the opposite kidney, and the probable causal relation between the kidney changes in the first case and the fatal issue after the operation.

In the absence of compensatory hypertrophy of the opposite kidney, and in the extreme atrophic condition of the affected one, it is reasonable to assume that there must have been impairment

[1] "Experimentelle Untersuchung über den Zusammenhang zwischen Nierenerkrankung und Herzhypertrophie," 'Virch. Arch.,' Bd. lxxvii, p. 315. "Experimentelle Untersuchung über den Zusammenhang zwischen Nierenkrankheiten und Secundären Veränderungen des Circulations Systems," 'Virch. Arch.,' Bd. lxxxvi, p. 299.

[2] "Unterbindung der Nierenarterien und seine Erfolgen," 'Zeitschrift für klin. Med.,' 1880–1, pp. 483—508.

[3] "Ueber die Erfolgen der Vorübergehenden und dauernden Unterbindung der Nierenarterien," 'Virch. Arch.,' Bd. lxxviii, p. 197.

[4] 'Ueber die Folgen der Unterbindung der Ureteren und Nierenarterien bei Thieren mit anderen pathologischen Processen.'

Digitized by Google

of the renal excretory functions, and the predisposition to bronchitis and peritonitis after a severe surgical operation, may, I think, be reasonably referred to it.

In conclusion I beg to acknowledge my indebtedness to Dr. Wade and Dr. Malins, and to Mr. Chavasse, for their permission to use the above cases.

April 16th, 1889.

---

8. *Cystic dilatation in a cirrhotic granular kidney.* (*Card specimen.*)

By Samuel G. Shattock.

The kidney presented at the surface two small pale areas, somewhat wedge-shaped in section; that examined measuring in the vertical direction 4 mm., in the opposite, 6 mm.

Microscopic examination shows the areas so altered to be formed of a congeries of dilated tubules, lined throughout with epithelium; to the naked eye they present an obvious spongy or cavernous appearance. On either side the cystic portion is bounded by a line of fibrous tissue, in which lie minute atrophied tubuli, and obsolete Malpighian bodies appearing as sparsely nucleated hyaline spheres. There are similar fibrous bands passing at intervals from the surface in the adjoining portion of the renal tissue, such as characterise the cirrhotic granular kidney.

It will appear therefore that the cystic dilatation is limited to a portion of the renal substance comprising a "granulation," and it has doubtless resulted from the distribution of the contracting tissue having been such as to obstruct one or more group of secreting systems.

Small isolated cysts, or cysts linearly arranged in the cones, are common enough in granular kidneys, but the condition under notice is unusual; it is as rare as it is unimportant.

March 5th, 1889.

Digitized by Google

4. *Cystic degeneration of kidneys, with two ureters on right side.* (*Card specimen.*)

By A. M. Jackson, M.B.

The specimens are from a man, aged 35, who died in the Surrey County Asylum of general paralysis of the insane. He was admitted on November 26th, 1888, in a state of mania, with history of two weeks' duration, and weighed 8 st. 8 lb. He suffered from hæmatoma aurium early in January, rapidly became emaciated, with bedsores developing three weeks before death. Died comatose, without convulsion, on March 12th.

Autopsy.—Weight of body 5 st. 3 lb.

There was a thin film of false membrane, and numerous small hæmorrhages beneath dura mater on both sides; atrophy of brain, and large amount of subarachnoid and ventricular fluid.

Heart: 8¼ oz.

Kidneys weighed 19 oz. each, much the same size and appearance. Capsules very adherent: numerous transparent cysts on surface of organs, containing clear straw-coloured fluid. Longitudinal section showed cysts of various sizes up to that of a walnut, the contents of which differed, some being filled with yellowish cheesy material, and one of the largest with red semi-fluid débris. Remains of cirrhotic renal substance between cysts and pelvis of left kidney dilated. On right side there was a supplementary ureter from upper portion of organ. The two ureters were traced side by side to the bladder, and opened by separate orifices about half an inch apart, one at base of trigone, the other within the trigone. Bladder contained purulent-looking fluid.

There were no cysts found in liver.

General vascular degeneration indicated by hæmatoma aurium and subdural hæmorrhage. *March 19th*, 1889.

Digitized by Google

5. *Absence of upper two thirds of left ureter, with very small cystic kidney. Surgical right kidney after gonorrhœa.* (*Card specimen.*)

By Frank Penrose, M.D.

The specimen shows the upper two thirds of the left ureter, represented by a fine band of fibrous tissue. The lower one third is fairly developed. The left kidney consists of a few small cysts. The renal vessels are unduly small. In the right kidney were two abscesses, which apparently have existed for some time. The ureter and its pelvis are considerably dilated.

History.—W. S—, aged 25, had gonorrhœa eighteen months ago, and had been ailing off and on ever since. A month ago he felt so ill that he gave up his employment of shop assistant owing to constant pains in the legs. A week ago he came to St. George's Hospital and fainted in the surgery. He was admitted under Dr. Cavafy.

On admission, râles were heard through both lungs, and the urine contained pus and one sixth albumen. Nothing else was detected. Twelve hours before death he had five fits rapidly one after the other. The spasms were most marked on the right side. This was followed by coma and death.

At the *post-mortem:* recent purulent pericarditis; the urinary organs as shown in the specimen. An old hæmorrhage in the fundus of the right eye. No gross intracranial lesion.

May 7th, 1889.

---

6. *The histological changes in the kidney in hydronephrosis.*

By Joseph Griffiths, M.B.

During the last two years I have had, on different occasions, opportunities of examining the minute histological changes which occur in the renal structure in cases of hydronephrosis, and of studying those additional factors which arise in the course of the disease from distension of the pelvis, and which induce changes in the kidney leading to its gradual disappearance. My observations were made on kidneys which were found in all stages, from

Digitized by Google

the slightest to the most complete, of distension of the pelvis and calyces, and in which the renal structure was but slightly altered or had completely disappeared.

The actual and indeed the possible causes of the production of this disease, and the anatomical characters the kidney presents, are ably discussed in several works on pathology, medicine, and surgery; but when information is sought regarding the histological changes that occur in the kidney in the course of this progressive affection, it is found to be scanty and very indefinite. I wish, in this paper, to draw attention to those minute changes which occur in the renal structure and also to some of the factors which induce them. The kidney structure gradually diminishes in amount from alterations in the part directly subjected to the pressure of the accumulating urine, and also from changes widely distributed throughout the organ. These two go often hand in hand, until the renal substance has entirely disappeared, and is replaced by a thin or thick layer of fibrous connective tissue. I shall now proceed to the full description of some cases which illustrate the changes induced in the kidney under different conditions in hydronephrosis.

Case 1.—A man, 67 years of age, died of uræmia, the result of double hydronephrosis, which was caused by enlargement of the "third" or median lobe of the prostate. The kidneys were similarly affected, the right, however, being more distended. There was the usual distension of the pelves, and the ureters were nearly three quarters of an inch in diameter, and tortuous in their entire course like varicose veins. The kidneys were not on the whole much enlarged, and on their external surfaces were numerous small translucent cysts, the largest of which did not exceed one third of an inch in diameter. These were similar to those found in chronic interstitial nephritis.

On longitudinal section the papillæ were not visible, and the calyces greatly dilated. Between the calyces was a thin layer of tissue, in which the renal blood-vessels ran. Closer examination of the kidney-substance revealed the existence of small irregular pale patches of fibrous tissue in the cortex and medulla. These fibrous patches gave a tough and firm character to the kidney. The normal arrangement of the Malpighian bodies in the cortex and the straight vessels in the medulla was greatly altered, and the proportion between the cortex and medulla varied in different

Digitized by Google

parts. In some places the medulla had disappeared to a much greater extent than the cortex; but not so in others. Although the papillæ had disappeared, yet there remained a fair amount of medullary tissue. The renal vessels were stretched over the distended pelves and were much flattened, and their walls were also irregularly thickened.

Under the microscope the capsule of the kidney is much thickened and laminated, the cortex much diminished in thickness. In some parts the cortex contains numerous typical wedge-shaped or pyramidal areas, similar to those of chronic interstitial nephritis, and these have their bases near the capsule and extend down towards the medulla; but in other parts the cortex is uniformly affected, and in the cortex thus altered small patches of normal tubules are seen widely separated from one another. The renal structure between these so-called wedges in the former is in many instances flattened from the medulla towards the capsule by the gradual distension of the whole kidney, but apparently in no other way altered. In the wedge-shaped areas, and also where the interstitial change is more uniform, the Malpighian bodies are crowded together and arranged irregularly. They are also seen in various stages of transformation into functionless fibrous knots, from thickening and lamination of Bowman's capsule, proliferation of the cells lining the capsule, and the formation of fibrous connective tissue between the capillaries of the glomerular tuft. Several of the glomeruli have been converted into typical fibrous knots like those seen in chronic interstitial nephritis. The tubules in the altered parts are considerably diminished in number and size, and are usually lined by small clear cubical cells; but in some places the epithelial cells are small, of irregular shape, clear or slightly granular, and fill the centre of the tubule. These tubules are in most places separated from one another by much connective tissue, which consists in some parts of numerous long spindle-shaped cells, and in others of fibrous connective tissue, with only a few nuclei here and there. Surrounding the disappearing tubules may be seen the development of large spindle-shaped connective-tissue cells with a little fibrous material between them in concentric layers, and separated from the epithelium of the tubule by a thick homogeneous layer or basement membrane. The process can be well seen in the cortex and medulla, but it is especially marked in the latter. In some of the

Digitized by Google

wedge-shaped areas the straight or collecting tubules are larger than normal, and filled with proliferated epithelial cells.

At the margins of the wedge-shaped areas, where the more or less healthy renal tissues join them, the convoluted tubules are dilated to form microscopic cysts, which in many instances are lined by flattened epithelial cells, and filled with colloid material. The arteries in the cortex are sinuous, and present considerable fibrous thickening of both intima and media. In the medulla the number of tubules is much diminished, and the intervening connective tissue more pronounced than in the cortex. The tubules in the outer half of the medulla are large, prominent, and in many instances present a sinuous course. These enlarged tubules are filled with proliferating renal epithelial cells. The intervening connective tissue in this, the outer part of the medulla, is somewhat cellular, and the cells are of a spindle or fusiform shape. The tubules that remain in the inner half of the medulla are widely dilated, and separated from one another by much fibrous connective tissue, which in parts contains connective-tissue cells, but in others only a few nuclei. In the outer half of the medulla the connective-tissue cells run parallel to the tubules; but in the inner half the cells or nuclei and the connective-tissue fibres run transversely between the tubules, and so parallel to the free surface of the distended pelvis of the kidney. Many of the collecting tubules near their termination have become dilated to form larger cysts or cavities, which border upon and open into the pelvis. They are lined either by a flattened layer of epithelial cells or by large swollen epithelial cells arranged in more than one layer; the latter are, I presume, constantly formed and cast off into the urine, and so form one of the urinary constituents in this disease.

Where the kidney is most distended a part may be obtained which is lined by the corresponding calyx. In such a specimen it will be observed that the epithelium of the calyx is in parts much like the normal, but in others it is replaced by small irregularly-shaped and imperfectly-formed epithelial cells in a state of proliferation. Doubtless these proliferating cells are also carried away by the urine. The renal arteries outside the kidney are flattened by the distended pelvis, and show marked thickening of intima and media from the formation of fibrous connective tissue. The opposite kidney presents similar changes, which, however, are more advanced.

Digitized by Google

Case 2 is an example of very advanced hydronephrosis in the Cambridge Museum. The pelvis is much distended, and the pelvic wall is somewhat thickened from chronic inflammation. The kidney is not much, if at all enlarged; the papillæ are flattened and obliterated and the renal structure does not exceed a quarter of an inch in thickness at any part; the medulla has diminished relatively much more than the cortex. The renal vessels, whose walls are thickened, run over the distended pelvis, and are stretched and compressed.

Microscopically, the capsule is thickened and laminated. The cortex is diminished in thickness, and almost entirely converted into fibrous connective tissue, in which there are numerous thickened and sinuous arteries. The altered Malpighian bodies that are still visible are irregularly crowded together. These present the usual changes seen in chronic interstitial nephritis, and resemble those already described in Case 1. A few remnants of the renal tubules are also seen embedded in the connective tissue. In some parts the tubules are represented merely by narrow fissures or channels filled with a granular débris, but in others, although diminished in size, yet contain one or two highly granular epithelial cells; a few tubules contain in addition small colloid casts. The connective tissue between the tubules contains very few nuclei, and has become more or less entirely homogeneous.

The medullary part is even more completely converted into fibrous tissue, and in it may be seen the remnants of tubules similar to those described in the cortex. The renal vessels show the same changes as in the preceding case.

Case 3 is one of partial hydronephrosis, in which the process has advanced so far at one point that but a thin layer of tissue remains, apparently containing no renal structure. This partial hydronephrosis was produced by the lodgment of a calculus in one of the branches of the pelvis. The only point of difference between this and the preceding specimens is that the true pelvis is not to any appreciable extent distended, and consequently the renal vessels run their usual straight course without being subjected to any stretching or compressing influence.

Microscopically the part of the kidney where there has been greatest distension, but where some renal structure still remains, shows the cortex to be diminished, and the medulla even more so. The cortex, in some parts of not inconsiderable extent, presents no

Digitized by Google

trace of changes similar to chronic interstitial nephritis, but in other parts changes occur which correspond in every detail with those seen in the preceding cases. Where the distension has gone so far that only a thin layer, half a line in thickness, is all that represents the kidney at that part, the tissue consists entirely of laminated fibrous connective tissue, without a trace of kidney structure in it. Those parts of the cortex of the kidney where no chronic interstitial changes had arisen are normal, except that the cortex is somewhat narrower, and that the tubules are somewhat compressed and flattened.

The medulla everywhere in the hydronephrotic parts is represented by a very thin layer which, for purposes of description, may be divided, as in Case 1, into two parts, an outer and an inner. The outer and thicker part contains straight tubules, some of which appear normal, whilst others are distended and filled with epithelial cells. The intertubular connective tissue is much increased, and consists largely of spindle-shaped cells; the inner and thinner part consists of fibrous connective tissue with few cells, and in which a number of dilated tubules is embedded. The contents of these dilated tubules have fallen out during the manipulation of the sections, probably due to imperfect hardening.

Case 4 is one of advanced hydronephrosis in a pig. The kidney is entirely transformed into a loculated sac, and only at one part of the circumference can a thin layer, one line in thickness, of kidney structure be detected. The pelvis in this case has only permitted of little distension, although the cause of obstruction to the outflow of urine must have been either in the ureter or lower down in the course of the urinary passages.

The renal vessels have been very closely cut off in the preparation of the specimen for the museum, but it is evident that they could hardly have been subjected to any pressure, from the amount of enlargement of the pelvis.

Microscopically this shows exactly the same appearances as Case 3, where the cortex remains free from any interstitial changes.

Near the free pelvic surface the connective-tissue cells can be seen forming concentric layers surrounding the tubules that are disappearing in a similar manner to that described as occurring in the specimen of Case 1.

The cases which I have just described show that two distinct histological processes occur in the kidneys in hydronephrosis; the

Digitized by Google

one being the direct result of pressure, and the changes so induced are limited to a thin layer of tissue immediately subjacent to the surface pressed; and the other being a general or interstitial change, identical with that seen in chronic interstitial nephritis, due in part at least, as I hope to demonstrate, to the distension of the pelvis, which by compressing and stretching the renal vessels as they pass into the kidney, interfere with nutrition of the whole organ. The changes induced by pressure occur in every case, and they may or may not be accompanied by the interstitial or general changes above referred to. The former, *i. e.* the changes due to direct pressure, are manifested in a thin layer of tissue below the surface pressed by proliferation of the connective-tissue cells in the intertubular connective tissue, so as to form in the early stages a more cellular structure; and simultaneously with that there occurs a progressive diminution in size and number of the renal tubules in that part. Later, the newly formed connective tissue becomes more fibrous, and the vascularity of the part becomes reduced almost to a minimum. The diminution in vascularity of the tissue immediately subjacent to the surface pressed renders the nutrition of the part insufficient to maintain in activity and full vigour the highly specialised cells of the renal tubules; nevertheless, the nutrition is sufficient for the growth of the connective-tissue elements to fill the spaces that would otherwise be left after the disappearance of the tubules and their epithelial lining. The epithelial cells lining the tubules gradually diminish in size, become clear, and ultimately disappear entirely. All these changes are inseparably associated with one another, and the several stages or transitions in their formation may be seen in such examples as have been described in this paper.

Some parts of the sac in cases of advanced hydronephrosis are lined by the distended and flattened-out calyces, which are themselves lined, under normal conditions, by a layer of transitional epithelium. This epithelial lining of the calyces persists, although the subjacent tissue disappears under the pressure that it is subjected to, and the epithelium merely shows signs of proliferation and irregular growth of its individual cells.

The disappearance of tissue under the influence of gentle and more or less continuous pressure, without ulceration, has been noted since the early days of the study of pathology, and the process has been and now is placed under the term "atrophy from pressure." The

Digitized by Google

term "atrophy" had originally a wide application, but since the observation of microscopic structure has in great part replaced the study of mere naked-eye appearances, and now forms, instead of the latter, the basis upon which the classification of disease in tissues rests, the application of the term has become gradually limited and is likely to become still more so.

However, as it is not my intention in this paper to discuss the question of atrophy from pressure I shall only point out the fact that the changes in the kidney in hydronephrosis resulting from pressure produce disappearance of the renal structure by a definite and demonstrable process,—a process which manifests itself by proliferative changes in the connective-tissue elements of the stroma, in addition to the diminution in size and ultimate disappearance of the epithelial cells of the renal tubules, or what may be termed true atrophy. All previous writers, Virchow amongst the rest, have indeed referred the disappearance of the medulla in cases of hydronephrosis to simple atrophy from the pressure of the accumulated urine in the pelvis, and so far as I am aware no one has described the histological changes associated with the disappearance of the renal structure. I may here quote from several authors who treat of this part of the subject.

Professor Virchow in his 'Krankhafte Geschwülste,' Bd. i, S. 268, makes the following remark:

"Je mehr die Erweiterung zunimmt, um so mehr atrophierte natürlich das Parenchym der Niere, indem die Nierensubstanz theils in Folge des Druckes, theils in Folge des entzündlichen namentlich interstitiellen Processes schrümpft, dünnere und dünnere wird, und zuletzt gar nichts mehr davon übrig bleibt, als ein etwas derber, fibröser mehr kammeriger oder buchtiger Sack."

Dr. Roberts, of Manchester ('Urinary and Renal Diseases'), speaks of the changes in a general way as the following extract shows:

"The stagnating urine exerts its pressure in the first instance upon the papillæ, which become flattened, and as it were, effaced; then the bodies of the pyramids are compressed and gradually atrophied; lastly, the cortex is encroached on more and more until it is reduced to mere islets of reddish tissue on the membranous parietes."

Ziegler sums up the changes in hydronephrosis in the following words (English Edit. by Dr. MacAlister, Art. 552):—"The first

Digitized by Google

results of this accumulation of liquid is the flattening of the papillæ and thinning of the cortex of the kidney. The parenchyma persists for a considerable time but at length undergoes atrophy, the tubules being reduced to flattened or cleft-like channels lined with compressed epithelium, and ultimately with the glomeruli becoming functionless and obliterated. In extreme cases the renal tissue is reduced to a thin fibre or in parts disappears altogether, the sack consisting in great measure merely of fibrous tissue, which in cases of old standing may be of remarkable thickness."

In a recent work by Dr. Newman, of Glasgow ('Surgical Dis. of the Kidney,' p. 119), I find he considers that the destruction of the renal tissue is brought about in one of two ways: (1) by the insufficient blood supply consequent upon the tension of the fluid in the capsules of the Malpighian bodies, and (2) by the pressure of the fluid within the pelvis causing dilation.[1]

In those cases in which the obstruction to the outflow of urine is in the ureter or lower down in the urinary tracts, the pelvis of the kidney usually becomes in the human subject distended to a very considerable extent, especially if the obstruction be of long standing.

In such cases there exists, in addition to the changes induced by pressure, already described, changes similar to those found in chronic interstitial nephritis; however, in cases of advanced hydronephrosis the process has often time to proceed until the whole kidney structure is transformed into fibrous tissue, containing few, if any, remnants of the renal structures. These interstitial or *general* changes, as these may be called, in contradistinction to the pressure or *local* changes, are found to be more or less equally distributed in pyramidal or wedge-shaped patches throughout the affected organ in the earlier stages; later the kidney is entirely converted into fibrous tissue containing functionless knots, the remains of the Malpighian bodies, and small narrow and elongated or rounded spaces containing small granular cells or débris, the remains of the renal tubules. Cases in which the general changes are absent merely show alterations due to direct pressure already

[1] I can find no evidence whatsoever to show that pressure upon the capillary tuft in the Malpighian body is the cause of the changes in and disappearance of the kidney, and I cannot help thinking that Dr. Newman has drawn a too special conclusion from the experiments which he refers to. The changes I describe here do not lend any confirmation to the view put forth by Dr. Newman.

Digitized by Google

described, an instance of which is afforded in Case 4. From the occasional absence of the general interstitial changes in some cases it is, I think, evident that the pressure of the accumulated urine in the pelvis is insufficient to account for the occurrence of these changes. I was led therefore to investigate more closely the conditions under which they occur, and by comparing the naked-eye alterations in the pelvis and kidney with the histological changes in each case, I found that the general or interstitial changes were usually absent in cases in which the body of the pelvis was not at all or only slightly dilated, and present in all cases where considerable or extreme dilatation of the body of the pelvis had occurred.

The distension of the pelvis takes place mainly in a forward direction, that being the direction of least resistance. The pelvis, being placed behind the renal vessels where they enter the hilum of the kidney, as it distends pushes these vessels in front, and so stretches and flattens them. From this stretching and flattening of the renal vessels the circulation through the kidney is diminished, and, in addition to this direct mechanical effect of the distended pelvis upon the renal vessels, there arises, especially in the later stages of hydronephrosis, a thickening of the intima and even of the media from the formation in them of fibrous connective tissue, contributing to a further diminution of the channels for the renal circulation. This thickening of the vessels, especially arteries, may be so great as to diminish the lumen to one half, or even less, of the normal size, and occasionally thrombi form in these altered vessels. This diminution in the circulation of the kidney, brought about in at least two ways, viz.: (1) by direct stretching and flattening of the renal vessels as they pass over the distended pelvis, and (2) by a narrowing of the lumen of the vessels by a kind of arteritis or endarteritis is, I conceive, the chief cause of the general or interstitial changes in the hydronephrotic kidney. It may be also that the branches of the renal vessels running between the calyces and interpyramidal cortex are subjected to the pressure of the accumulated urine, as indeed has been suggested by Cohnheim ('Allgem. Path.,' Bd. ii, S. 400), but, so far as I have been able to discover, this does not seem to occur so often as would be expected. It is quite possible and even very probable that it does occur in some cases. It is, however, difficult to demonstrate, and I have not been able to find any strong evidences in support of the view. These general changes remarked

Digitized by Google

are similar to those changes produced in the kidney by diminution in the vascular supply in old age, and chronic granular kidneys produced by narrowing of the vessels from arteritis; and in order to further illustrate this point I may here refer to a case of unilateral chronic interstitial nephritis, produced by the stretching of the renal artery over an aneurysm of the neighbouring parts of the aorta, the origin of the renal artery being quite free.[1]

Case 5 was that of a soldier, aged 33, who had a large aneurysm on the left and posterior wall of the abdominal aorta opposite the second, third, and fourth lumbar vertebræ. He died from rupture of this sac at one point of its attachment to the eroded bodies of the second and third lumbar vertebræ. The left renal artery had its origin free, and as it passed outwards to its organ it had been carried forwards in front of the enlarging sac, stretched and markedly compressed. The right kidney was of normal size, and presented no abnormal appearances; the left, much smaller, appeared elongated and narrow, its capsule thickened and adherent to cortex; the cortex much diminished, to at least two thirds its normal thickness, and it showed the usual appearances of interstitial nephritis. The left ventricle of the heart was much hypertrophied. All other organs healthy.

Microscopically the right kidney is normal, but in the left the cortex is diminished, and the capsule laminated and thickened; typical wedge-shaped patches of interstitial nephritis, with their bases to the capsule and apices towards the medulla. Between these so-called wedges the renal structure is more or less normal. In the wedges the Malpighian bodies are crowded irregularly together, many already transformed into fibrous knots, and many in the process of becoming so. The renal tubules are small, few in number, and lined by small clear, cubical cells, and some of the tubules contain colloid casts. The intertubular connective tissue is much increased, and consists in the main of fibrous connective tissue; the medulla is also diminished, and the connective tissue between the tubules in places much increased.

In Cases 1 and 2, with much distension of the pelves, the renal vessels were stretched over the sac and flattened from before backwards. This compression necessarily diminished the calibre of the vessel, and superadded to this was a thickening of the tunica in-

[1] I am not aware that such cases have been described, and I can find no reference to such in our text-books nor in scattered literature.

Digitized by Google

tima and media from the formation of fibrous connective tissue, which contributed to a further diminution of the calibre of the vessel. I venture to suggest, after the evidences I have brought forward above, that the general interstitial changes are in the main induced by compression of the renal artery as it passes over the much distended pelvis, causing a gradual diminution in the arterial supply of the kidney.

In Cases 3 and 4 the only place where such a compression could be exerted is between the calyces and interpyramidal cortex. Although parts of the hydronephrotic portion of the kidney in Case 3 shows the usual interstitial changes, yet other parts of equal if not greater extent show no evidence of such changes, and in Case 4 no trace of general interstitial changes can be seen, but only interstitial changes (local) due to pressure near the pelvic surface.

---

7. *Calculus in ureter; disorganisation of kidney.* (*Card specimen.*)

By F. D. Drewitt, M.D.

The calculus was the size of a bean. It was impacted in the left ureter one inch from the bladder, this portion of the ureter being obliterated. The left kidney was dilated and completely disorganised, while the right was in a condition of acute nephritis. Death resulted from uræmia.

The patient was a child 12 years of age.

January 29th, 1889.

---

8. *Malposition of left kidney.* (*Card specimen.*)

By A. Primrose, M.B.

The abnormality was discovered in the dissecting room of the University of Toronto, Canada. The subject was that of an adult male, coloured. It was impossible to obtain any previous history of the individual.

Digitized by Google

The kidney was situated over the left sacro-iliac synchondrosis. The following is a detailed account of its anatomical relations: The aorta divides into the common iliac arteries one eighth inch below the upper border of the body of the fourth lumbar vertebra, and the upper extremity of the kidney is one and a quarter inches below the bifurcation. The inner border of the kidney, in its lower half, lies to the extent of one quarter inch across the middle line of the body; the remainder of the kidney is to the left of the middle line. The lower extremity of the kidney lies opposite the upper portion of the first piece of the sacrum.

The kidney lies upon the iliac vessels of the left side. The common iliac and external iliac vessels separate it from the psoas muscle, which lies to its outer side. Behind it further are the expanded lateral mass of the first sacral vertebra, and the sacro-iliac synchondrosis. The lower end of the organ dips into the true pelvis, projecting half an inch beyond the brim. The kidney was bound down in this unusual position by loose areolar tissue.

The lower end of the kidney is thick and rounded, and is larger than the upper end. A deep triradiate fissure on the anterior surface divides the kidney-substance into three lobules of unequal size. This fissure, in which lie branches of the renal artery, extends in depth about half way through the total thickness of the organ. The size of the kidney is as follows:—Length, four inches; breadth, two and a half inches; thickness, one inch.

There are three renal arteries. 1. A vessel arising from the bifurcation of aorta anteriorly. This artery runs downwards and outwards, and lies in a fissure on the anterior aspect of the kidney. It gives off a branch which enters the cortex directly at the upper extremity of the kidney, and the vessel then continues on to the end at the hilus. 2. Arises from posterior aspect of aorta, one quarter inch above bifurcation. This vessel runs downwards in front of left common iliac vein, and splits into two branches which enter, close together, directly into the kidney-substance along its upper and inner border. 3. A third artery comes off the middle sacral artery about half an inch from the origin of that vessel from the aorta. Its course is downwards, passing behind the left common iliac vein. A branch enters the kidney at its inner border, and the vessel terminates at the hilus. This artery, at its termination, lies behind the ureter, and in front of the renal vein.

The renal vein arising at the hilus behind the artery last

Digitized by Google

described, crosses above that vessel, and passes over to enter into the right common iliac vein.

The ureter arising in front of artery No. 3 courses down over the anterior aspect of the lower portion of the kidney, and enters the bladder in the normal position.

The position of the structures therefore at the hilus of the kidney, from before backwards is:—Ureter, artery, vein, or, in other words, the reverse of normal. This circumstance, coupled with the fact that the larger end of the kidney is downwards, leads one to suppose that the kidney had been completely turned over.

The rectum occupies the middle line of the body, and overlaps to a slight extent the inner border of the kidney. The sigmoid flexure begins over bifurcation of aorta and lies immediately above kidney, where it is bound down by peritoneum. The right kidney and ureter were normal in position and size.

The instances of misplaced kidney are rare. Mr. Henry Morris states the average to be probably one in every thousand bodies.

April 16th, 1889.

---

9. *Stricture of urethra, death caused by a false passage made by the patient.* (*Card specimen.*)

By Frank Penrose, M.B.

P. H—, aged 38, was admitted into St. George's Hospital, under Mr. Rouse, in the early morning of January 30th, much collapsed, and died without rallying.

The history given was as follows:—For many years he had suffered from stricture, and two years ago had extravasation of urine into the perinæum. For this he underwent an operation at St. George's Hospital, which relieved him so much that he is believed to have had no difficulty in passing his urine until January 29th, 1889, on which day he tried once in the afternoon to pass an old silver catheter, but unsuccessfully. In the evening he made a second attempt and brought away some blood and urine. About three hours later he became much collapsed, and was then admitted to the hospital.

Digitized by Google

The specimen shows the false passage above the stricture in the floor of the urethra. The middle part of the urethra is quite blocked, and urine has passed along a new channel through connective tissue to the left of the urethra, and along this the patient must have passed the catheter. *March 5th*, 1889.

---

10. *Case of vesiculation of the mucous membrane of the bladder.*

By Quarry Silcock, M.D.

[With Plate XII.]

Scattered over the surface of the mucous membrane of the bladder exhibited were numerous cysts, varying in size from a small pin's head to that of a small pea; they were most numerous over the base, especially so towards the neck, and a few were apparent in the mucous membrane of the prostatic portion of the urethra where it debouched into the cavity of the bladder. At the time of the autopsy the vesicles contained a clear serous-like fluid, in some cases apparently blood stained. The muscular wall was somewhat hypertrophied, and the mucous membrane generally was somewhat thickened, otherwise no noticeable abnormality of the viscus presented itself, except that the lower end of the right ureter was blocked by an impacted calculus, immediately above the point where it entered the bladder wall.

The specimen was obtained from the body of a man who died in St. Mary's Hospital a few hours after the operation of nephrectomy, the kidney removed being completely disorganised by long-standing calculous disease. The kidney had been cut down upon five years previously, but a careful exploration had failed to reveal the presence of a stone. Three years later (in September, 1887), a large renal abscess was opened, but again no stone was found. Since that date a sinus leading down to the kidney had remained, all efforts which were made to induce the closure thereof proving useless. Consequently, the removal of the organ was determined upon, and carried out on February 5th, 1889.

Digitized by Google

The right ureter, at the autopsy, was found to be immensely dilated, and its walls greatly thickened. In its lower end, as already mentioned, two calculi were firmly impacted; in the pelvic portion of its course it was blended with and surrounded by tough cicatricial tissue, which formed a large sausage-shaped tumour in this region. In the mucous membrane of the ureter above the impacted calculi were a few small cysts, like those described as existing in that of the bladder. The left kidney and ureter were normal.

Looking to the history of the case, and the *post-mortem* appearances, there can be but little doubt that the calculi had been impacted in the lower end of the ureter for some years. The urine examined immediately before the final operation was acid, of specific gravity 1013; but previously it had from time to time been mingled with much pus.

Sections kindly prepared for me by Dr. Reid, showed that the vesicles appeared to originate in foci of epidermal cells, the result of a rapid local proliferation, the central cells of these little epidermal nodules becoming granular, and finally undergoing disintegration and liquefaction, so accounting for the granular contents of the vesicles (Plate XII, fig. 1.) In some of the vesicles blood-pigment granules were observed. The walls of the vesicles were in all cases formed of and bounded by stratified epithelium cells, which became flattened out as the vesicle increased in size. The epithelium in the vicinity of the vesicles appeared to be in an active state of proliferation, and the mucous membrane generally showed evidence of inflammation in the presence of a small-celled infiltration more marked in some localities than in others. The occurrence of vesicles in the mucous membrane of the bladder is rare. Rokitansky, however, stated the fact that he had occasionally met with the condition, but he offered no explanation of the pathology of the lesion. Indeed, no valid explanation can be given in the present instance. Possibly the passage of abnormal or excessively irritating urine over the mucous membrane may have caused the formation of the vesicular eruption; possibly it may have arisen through reflex nerve irritation, induced by the impaction of the calculi in the ureter. *May 7th*, 1889.

Digitized by Google

Digitized by Google

Fig. 1

x 40

M H Lapidge del.

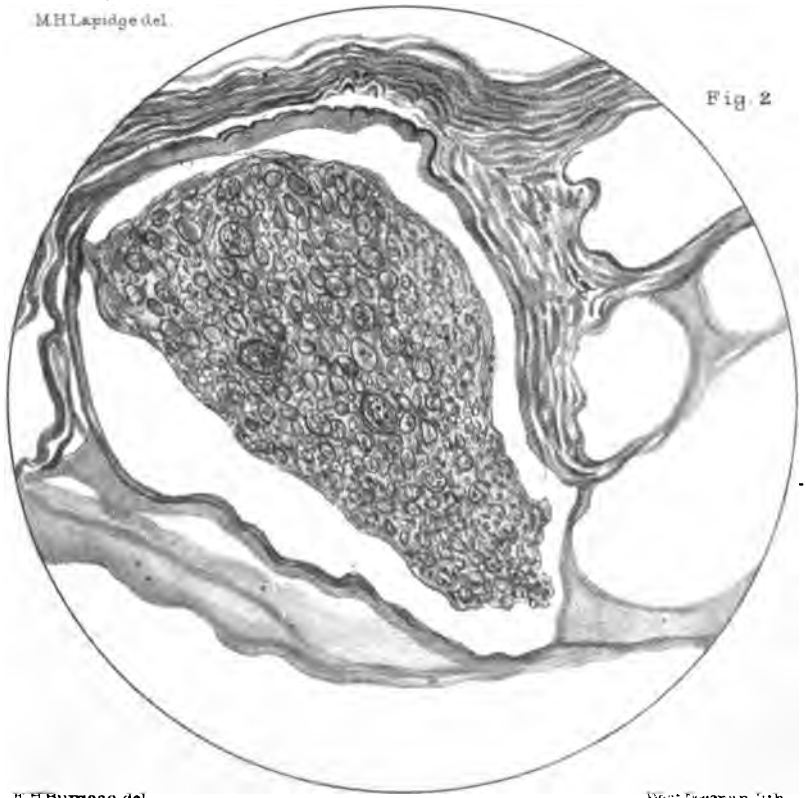

Fig. 2

E H Burgess del.

x 360

West Newman lith

Digitized by Google

DESCRIPTION OF PLATE XII.

FIG. 1.—To illustrate Mr. Silcock's paper on Vesiculation of the Mucous Membrane of the Bladder. (Page 175.)

Section through the mucous and muscular coats of the bladder, showing the formation of vesicles.

a. Fully-formed vesicle.
b. Vesicle in process of formation.
c. Muscular coat.

FIG. 2.—To illustrate Mr. Eve's case of Psorospermial Cyst of the Ureters. (Page 444.)

Vertical section of a ureter, showing several psorospermial cysts cut across. The largest cyst contains a mass of mucoid material, which is studded with ovoid bodies having the characters of pseudo-navicellæ.

Digitized by Google

Digitized by Google

11. *Epithelioma of the male urethra.*

By Joseph Griffiths, M.B.

It is on account of the rarity of a primary epithelioma of the urethra that I venture to bring this example before the Society. It may be indeed that this affection of the urethra is not so rare as our larger and more extensive works on surgery would lead us to suppose. Secondary epitheliomatous invasion of the urethra by direct extension from neighbouring parts is not at all uncommon, and especially common is the affection in those women who have suffered from epithelioma of the cervix uteri. In this case, as will be shown, the disease affects the penile portion of the urethra and I could not detect any evidences to show that the affection originated elsewhere than in the urethra.

On referring to 'Holmes' System of Surgery' (vol. iii, p. 225) I find that Sir Henry Thompson says:

"First, that the existence of any excrescence so large as to attract observation as an independent growth in the urethra is extremely rare.

"Secondly, that these bodies consist either of (*a*) vascular granulations; (*b*) polypoid formations peculiar to the prostatic part of the urethra; or (*c*) masses of tubercular and cancerous origin, always secondary to primary disease elsewhere."

In Billroth and von Pitha's 'Handbuch der Chirurgie' no mention is made of a primary malignant disease of the urethra. I have further searched in the scattered literature and have so far been unable to find any record of a similar affection of the urethra. I shall next briefly refer to the clinical notes of the case.

G. S—, aged 70 years, was admitted into Addenbrooke's Hospital, Cambridge, on March 31st, 1887, under the care of Professor Humphry. He was sallow and much emaciated and complained of numerous sinuses in the perinæum, together with a brawny hard swelling in the region of the ischio-rectal fossa.

There was no history of gonorrhœal attacks, syphilis, or any injury to the perinæum, and he had never suffered from any urethral trouble until eight or nine weeks previous to admission. Since that time he had suffered from pain during the act of micturition and had experienced some difficulty in expelling

Digitized by Google

his urine; this difficulty gradually increased. He had never noticed any blood either at the beginning or the end of the stream, nor had he observed any bloody discharge. The urine never escaped through any of the openings in the perinæum. The urine contained a small amount of albumen but no pus, blood or sugar.

Soon after admission, a very hard, slightly tender swelling with rounded ill-defined margins was found to occupy the position of the bulb and corpus spongiosum a short distance along the penis; the corpora cavernosa were found implicated by a similar swelling to about an equal extent. A catheter was passed with some difficulty which was especially marked at the bulb, and without much pain; a little blood was afterwards passed from the urethra.

This hard swelling gradually increased in size, and simultaneously the difficulty in expelling urine became more pronounced. At this time some urine was seen to escape from some of the perinæal openings. On May 10th, 1887, another hard symmetrical swelling was found at the junction of the scrotum and perinæum in the middle line; this swelling was about the size of a small Spanish chestnut, but not so hard as that which occupied the structures of the penis. It became very prominent and the skin over it reddened. On May 20th perinæal section was performed to relieve the urinary troubles, the finger in the rectum being used as a guide.

The patient had been gradually losing flesh, and on June 3rd, 1887, was seized with an attack of hemiplegia, and died on June 6th.

Post mortem all the organs were in the state found in chronic Bright's disease, viz. granular kidney, hypertrophied heart, and cerebral softening. The penis, perinæum, bladder, and symphysis pubis were removed in one piece and hardened. The following is the condition of those parts.

A median longitudinal section of the bladder, rectum, and penis shows that the posterior two thirds of the corpus spongiosum and the posterior half of the corpora cavernosa, which bodies retain their outline throughout, are entirely replaced by a firm, dense, and whitish new growth. The corpus spongiosum is nearly half an inch in thickness in the region of the bulb, and beyond the middle of the penis the amount of new-growth tissue gradually diminishes, and ceases about an inch from the corona of the glans. The urethral canal has been transformed into a narrow, irregular slit,

Digitized by Google

traversing the altered and thickened corpus spongiosum. In front of and below the posterior half of the penis the skin and subcutaneous tissues are much thickened and hard, this being in great part due to the formation of old fibrous tissue. There are no evidences whatever that point to the fact that the growth originated in this situation, and attacked the parts of the penis subsequently. The corpora cavernosa are completely replaced by the new growth in the posterior half of their extent, and it is somewhat strange that the anterior extremity of the growth is marked by a defined and abrupt line. Extending from the perinæum into the bladder is the canal made at the operation to relieve the patient's symptoms. From this canal inflammation had extended into the loose cellular tissue between the bladder and symphysis pubis, where a large collection of pus had formed, and was the more immediate cause of death. The prostate remained unaffected; the bladder is very contracted, hypertrophied, and in a state of chronic cystitis. There were no secondary growths in the body, nor any enlarged glands. The growth proved to be, on microscopical investigation, an ordinary squamous-celled epithelioma.

In conclusion, I desire to express my thanks to Professor Humphry, under whose care the patient was, and for permission to bring the case before the Society. *February 5th*, 1889.

---

12. *Encysted prostatic calculi.*

By W. Bruce Clarke, M.B.

E. H—, aged 67, first came under my care in 1885, suffering from symptoms of stricture. He had been in the habit of using a catheter for some years previously, but had neglected to pass his instrument and consequently the stricture had undergone rapid recontraction.

As he had a very severe rigor after the passage of his instrument, external urethrotomy was performed. I did not come across him again until he returned to place himself under my care early in 1887. He was then suffering from very severe cystitis, his urine was foul, and he was obliged to get up many times in the night to pass his water. There was no difficulty in introducing the No. 12 catheter which had been given him two years pre-

Digitized by Google

viously, and he was put to bed, and his bladder washed out two or three times daily. His symptoms speedily diminished in severity, but they did not entirely disappear. His bladder was very carefully examined with a sound, but without detecting any calculus. As he became gradually worse under the washing-out treatment, an incision was made in the perinæum, and the prostate was also divided on its floor with a view to exploring the whole of the interior of the bladder, but without result. His death took place some few weeks later from suppression of urine, and at the *post-mortem* examination the urinary organs were found in the following condition:

The kidneys were small and contracted, and the pelvis of the kidney was considerably larger than natural. The ureters were much dilated and contained a good deal of pus. The interior of the bladder was not rugose, but revealed on its back wall the tip of what turned out on further examination to be a calculus embedded in the back wall of the bladder. A considerable incision had to be made in the wall of the bladder before the calculus could be extracted. The exposed tip of the stone lay just above the level of the ureters, but the cavity in which it lay passed down towards the prostate. The calculus weighed in the moist condition 322 grains, or rather its fragments amounted to this weight, for it was broken into pieces during the process of removal. On examination of the fragments it was perfectly clear that the bulk of the calculus was phosphatic in character, but a small nucleus was present in the centre which was similar to the small stones about the size of a millet seed which are so often found in the prostate after death, and have been described by Sir Henry Thompson and other authors who have treated the subject of the prostate gland. These usually consist, as is well known, of about 85 per cent. of phosphate of lime, the remainder being made up of animal matters with a small proportion of carbonate of lime.

On further examining the prostate, a considerable number of small calculi of a millet-seed shape and size were found in its interior, and they were exactly similar both in chemical composition and in appearance to the nucleus of the stone which had given rise to all the patient's trouble.

In many ways the case resembles that of a patient whose case was related by Mr. A. W. Storks in the 'British Medical Journal' for October 28th, 1882; but in this case there was more than one

Digitized by Google

calculus in the bladder, and some of the bladder calculi underwent spontaneous fracture and were passed *per urethram*.

The chief interest in the case centres on the fact that it seems to show that a prostatic calculus may form the nucleus for a calculus in the bladder, or, to put the matter more exactly, it would seem most probable that the nucleus, at first prostatic in origin, found its way towards the surface of the bladder, or into one of the numerous recesses of the prostate where the urine could come into contact with it, and so form a deposit round it. At first this deposit took place within the prostate, and formed a bed for itself, whilst later on it partially protruded into the bladder cavity, and there gave rise to the symptoms above detailed. That such a sequence of events often ensues it is by no means suggested, but probably the presence of encysted calculi at the base of the bladder may be best explained in the manner which I have just described. *October 16th*, 1888.

---

18. *Cancer of prostate.* (*Card specimen.*)

By Berkeley Hill, M.B.

History.—From a man, aged 64, who had had a long history of gravel. Hæmaturia twelve months. Incontinence of urine twelve months. Had an instrument passed in Teneriffe September 26th, 1888. Sailed for England September 27th, 1888. He passed no urine (only a few drops of blood) after September 29th, 1888.

October 5th.—Treated with jaborandi and hot-air baths.

8th.—Examined under anæsthetic. Left kidney felt, and a nodule in right lobe of prostate, which was very hard. A few drops of bloody urine drawn.

9th.—Patient died suddenly. No fits; no sickness; no twitching; no elevation of temperature. After suppression of urine for ten days.

Specimen consists of kidneys, ureters, bladder, &c. There is a firm new growth of the prostate invading the walls of the bladder, which is very small. The internal surface of the bladder is shaggy, with a few phosphatic concretions.

Walls of bladder at fundus thin, where a piece of intestine is adherent. Around base much thickened by invasion of new

Digitized by Google

growth from prostate. Orifices of ureters pervious. Ureters and kidneys dilated.

Microscopically growth consists of an abundant stroma of fibrous tissue, containing large numbers of spindle-cells. The stroma encloses spaces which are filled with groups of glandular epithelium cells. *December 4th*, 1888.

---

14. *Cystine calculus.*

By Anthony Bowlby.

The calculus was removed, by the operation of lateral lithotomy, from a boy aged 3, who had suffered from symptoms of stone for about nine months. It is oval in shape, and weighs 150 grains. The surface is crystalline and rough, like a piece of loaf sugar. The colour is a honey yellow, and the section homogeneous. Chemical analysis shows that the stone is composed throughout of pure cystine.

The patient made a good recovery, and the urine was subsequently tested daily for several weeks. It was passed in full quantity; the specific gravity was about 1020, its reaction acid, and it constantly contained a large quantity of cystine crystals, which did not vary in amount, though the child was placed on very various diets.

The father of the patient had been cut for stone when a child.

May 21st, 1889.

---

15. *Abscess of epididymis.* (*Card specimen.*)

By A. Marmaduke Sheild, M.B., B.S.

One large and several smaller tubercular abscesses occupy the epididymis. Removed by operation from a young man who had suffered from caries of the sternum, and who also suffered from psoas abscess. The connection between psoas abscess and tubercular disease of the testis has been remarked.

March 5th, 1889.

Digitized by Google

16. *Chylous fluid removed from tunica vaginalis.* (*Card specimen.*)

By SYDNEY JONES, M.B.

THIS fluid was removed on July 4th, 1887, from a Hindoo, aged about 35.

The right side of the scrotum, much distended, was not transparent, but had distinct fluctuation. When tapped this fluid was evacuated. About six weeks later, the same quantity of a similar character was evacuated.

The following is the analysis by Dr. Bernays:

"Chylous-like—strongly alkaline—spec. grav. 1020. The fat smelt of perspiration. Water extracted from it (2·51) a small quantity of a syrupy acid answering to sarcolactic acid.

Total solids	9·21
Total ash	0·87
Serum albumen	5·58
Fat	2·51
Extractive	0·25
Sodium chloride	0·63
Phosphatic chloride	0·24
Water	90·79

The extractive consists of an undetermined form of albumen."

Microscopically no filaria could be detected in blood; not examined at night. *January 15th*, 1889.

---

17. *Extra-vaginal hæmatocele of scrotum.* (*Card specimen.*)

By F. S. EVE.

THE specimen was presented to the Royal College of Surgeons' Museum by Mr. W. Rivington. It was dissected by the exhibitor, who described it as follows in the catalogue:

"4299. A hæmatocele in the cellular tissue of the scrotum. Two large cysts, extending upwards around the spermatic cord, occupy

Digitized by Google

the front and back surfaces of the preparation; they are distinct except at their upper part, where they communicate by a small opening, and their walls are covered with coloured blood-clot The testicle, exposed by an incision, lies below the cysts; its substance is healthy, but the cavity of the tunica vaginalis is obliterated by adhesion of its surfaces, except above the testicle, where a small cavity exists, which could not be ascertained to communicate with the cysts, and did not contain blood-clot. By dissection it was distinctly ascertained that the walls of the cysts were formed by the layers of connective tissue of the scrotum.

"The specimen was removed from a man aged 57 years. Sixteen years before the operation the left side of his scrotum became swollen after the kick of a horse; the swelling subsided under treatment. Three years later he again injured his scrotum, and since then it had gradually enlarged. Two months before he came under observation he received a blow from a piece of timber. The scrotum was greatly enlarged, opaque, and fluctuating; it was tapped, and 60 oz. of fluid resembling chocolate were removed, the swelling still remaining half the original size. Complete removal of the mass with the testicle was then performed."

Beside this is a precisely similar specimen from the same Museum (No. 4300), which was described by Mr. Arnott in the 'Transactions' of this Society, vol. xxii, p. 184. In this case a lump formed in the left testicle, and gradually increased; it was removed eleven months after it was first observed. Curling mentions several cases of hæmatocele of the cord from rupture of a spermatic vein or injury; one being a case of Bowman's in which the tumour extended as low as the knee. Monod and Terillen (1889), like Curling, describe diffused hæmatocele of the cord, but do not mention it as occurring in the scrotum.

In both the specimens exhibited the effusion of blood appears to have taken place in the loose cellular tissue of the scrotum; in Arnott's case it is distinctly stated that the swelling appeared near the testicle; and in the recent specimen, No. 4299, it was stated that the scrotum became swollen after a kick; yet it is quite possible that blood may have gravitated from a ruptured spermatic vein.

The recent specimen is also remarkable from the long duration of the swelling, viz. sixteen years, and its consequent complete encapsulation. *February 19th*, 1889.

Digitized by Google

Digitized by Google

Fig. 3.

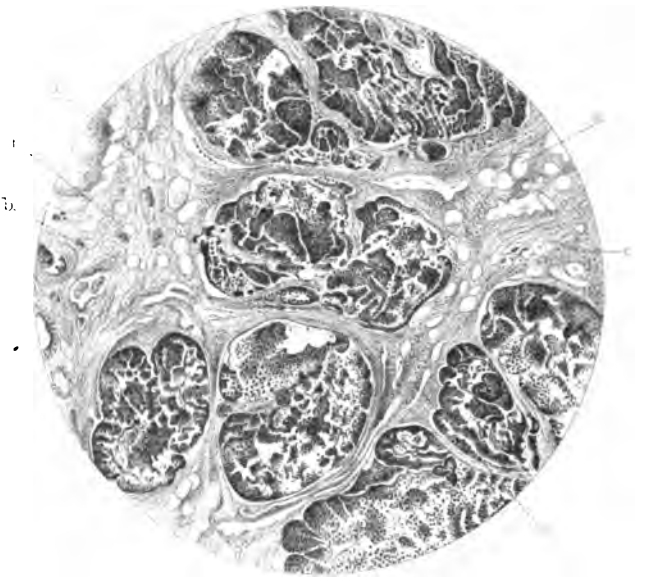

Fig. 2

Fig. 1.

Digitized by Google

DESCRIPTION OF PLATE XIII.

Fig. A.—To illustrate Mr. Doran's account of a case of Primary Cancer of the Fallopian Tube. (Page 221.)

Section of a carcinomatous mass on the stump of the left tube, which was free from cancer when the operation was performed (see text), showing collections of large cells in wide spaces, bounded by broad trabeculæ.

a a. Circular holes in the trabeculæ.

b b. Cells occupying similar holes. These cells appear under a high power identical with those which fill the large alveolar spaces.

c c. Small-cell infiltration in the trabeculæ. ($\frac{1}{2}$" obj.)

Figs. 1 and 2.—To illustrate Mr. Spencer's paper on Varicocele. (Page 185.)

Fig. 1.—Spermatic veins. Left cord above epididymis. Fœtus, 7th month. Veins of various sizes partly filled with blood.

A. Artery.

Fig. 2.—Spermatic veins of right side, just above epididymis. Boy 12.

A. Artery.

v. Vein.

vas. Vas deferens.

Digitized by Google

Digitized by Google

Digitized by Google

Fig 3a

Fig 3b

Fig 4b

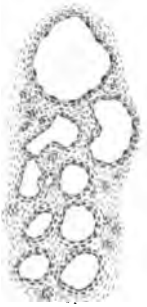

Fig 4a

Fig 5



Fig 6.

Mintern Bros. sc.

Digitized by Google

DESCRIPTION OF PLATE XIV.

To illustrate Mr. Spencer's paper on Varicocele. (Page 185.)

FIG. 3 *a*.—Spermatic veins of right side.

FIG. 3 *b*.—Spermatic veins of left side.

A. Artery.

v. Vein.

vas. Vas deferens.

FIG. 4 *a*.—Spermatic veins above testis of right side. Fœtus, 6th month, undescended. Small veins.

FIG. 4 *b*.—Spermatic veins of left side. Large veins with small ones amongst these.

FIG. 5.—Spermatic veins of left side above testis. Child, 6 years.

1. Veins of considerable size.
2. Minute veins.

o. Group of cells arranged concentrically.

FIG. 6.—Spermatic veins of right side, one inch above epididymis. Man, 25 years.

v. Veins.

o. Group of cells arranged concentrically.

Digitized by Google

Digitized by Google

18. *Varicocele, a spontaneous variation in the spermatic veins.*

By W. G. Spencer, M.S.

[With Plates XIII and XIV.]

A number of transverse sections at various levels have been made of the spermatic cord at all ages. Over twenty sections and specimens were shown to the Society. Three chief points are illustrated by them:

A. The large number of veins of all sizes present in the spermatic cord at all ages.

B. The number and size of the veins, greater on the left side than on the right.

C. The presence, on the right side especially, of very minute veins, of other veins in which the lumen is imperceptible, and amongst these groups of cells arranged in a concentric manner as if representing obliterated veins.

A. The spermatic veins are at first the veins of the Wolffian body, a very vascular organ. Statistics and clinical experience show that every variety exists between veins which can be just felt and the largest varicocele. Examinations of the whole French male population are made for the army, and of these about 3·2 per 1000 require treatment for varicocele before entering. A very large number of men are admitted without treatment because the presence of varicocele is not inconsistent in them with active service. The ratio of varicocele consistent with active service to those not so is by some put at 400 or 500 to 1. Some have found varicocele in 60 per cent. of all those examined. Varicocele is found in childhood, and very frequently before puberty. The large size frequently of the veins in childhood is to be seen during the operation for the radical cure of hernia in male children. Mr. Sutton has found similar conditions in animals to those in man. Varicose veins and nævi are variations from the normal; like varicocele, these variations take place during development. Varicocele, varicose veins, and nævi are capable of being inherited. For the reasons given above, varicocele appears to be a "spontaneous variation" in the spermatic veins.

Digitized by Google

All the conditions called at present "causes" of varicocele are not really such; they merely keep filled with blood veins already present. A large number are anatomical in character; how can conditions which exist in all be the cause of disease in some? The increased vascularity at puberty is natural; it cannot itself cause disease, but it may tend to fill veins which are already present, and hence cause varicocele to appear at puberty. Anything increasing the blood supply to the testis or obstructing its return may fill veins already present. The position of the sigmoid flexure and the passage of fæces is also a natural condition; there are no recorded cases of the supposed collection of fæces in the sigmoid flexure. Mr. Gould believes that a true venous hypertrophy takes place at puberty, and that there is an increase not only of fibrous tissue but also of unstriped muscle in the walls of the veins.

B. It is interesting, with respect to the greater number of varicoceles on the left side, to note that the left kidney and testis are larger, and the latter more advanced in its development than the right. This may have to do with the persistence of the left arch of the aorta in the embyro, whilst the right arch becomes obliterated. This persistence is referred to an origin by "spontaneous variation" from a condition far back in the history of the race when the two sides were equal. It may be that whilst the left arch is increasing and the right decreasing the arterial supply is greater on the left side until the fully-formed median aorta equalises the circulation. No vena cava is formed on the left, but the vein has to join the left renal vein and cross the vertebral column. The embyro is said to lie constantly on its left side.

C. On the right side the very minute veins and the groups of concentrically arranged cells appear to take the place of many of the larger veins on the left. In some sections from the left side the veins are not very much larger than on the corresponding right, and in these the above conditions are seen also on the left side. But where on the left side the veins are numerous and large the appearance of very minute veins, or concentric groups of cells, is scarcely seen. The apparent obliteration of veins is seen in young specimens following the disappearance of the Wolffian body. An arrest in a retrograde process thus seems to leave many veins persistent. In other words, the variation in the number of the spermatic veins is in inverse ratio to the amount of obliteration.

October 16th, 1888.

Digitized by Google

19. *Paget's disease, affecting the scrotum and penis.*

By H. Radcliffe Crocker, M.D.

[With Plates XV and XVI.]

James D—, a whitesmith, aged 60, attended University College Hospital first as an out-patient in April, 1887. On the front and left side of the scrotum and on the contiguous under surface of the penis there was an oozing, well-defined area of superficial ulceration. At first sight it was something like an eczema, but the lesion was deeper and more sharply defined than would be expected in that disease, and although there was no corroborative evidence, specific treatment was therefore tried thoroughly, but without any good effect. Various non-specific remedies in the shape of powders, lotions, and ointments were also tried, but without the slightest real benefit; the diseased area gradually extended, especially on the left side.

As the removal of the dressing was a long and painful process a complete examination of the disease was not made at each visit, but at the end of November two small nodules were observed in the excoriated area, which at once suggested the malignant nature of the affection, and he was admitted as an in-patient for the removal of it.

At that time the lesion extended over nearly the whole of the left half of the scrotum, except the posterior surface; above, it reached up to the pubes on the inside, over the whole part adjacent to the thigh, and in front, as far as could be seen without raising the scrotum.

On the right side it formed only a patch, separated below by sound skin from the affected left side, but joined to it above, where the penis and scrotum were in contact, the skin of nearly the whole of the under surface of the penis being also involved.

The general aspect remained the same, viz. a superficially ulcerated, easily bleeding surface, with well-defined borders, and here and there pearly-white islets, in which the epithelium had escaped destruction, while a serous discharge was constantly oozing from it. The nodules alluded to were situated close together on the left

Digitized by Google

side of the raphe. The largest began about seven weeks previously, and was then about half an inch in diameter, with a shallow fissure on its upper border; it was firm to the touch and covered with a yellow secretion.

The more recent and smaller nodule was the size of a large pea, and possessed similar characters to the other; neither these nor the raw surfaces were painful, except that the latter smarted and throbbed when first dressed. There were no enlarged glands in the neighbourhood. The patient was a healthy-looking, well-nourished man, and but for this affection had nothing to complain of. There was nothing in his occupation or habits which suggested a predisposing or exciting cause, and he himself stated that it began spontaneously in the summer of 1886 as a raw surface at the root of the penis and adjacent scrotum.

He was treated in vain by several doctors, and also attended at the Lock Hospital, where he was sent on to University College Hospital.

Prior to operative interference the man was shown to the Dermatological Society, where its similarity to Paget's disease was admitted by several of the members, and subsequently Sir James Paget kindly consented to see him, and concurred in its being analogous to the nipple disease identified with his name, and he recommended the removal of the whole of the diseased area. This was carried into effect on December 20th by my colleague Mr. Godlee, and although, owing to the large surface, the process of healing occupied some time, by February 6th it was so nearly accomplished that he was made an out-patient again until healing was completed. I saw him in July, when the cicatrix still remained sound, and the man gratefully expressed himself as quite well.

Microscopical investigation.—Portions of the excoriated skin and the two nodules were hardened in a fluid consisting of equal parts of one sixth per cent. chromic acid solution and alcohol, and afterwards in pure alcohol. The sections were stained in hæmatoxylin, and gave the following results:

The skin, which was simply ulcerated, had for the most part only a thin layer of epidermis left, and here and there even that was wanting, while on the other hand islets of epidermis, almost intact or somewhat thickened, were scattered about, but there was nowhere any notable downgrowth of the epithelium.

Below the epidermis the papillæ were obliterated, and the whole

Digitized by Google

Digitized by Google

DESCRIPTION OF PLATE XV.

To illustrate Dr. Radcliffe Crocker's paper on Paget's Disease Affecting the Scrotum. (Page 187.)

The whole patches on the raw surface are islands of epidermis, spared by the surrounding ulceration. The yellow masses are the two tumours described in the text. They were not yellow as depicted in the plate, but nearly the same colour as the rest.

Digitized by Google

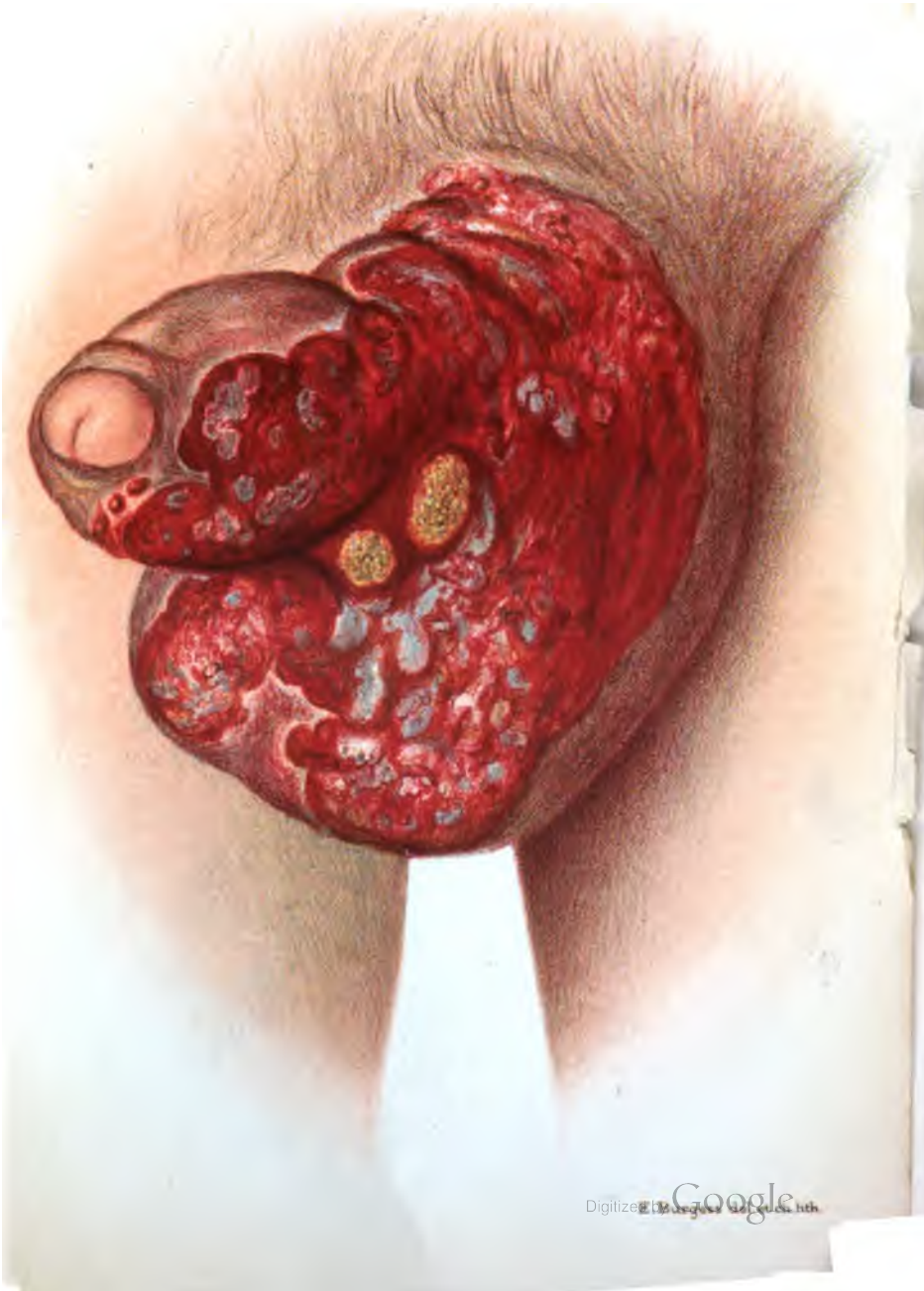

Digitized by Google

Digitized by Google

Digitized by Google

DESCRIPTION OF PLATE XVI.

To illustrate Dr. Radcliffe Crocker's paper on Paget's Disease affecting the Scrotum and Penis. (Page 187.)

FIG. 1.—Portion of large nodule from the scrotum. Obj. 2 in., ocul. No. 3.

a. Epidermis still intact, with only moderate down-growth of the rete Malpighii.

b. Ulcerated part, showing only round-cell infiltration with dilated vessels at the surface.

c. Acini, with small epithelial-cell contents.

FIG. 2.—Two acini, with epithelial contents, more highly magnified. Obj. ⅛, ocul. No. 3.

FIG. 3.—Sweat-coil, with commencing cancerous change. Obj. ⅛, ocul. No. 3.

Digitized by Google

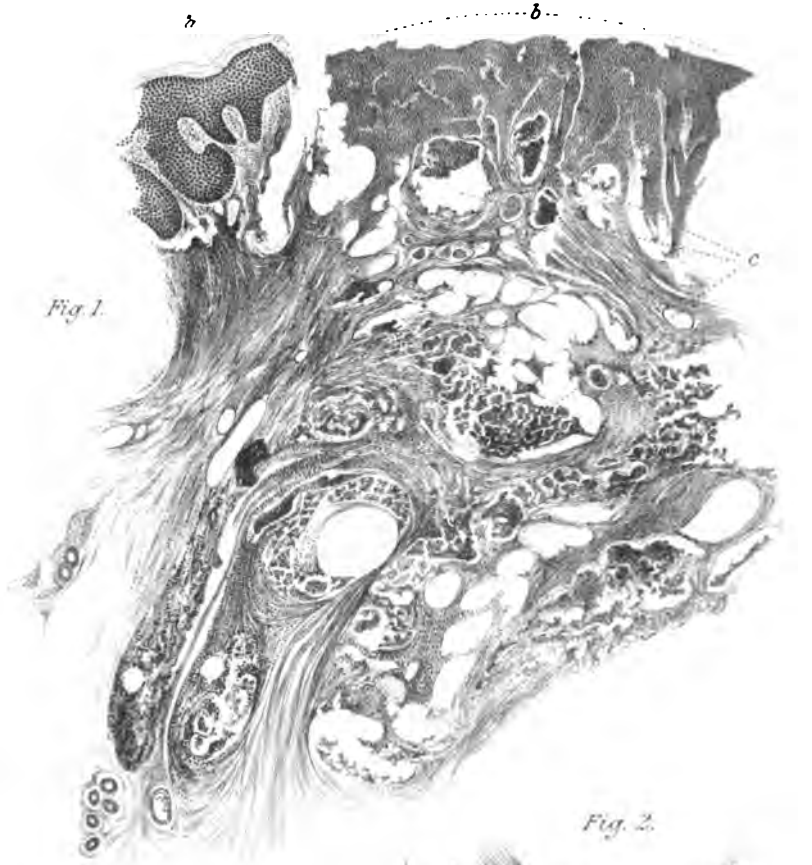

Fig. 1.

Fig. 2.

Fig. 3.

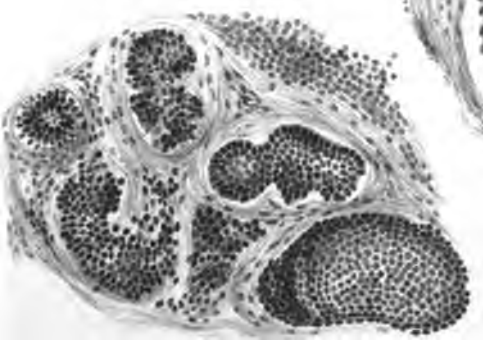

A Damelsson del

F. Huth, Lith^r Edin^r

Digitized by Google

Digitized by Google

structure of the upper part of the corium replaced by a dense infiltration of exudation-cells.

In the upper portion of the corium the cells were less dense, and were, for the most part, in lines perpendicular to the surface, and portions of vessels, sweat-ducts, and fibrous tissue could be seen between the cells. With the exception of occasional foci round vessels and sweat-coils, the exudation-cells ceased at about the level of the dartos. The rest of the tissues were healthy, except that in some of the sweat-coils there were signs of internal proliferation of the lining epithelium.

The large nodule showed in the greater part of the tissue a distinctly cancerous structure, consisting of alveoli containing small epithelial cells closely aggregated together, containing one or more nuclei. The general run of the alveoli were small and roundish, but some were much larger than the rest, and elongated or ovate; in these last the outermost cells had a radiate arrangement similar to those seen in rodent ulcer. There was great variety in the arrangement of the alveoli, and in the thickness of the walls in some parts the alveoli were so closely aggregated, and with so little intervening stroma, that it resembled encephaloid. In others the stroma between the cell-masses was much thicker, and the fibrous tissue more developed. In the greater part of the nodule the cancerous structure reached quite up to the surface, and was nowhere below the dartos, but here and there large cell-foci were buried in the deeper part of the skin or in the subcutaneous tissue; this condition was, however, much more marked in the small nodule.

The process of conversion of the sweat-coils and ducts into the cancerous structure could be distinctly made out in some sections, but it could not be determined whether this was primary or secondary. The larger masses were probably derived from the hair-follicles or sebaceous glands, but there was not such distinct proof of this as in the case of the sweat-coils. Where the epidermis was intact in the part adjoining the cancerous structure there was some thickening and slight downgrowth of the interpapillary portion, but nothing at all resembling epithelioma of the ordinary type.

In the smaller nodule the fully developed cancerous tissue structure was confined to a limited portion, but there were large alveoli, isolated or in twos and threes, very conspicuous in some

Digitized by Google

parts, deeply embedded in the tissue, and showing well the radiate arrangement of the outer epithelial cells. These, from their position, suggested an origin of hair-follicles and sebaceous glands as sweat-coils, more or less changed, could often be seen in their immediate neighbourhood. In the larger nodule the similar large foci of cells were more mixed up with the smaller cell-masses.

Cancerous disease of the scrotum is well known under conditions of chronic irritation from various occupations, such as that of chimney-sweeps, in the old days when they ascended chimneys, and in more modern times Volckmann has drawn attention to a similar occurrence in workers in tar or paraffin which, combined with want of cleanliness, lead to blocking up of the gland-ducts, and consequent inflammation. Under these circumstances, however, the primary inflammation is of a dry kind, leading to thickening and scaliness and fissuring, and the induced scratching and frequent tearing off of the scales and crusts play a not inconsiderable part in the production of the ultimate cancerous development, which always takes the form of epithelioma. An excellent summary of the inflammatory conditions under which this form of cancer is induced is contained in a paper by Schuchardt,[1] for reference to which I am indebted to Sir James Paget.

The case before us, however, differs from this class by the absence of anything in the man's occupation or history pointing to a chronic irritation, and also in the form of inflammation being a moist one, and clinically resembling the disease of the nipple, generally known as Paget's disease. The difference in the normal structure of the two parts may go far to explain the differences in the anatomy of the nipple cancer and the one before us. It is not easy to define the exact variety of cancer to which the case belongs.

It is certainly not an epithelioma in the ordinary sense, for it is clearly not derived from the epidermis, as there is total absence of the exuberant downgrowth of the epidermis, and the general structure differs notably from that form. The fibrous stroma is too abundant in some parts for encephaloid and too scanty in others for schirrhus. The general resemblance to rodent ulcer is striking, and there are strong grounds, moreover, for believing that the malignant change starts from the sweat- and sebaceous-glands

[1] 'Clinical Lectures,' edited by Volckmann, No. 257.

Digitized by Google

and hair-follicles, that it is in short an appendicular cutaneous cancer; and this again would bring it in relation to rodent ulcer. The clinical characters do not, however, correspond with this, inasmuch as the presence of nodules is not according to our usual conception of rodent ulcer, though it generally commences as a soft tubercle. Possibly also some members of the Society may know of cases of rodent ulcer in which there was a nodular development in some other period of its course. Even if its relation to rodent ulcer be admitted this would not destroy its analogy to the nipple disease, in which the cancerous development admittedly starts from the ducts of the gland. *November 6th*, 1888.

---

20. *Large fatty tumour in the scrotum surrounding the testis, but not adherent to it.*

By JONATHAN HUTCHINSON, F.R.S.

THE subject of this case was a gentleman of middle age from the country, who came up to have his testicle removed. The tumour had been growing in connection with the testicle, as both he and his surgeon believed, for many years. My first thought on seeing and handling his scrotum was that it was a hydrocele, for it was shaped exactly like one, and I thought it fluctuated. A little further examination, however, assisted by the patient himself, showed me that the testis could be isolated behind the swelling and pushed quite above it. I also became convinced that it was a soft solid, and that the apparent fluctuation was deceptive. The tumour did not pass up into the groin and the cord was not at all thickened. I advised the removal of the tumour, and assured the patient that I did not think it would be necessary to take the testis. The tumour was somewhat larger than the fist of an adult, and was quite loose in the scrotum. Excepting when carefully manipulated it quite concealed the testis. The operation was of the simplest character, for on cutting through the skin of the scrotum and some thin layers of fascia I came upon a lobulated and well-encapsuled mass of fat, which was easily shelled out by the finger. One lobule,

Digitized by Google

about as thick as a thumb and also about its length, passed upwards in front of the cord, but it had no attachments, and on following it up with the finger it came away just as easily as the rest. The tumour after removal presented all the characters of a common fatty growth, and was of very soft texture. The case is therefore an undoubted instance of a fatty tumour occupying the scrotum. The question remains, however, as to where it had originated, and especially as to whether it was within or external to the coverings of the cord. These points, I am sorry to say, I must leave in some doubt. There was no history of its having ever occupied the groin or having been mistaken for a hernia. The patient had always considered that it was connected with his testicle. In this, however, he may easily have been mistaken, for nearly twenty years had elapsed since it began to grow. The fact that it had kept in close apposition with the testicle perhaps favours the view that it was under the coverings, cremaster, &c. In the performance of the operation I did not recognise any special structures, but as they must necessarily have been very much thinned out by distension this evidence is again not conclusive. The probabilities from analogy and from the evidence of other cases are strongly in favour of its having originated near the ring and under the cremaster, &c., and having subsequently travelled downwards. In a paper by my eldest son on "Lipomata in Hernial Regions," published in our 'Transactions' for 1886, he arrives at the conclusion that all fatty tumours found in the scrotum are really developed from the fat external to the peritoneum, and have travelled downwards. Almost the only case in his series, however, which closely resembles the present one, in that the tumour was low down in the scrotum, and simulated hydrocele rather than hernia, was one which was recorded by Mr. Gascoyne in the seventeenth volume of our 'Transactions.' In this instance the tumour weighed 5 lbs. 6 oz., and had developed from the size of a walnut in the course of seven years. It was believed to have originated in the lowest part of the spermatic cord, and the testicle, perfectly healthy, was in front of it. In this instance, as in mine, there was no history of its having travelled from above nor any suggestion that it had ever been taken for hernia.

February 19*th*, 1889.

Digitized by Google

21. *Sarcoma of the testicle, following on removal of the other for hypertrophy of a doubtful nature, which the microscope had declared not sarcomatous.*

By JONATHAN HUTCHINSON, F.R.S.

AN elderly gentleman, a member of our own profession, called on me with the express request that I would remove one of his testicles. He had already consulted Sir James Paget, and had been told that the conditions were very suspicious as regards malignant disease in an early stage. He was in good health, but was very anxious and unhappy from his fear of cancer. He was fond of hunting and thought that he might have bruised the testis on the saddle; there was no history, however, of any definite injury. The testicle was enlarged to about the size of a hen's egg and felt heavy and firm. It was the body of the gland which was involved, and the enlargement had been noticed for about six months and was steadily increasing. It was impossible to feel any certainty in the diagnosis, but the conditions were sufficiently suspicious to make me readily accede to the patient's wish. The testis was accordingly removed. Mr. Harrison Cripps, Mr. R. W. Parker, and others were present at the operation. On examining the testis by section after its removal, everyone thought that we had made a mistake in diagnosis, for it showed no appearances of new growth whatever. It was simply hardened and apparently hypertrophied. All parts in the cut surface looked much alike. The lobules and tubes were seen with remarkable distinctness, and on a larger scale than usual. We all of us took portions away for microscopical examination, and all my friends assured me afterwards that they could find nothing but the evidences of chronic inflammatory induration. Such being the case I told my patient that I did not think he need fear in the least any recurrence, and regarded the case as one in which an operation had been done without adequate cause. I am very sorry, as the sequel proved, that I did not think it worth while to preserve the specimen or to make a drawing of it, nor did I keep any microscopic sections, and I am indebted to the kindness of Mr. Harrison Cripps for the one which I produced at the Society. I may repeat, however, that

Digitized by Google

the testimony of all who examined it confirmed our naked-eye impressions that it was an example of inflammatory hypertrophy and not of new growth. About eighteen months, however, after the operation, Dr. H— returned to me with the statement that his remaining testis was beginning to enlarge just as the other had done. He had in the interval enjoyed good health, and his age was now nearly seventy. I found, as he said, the second testis presenting precisely the same conditions as the first had done. It was somewhat enlarged in all directions and felt dense and heavy. Remembering the negative results of examination on a former occasion, I was unwilling to do another operation and advised delay. When, however, about two months later he returned to me with very considerable increase, I took alarm and acceded to his wish. The second operation was performed on June 14th, 1883, the testis being at this time as large as a small fist and somewhat nodulated on its exterior. I possess portraits of the testis after removal, exhibiting its exterior and its appearances on section. The latter exhibits a greyish-brown surface obscurely divided into lobes. It was moderately firm in structure, and did not yield much juice. It proved to be a good example of round-celled sarcoma. Dr. H— did well after the operation, and again recovered excellent health. Two years later, however, he slipped n descending some steps, and soon after this a growth appeared in the head of his tibia; probably it had been there before. After this, spontaneous fracture of the tibia occurred, and still later growths developed in the subcutaneous cellular tissue of several parts. He died early in January, 1886, two years and a half after the second operation, and about six after the first.

Several different opinions may be held respecting the facts which I have narrated. It may, in the first place, be held probable that the testis first affected was really not the seat of any morbid growth, but of inflammatory hypertrophy only, and that it had no direct connection with what subsequently happened. This seems to me improbable, for such enlargements are rare as the result of inflammation only, and the cause of the malady in the second testis was exactly like that of the first. Next, it may be supposed that a condition not to be distinguished from inflammatory hypertrophy was really introductory, and constituted indeed the first stage of sarcomatous growth. This is the view which I am myself most inclined to take, for it is in harmony with much

Digitized by Google

that we observe as regards the early development of external cancer. In epithelial cancer, as we see it on the lip, tongue, &c., there are very frequently, indeed I think usually, prolonged precancerous periods, during which the local changes are those of chronic induration only. What we here see demonstrated beyond possibility of doubt in parts which are visible may very probably have its parallel in the viscera. Many forms of internal cancer may, it is not unlikely, have their introductory stage of chronic inflammation. In the case of the lymphatic glands in particular, everyone will allow that it is almost impossible to decide where inflammatory hypertrophy ends, and sarcomatous or lympho-sarcomatous processes begin. There is, however, yet another suggestion as explanatory of the facts of my case, and one probably which the majority of authorities would prefer to accept. It may have been that the disease was from its very beginning an infiltrating sarcoma and had nothing to do with inflammatory processes, and that it illustrates only the difficulty of distinguishing by the microscope as well as the unaided eye between the two. Very fortunately sections from the testis first removed had been preserved by Mr. Harrison Cripps, and concerning these I believe that the opinions of several who have recently seen them are in favour of their being examples of sarcoma. Others, however, declare that they show nothing that would justify any definite opinion, and I must claim to be entitled to allege that no one suggested they indicated sarcoma before the sequel of the case was known. I will not enter into any detail as regards the microscopic appearances, for I did not myself in the first instance study them carefully, having taken for granted from the naked-eye appearances that there was no new growth, and having been told also by my histological friends that such was their conclusion. It may, I suppose, be freely granted that the microscopic diagnosis between infiltrating round-celled sarcoma and chronic inflammatory hypertrophy is not always easy.

For clinical purposes the recognition of the early stage of malignant disease of the testicle is at the same time very important, and at the same time very difficult. If the testis continues to grow in spite of treatment, then the disease declares its nature. But should the patient come under care in an early period of the enlargement, it may for a time be almost impossible to give any definite opinion. I have had recently under care a case in which

Digitized by Google

the lesson taught in the narrative above given was repeatedly recalled to my mind. The patient was an elderly gentleman, who was brought to me in the belief that the disease was of the nature of new growth. The testis was hard and heavy, just as in Dr. H—'s case. There was the history of cancer in his family, and I had indeed myself amputated the lower limb of one of his sons on account of myeloid sarcoma. There was the history, however, of prostatic irritation having preceded the swelling of the testis, and this induced me to recommend that the operation which had been proposed should be deferred. After a few weeks of absolute rest in bed with iodide of potassium and the local use of cold the induration of the testis disappeared completely.

February 19*th*, 1889.

Report of the Morbid Growths Committee on Mr. Hutchinson's case of disease of the testicle.—We have examined microscopic sections of the testicle removed by Mr. Hutchinson on April 24th, 1880. One of the sections was prepared by Mr. Harrison Cripps, others by Mr. R. W. Parker.

Of the other testicle subsequently removed, neither microscopic sections nor the specimen are extant. We have no hesitation in regarding the disease as lympho-sarcoma. The structure of the new tissue is quite uniform, and is of the most typical lymphoid kind. The reticulum between the individual cells of the growth is beautifully seen in Mr. Cripps's preparation. There is nowhere the least indication of any transformation of the new substance into fibrous tissue, the cells of which substance are uniform in size and shape, and exhibit no enlargement, elongation, or other fibroblastic changes.

R. W. Parker.

April 2*nd*, 1889. Samuel G. Shattock.

Digitized by Google

22. *Extra-uterine fœtation; rupture of cyst; abdominal section; peritonitis; death.* (*Card specimen.*)

By FREDERICK WALKER MOTT, M.D.

M. H—, aged 25, admitted into Charing Cross Hospital for extra-uterine gestation under the care of Mr. Bellamy. She was seen by Dr. Black on April 22nd; he found a tense elastic tumour in the right side of the lower part of the abdomen reaching to within three fingers' breadths of the umbilicus, the uterus being pushed over to the left side.

April 24th.—On the day of admission there was a central swelling of the abdomen situated entirely below the umbilicus. Patient had not menstruated for three months. She had had one child which was born four and a half years ago. On either side of the cervix a firm mass could be felt on vaginal examination. Milk could be squeezed from the breasts.

At the operation on April 25th, on opening the peritoneal cavity a large quantity of clot appeared which was not quite recent, but had not become organised. On scooping away some of this clot a fœtus, third to fourth month, appeared and was readily removed, the umbilical cord tearing through. A mass was then removed consisting of blood-clot and placenta.

Autopsy.—On removal of the dressing and cutting the sutures the small intestine was found adherent to the front of the wound, and the coils adherent to one another by fibrinous lymph and blood-clot. On separating the coil of intestine a large cyst was found bounded in front by the abdominal wall the bladder and pubis, to the right by the cæcum and adjacent structures, to the left by adherent coils of intestine; the wall of the cyst was formed of coagulated blood. The cavity, which extended for the most part to the right of the middle line, was as large as a child's head. It contained a quantity of lymph and blood-clot. The intestine showed recent and old peritonitis, but not enough, it was considered, to account for death. The uterus and appendages, together with bladder and rectum, were removed. The bladder was cut away and the uterus opened with scissors from the front; it contained a decidua one third of an inch thick. Subsequently the Fallopian tubes were dissected out on either side and a blunt probe passed in.

Digitized by Google

Further dissection showed the right Fallopian tube to be perfect throughout, as the left also was up to its termination; here it was firmly matted in a dense, hard, old blood-clot, which was connected with the cavity that had contained the fœtus. The direction of the left Fallopian tube was backward as well as outward, and it seems that the ovum which had undergone the abnormal gestation must have either escaped from this Fallopian tube and become attached close to the fimbriated extremity, or that it had not completely become disengaged from the end of the tube. *May 21st*, 1889.

---

23. *Blood concretions in the ovaries.*

By H. W. G. Mackenzie, M.D.

A woman, aged 41, who had suffered for two years from menorrhagia, was admitted to St. Thomas's Hospital under the care of Dr. Gervis. The catamenia had during this period lasted from ten to fourteen days, and had been very profuse. She was very weak, anæmic, and emaciated. Examination showed the existence of a large fibroid tumour of the uterus. She died in a few weeks from cardiac failure.

At the autopsy the various organs other than the pelvic were found healthy, with the exception of the heart, liver, and spleen. The curtains of the mitral valve were thickened, the valve was incompetent, and the left ventricle was hypertrophied. The liver was fatty, and both it and the spleen were larger and heavier than normal. There were no hæmorrhages in any of the organs.

The uterus was uniformly much enlarged, filling up the whole of the pelvis. The right ovary lay outside the pelvis on the right iliac fossa, while the left was adherent to the back of the uterus. The cavity of the uterus was filled by a large globular mass about four inches in diameter, attached on the left by a broad base to the uterine wall. The latter was uniformly increased in thickness to about three quarters of an inch.

On section the tumour had the characteristic appearance of a fibro-myoma, being firm and tough, greyish white, and glistening, differing little from the uterine wall.

Digitized by Google

On the surface of the tumour was a very vascular nodule, probably the source of the uterine hæmorrhage.

The ovaries were enlarged, and on section were found to contain a number of black, hard, flat masses. The cavities in which these concretions were contained were smooth walled, and had been adapted in shape and size to the concretions contained in them. Two or three concretions were contained in one cavity. The concretions were of various sizes, from a coriander seed to a small bean; they were of very irregular shapes, as if they had been moulded in irregular cavities; they had smooth surfaces, and were flattened where they had been in contact with one another; they were very firm and hard, but light, and they could be cut with a knife like very hard wax. In the recent state their colour was nearly black, but in the course of a few months they have become much lighter, being, when exhibited, lightish brown.

A thin section under the microscope has the same yellow colour as blood. There is no trace of structure, but there are indications that the whole mass is made up of minute spheroidal bodies.

The physical character of the concretions pointed to their being of an organic character; their situation and colour made it probable that they were derived from blood-clots. Dr. S. M. Copeman has very kindly examined some of the concretions, with a view of determining their constitution. He found that they were exceedingly insoluble, alike in acid and alkaline solutions, and in ether and chloroform. Prolonged digestion with artificial gastric juice in an incubator at the body temperature, however, dissolved them. A coloured solution was thus obtained, from which Dr. Copeman obtained the spectrum of acid hæmatin; the solution also gave the guaiacum reaction for blood.

The concretions, therefore, most probably consist of coagulated proteids derived from blood-clot, akin to lardacein, and of the same family as the colloid concretions of the prostate and the amyloid bodies sometimes found in old hæmorrhages.

The specimen is, as far as I have been able to find out, unique. It is most likely that the cavities in which the concretions were situated were Graafian follicles, and that the blood effused into these follicles, instead of becoming absorbed, had undergone a rare colloid change. A large tumour, uniformly distending the uterus, and accompanied with hypertrophy of the organ, would doubtless be a cause of chronic congestion of the ovaries. For the occurrence

Digitized by Google

of this rare change of a blood-clot into a solid concretion I can offer no explanation.

October 16*th*, 1888.

---

24. *Large ovarian tumours in a seven months' child.*

By Alban Doran.

[With Plate XVII.]

These tumours were removed, after death, from a seven months' child, which survived its birth but a few minutes. The mother was a multipara under the care of Mr. Charles Hooper, of Aylesbury, in March, 1888. The abdomen was distended, the subcutaneous veins were prominent. The integuments above the level of the umbilicus were discoloured through ecchymosis. On opening the peritoneal cavity much ascitic fluid escaped, and two large ovarian tumours were discovered; the larger was on the left side. The liver appears to have been large even for a fœtus, the kidneys and spleen were healthy. There was a hernial sac, containing nothing but fluid, in each inguinal canal.

The left tumour was presented by Mr. Knowsley Thornton to the Museum of the College of Surgeons (Path. Ser., No. 4498 D). The donor kindly committed it to my charge whilst it was still fresh, and I at once directed Mr. Lewin to prepare the coloured sketch which I exhibit this evening (Pl. XVII, fig. 1). The action of spirit on the delicate embryonic tissues of the specimen has altered its original appearance and destroyed its natural colour.

This tumour when fresh strongly resembled a small cystic kidney. The Fallopian tube, very thin but nearly an inch long, the intervening portion of the broad ligament, and a small portion of the uterus lay on its upper surface, and are represented in the coloured sketch. A great part of the tube was inadvertently cut away; the fimbriated extremity and the piece of uterus remain; fortunately the sketch was taken before this mutilation. The tumour measured three and a half inches horizontally by two and a half vertically. When fresh it was of a uniform bright pink

Digitized by Google

Digitized by Google

DESCRIPTION OF PLATE XVII.

To illustrate Mr. Doran's case of Ovarian Tumours in an infant. (Page 200.)

FIG. 1.—The left tumour as it appeared when fresh. Natural size. From a coloured sketch by Mr. Lewin. The Fallopian tube lies above, the cavity of the tumour is exposed by a large aperture, along the edge of which the peculiar reticulated or cavernous structure of its wall is displayed.

FIG. 2.—Portion of the left tumour, as seen under a low power (½ inch objective), showing large spaces and broad trabeculæ.

l. c. Transparent material lining a space or cavity.

h. p. Are represented in Fig. 3 under a higher power. The trabeculæ appear to be made up of round-cells.

FIG. 3.—The area, *h. p.*, Fig. 2, as seen under a high power (⅛ inch objective).

r. c. Round-cells closely packed.

f f f. Graafian follicles.

i. c. Incipient cavity, the round-cells becoming transparent and surrounded by an oval chain of flatter cells (see text).

c. Cavity, as they approach its border the round-cells become gradually fainter. No epithelial lining can be detected.

Digitized by Google

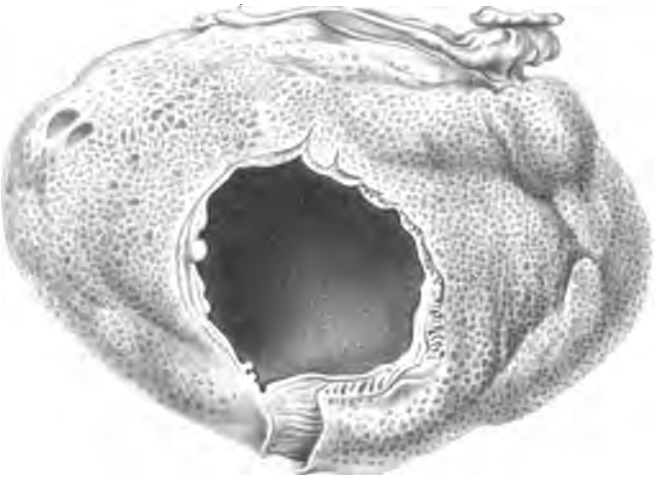

Fig 1.

Fig 2

Fig 3

Digitized by Google

Digitized by Google

colour, faintly tinged with lilac. Its surface showed numerous minute elevations, as though produced by small cysts, and was free from any adhesion or evidence of peritonitis. On laying the tumour open, it was found to consist of a thin shell of solid material enclosing a large central cavity. This cavity contained clear fluid which had been emptied out before the specimen came into my hands; its wall was quite smooth. Excepting at one point on the lower part of the anterior surface, the wall or solid part of the tumour was nowhere over an eighth of an inch in thickness. It has become yet thinner through draining away of its fluid contents and the action of spirit. The cut surface displayed a reticulated rather than a cystic structure; at the point mentioned above where the tumour substance was dilated, I found an irregular cavity, nearly one inch long, with imperfect loculi. Thus, thin though the wall was, it greatly exceeded the wall of an ordinary multilocular cyst in thickness, and was perfectly different in structure.

The tumour of the right ovary closely resembled the left in colour, when fresh, but was much smaller. The Fallopian tube and broad ligament showed very plainly on its surface. Horizontally, it measured two and a half inches, vertically one and a half. It has shrunk and become much puckered through the action of spirit.

Portions of the wall of the left tumour were carefully removed when the specimen was fresh and prepared for the microscope. When viewed by the naked eye, each section appeared as a wide-meshed network, with trabeculæ very fine in parts but elsewhere stout. Only in one section was there any considerable tract of solid matter. The spaces were partially filled with semi-transparent material. Under a half-inch objective the trabeculæ appeared to consist of a multitude of small round-cells in a homogeneous matrix. Evidences of the formation of cysts, or rather cavities, were abundant, especially in trabeculæ of moderate width (Pl. XVII, fig. 2). In the larger trabeculæ and small tracts of solid matter, the stroma was more uniformly made up of the round-cells, with fewer cavities. The thinnest trabeculæ were much altered by the action of reagents, hence their structure was not easily defined. In the parts of the section where these thin trabeculæ prevailed, the tissue appeared to be cavernous,[1] or reticulated rather than cystic; whether this

[1] I use the word "cavernous" to explain the arrangement of the imperfect

Digitized by Google

represented a primary or secondary condition will be presently discussed. The semi-transparent material, which formed networks within the cavities, proved to be entirely artificial. It represented the action of reagents on the half-fluid contents of the cavities. In fig. 2, the transparent deposit may be seen at the edge of some of the wide cavities (*l. c.*) simulating, at some points, the deep layers of epithelium seen in glandular growths from multilocular ovarian cysts; but I failed to detect epithelium of any kind.

Under an eighth-inch objective the structure of the trabeculæ and the borders of the cavities showed some interesting appearances, well displayed in Mr. Lewin's sketch (fig. 3). The cells were far less uniform in character than they appeared to be when viewed under a lower power. In the solid areas the uniformity was no doubt greater than elsewhere. Multitudes of small round-cells lay close to each other in parts; in other places they were more scattered. A matrix could be distinguished in the parts where the cells were sparsely distributed. This matrix showed evidences of fibrillation and indications of plain muscle-cells or at least of elongated connective-tissue cells of considerable size. A few fine-walled blood-vessels could also be distinguished.

The round-cells which prevailed in the solid tracts resembled cells which abound in the stroma of the parenchyma, or interfollicular tissue of the human ovary early in fœtal life. Thus I found multitudes of round-cells in the ovary of a four months' fœtus, in my collection; the cells were rather larger than those seen in this tumour. In the ovary of a seven months' fœtus, also in my private collection, the round-cells, instead of abounding, were found to be scanty and mostly replaced by a delicate fibrillated intertrabecular tissue. In the ovary of a child aged three, the fibres were yet more distinct, whilst the round-cells were almost absent, and in no parts of the section formed anything like a group.

Thus the more solid part of the tumour may be said to consist of embryonic tissue, resembling the normal tissue of the ovary in early fœtal life. The tissue of the tumour was, in fact, younger than that which makes up a healthy ovary in a seven months' fœtus. In an adult a tumour composed of similar tissue would be described

septa which traversed the sections in all directions. I do not mean to imply that the tissue of the tumour was "cavernous" in the sense understood by the term "cavernous tissue."

Digitized by Google

as a round-celled sarcoma, essentially malignant. The ascites, the dilated abdominal veins, and the discolouration of the integuments (if not a mere *post-mortem* change) indicated malignancy in the present case. Yet all these three symptoms are exceptionally seen in cases of large but pathologically innocent multilocular ovarian tumours in the adult. In the fœtus this exceptional condition may be yet less rare, for the delicate peritoneum may more readily pour out fluid, and the venous circulation in the abdomen may more easily be obstructed in the embryo than in the adult. Hence the above clinical conditions were no absolute proof of malignancy, although they indicated it. Above all, embryonic tissue in the embryo must bear a different histological and pathological signification to embryonic tissue in the adult, even in the case of a tumour. It is less abnormal, therefore less characteristic of malignancy in the fœtus. Hence the tumour exhibited to-night must not be lightly described as a round-celled sarcoma.

I may here state that during the present year I have examined a remarkable case of undoubted congenital sarcoma in an infant, exhibited by Dr. John Phillips before the Obstetrical Society. There were large growths in the frontal and parotid regions and deposits in some of the viscera. On microscopic examination the new growth was found to bear all the appearances of a round-celled sarcoma. The sections bore a considerable resemblance to parts of the sections exhibited to-night, both in the form of the round-cells and in their arrangement and relations. Nevertheless this fact does not justify me in describing the tumour now under consideration as an ordinary round-celled sarcoma. The ovary at birth is normally far more embryonic in character than are the tissues which were invaded with new growth in the infant exhibited by Dr. Phillips.[1] Hence a tumour of similar appearance in each case may bear a different pathological interpretation.

The narrowest trabeculæ showed uniform collections of round-cells in a matrix for the most part homogeneous. The broader trabeculæ presented certain appearances which were highly instructive, both as regards the stroma and the manner in which the cavities were developed. Fig. 3 shows part of a broad trabecula and the border of a large cavity, being the area marked *h. p.* in fig. 2, as seen under an eighth-inch objective. The round-cells, which

[1] A pathological report of Dr. Phillips's case, with drawings, will be found in the 'Trans. Obst. Soc.,' vol. xxx, 1889, p. 334.

Digitized by Google

abounded in all parts of the tumour, are marked *r. c.*; *c.* points to the border of a large cavity, showing how the round-cells fade off into the free space with no signs of an epithelial lining. At *i. c.* a cavity is, I suspect, about to be formed. A collection of round-cells appear, surrounded by a zone of flatter cells. The round-cells are less distinct than at *r. c.*, and in other parts of the section I found similar encapsuled groups (to use a convenient term) actually breaking down in the centre. Let it be granted that cystic cavities continue to be formed in this manner and we can understand how their partition-walls may break down in an irregular manner, and thus form the reticulated tissue which is the chief feature in this tumour. On the other hand, what is the origin of *i. c.*? The structures *f. f. f.* look remarkably like Graafian follicles, as seen in the fœtal ovary. Comparing their borders with the zone of flat cells which encapsule *i. c.*, the observer may be led to believe that the zone represents the epithelial investment of an enlarged follicle. If this be true the enclosed round-cells, if not all the round-cells which compose the tumour, would be of intrafollicular origin.

I doubt, however, whether any competent observer would be satisfied with the latter part of the above interpretation of the appearances of the sections, which, taking away the middle factor, *i. c.*, would lead to the conclusion that the tumour was developed from the Graafian follicles. I have already noted that the tracts of solid tissue already described, tracts extensive enough to cover three or more fields as wide as that included in fig. 2, histologically resembled the interfollicular tissue in the normal ovary in early fœtal life. In the midst of these tracts were collections of cells which were swelling, becoming transparent, and breaking down. These appearances were also seen at the borders of the large spaces (*l. c.*, fig. 2, and *c.*, fig. 3). Hence it is more probable that the tumour was the result of proliferation of the cells of the stroma of the parenchyma (oöphoron) and subsequent cyst-formation by breaking down of cells, than that it was of intrafollicular origin. The flat cells around *i. c.* might be of extrafollicular origin or, if follicular, the round-cells which they surrounded might have invaded the follicle from without.

There can be little doubt that *f.*, fig. 2, represents a Graafian follicle. Hence the stroma of the parenchyma of the ovary, the oöphoron, was the seat of the tumour, whether the tumour arose

Digitized by Google

from within or without the follicles. Before turning to the comparison of this tumour to a multilocular cyst in the adult I may note that it could hardly have arisen from relics of the Wolffian tubules. The tumour lay precisely in the anatomical site of the ovary, the broad ligament was normal, and the presence of follicles indicated parenchyma tissue (oöphoron). Into that tissue Wolffian tubules and epithelium normally stray to a limited degree, but follicles rarely, if ever, extend into the hilum tissue (paroöphoron). The stroma of the tumour bore none of the characters of hilum tissue. Admitting, then, that we have to do with parenchyma, the theory that the tumour arose from stray Wolffian elements is hardly tenable. No such elements could be detected, and whereas they tend, under morbid influences, to form papillomatous cysts, bearing well-formed columnar (and sometimes ciliated) epithelium,[1] no papillomatous growths and no distinct epithelium could be detected in this tumour.

Hence there can be no doubt that the specimen is a tumour of the ovary proper, the oöphoron. This suggests an important question. Is it a multilocular ovarian tumour, identical pathologically with that kind of growth so common in adult life?

In the first place, the nature of cases of ovarian tumours in the fœtus already recorded must be taken into account. A large proportion of ovarian tumours in children are dermoid, but I know of no specimen of a fœtal dermoid ovary. The cystic fœtal ovaries preserved in London museums are all examples of dropsical follicles. The fœtal ovarian tumours described by Mr. Sutton and myself[2] were papillomatous and therefore probably of Wolffian origin. In my case, the ovary was hardly enlarged, though the fœtus was of the same age as in the case described to-night. Winckel, in his well-known text-book on diseases of women, figures a congenital cyst of the left ovary in a new-born infant, said to be in a Munich museum. The tumour is represented as cystic in its upper part and solid below, very unlike the present specimen in appearance, and much smaller. The same text-book contains two drawings of microscopic sections of a multilocular solid ovarian cyst in a new-

[1] See "Proliferating Cysts in the Ovary of a Seven Months' Fœtus," 'Trans. Path. Soc.,' vol. xxxii, 1881, p. 147. Mr. J. B. Sutton has since described a similar case where also "the remains of the mesonephros (Wolffian body) seemed to have completely usurped the true ovarian tissue" ('An Introduction to Pathology,' p. 205).

[2] Ibid.

Digitized by Google

born child. The sections resemble those prepared from similar tumours in the adult ovary. Microscopic secondary cysts, or at least spaces, are represented; they are lined with very distinct well-formed epithelium. The sub-epithelial connective tissue includes large collections of round-cells as in the present specimen. No cavities evidently formed by breaking down of those cells can be detected. Hence Winckel's specimen differs from mine in two respects, the lining of the cavities and the apparent manner of their formation. Nevertheless, I can hardly draw satisfactory conclusions from comparison of a tumour which I have examined with a series of drawings in a foreign text-book.

As I cannot find a precise histological resemblance between my specimen and a multilocular ovarian cyst in an adult, I refrain from tracing to any appearances in this specimen the possible origin of the common ovarian tumour. Aberrations in the development of the follicles (*f.*, fig. 3) may have been the exciting cause of the new growth, but I have already shown that the tumour is mostly, at least, made up of hyperplastic extra-follicular cells belonging to the parenchyma, and of cysts the result of breaking down of those cells. The large central cyst no doubt developed more or less in the same manner as the minute cysts in the wall of the tumour. Lastly, I could not detect any of the different appearances which Mr. Eve, Dr. Vincent Harris, and myself have noted in relatively small ovaries, the fellows of large multilocular cystic tumours removed by operation.

In conclusion, this tumour might be held by some observers to represent certain semi-solid ovarian growths seen in the adult; as, for example, the specimen described in my 'Clinical and Pathological Observations on Tumours of the Ovary,' p. 101, figs. 23, 24, or a case which I once observed in a woman about twenty-five years of age, simulating in some respects round-celled sarcoma. The pathologist would, in the latter instance, recognise a growth made up of round-cells, completely replacing one ovary, or even both ovaries, as in this fœtus; yet he would be bold indeed if, upon some theory of "latency," he were to assert the identity of a pair of tumours which took twenty-five years to develop with a pair which reached a large size before the patient was born, and prematurely born, into the bargain. Possible it may be that the histological development of the ovary may cease to advance at the fourth month, the lowly organised ovarian tissue sud-

Digitized by Google

denly undergoing hyperplasia at the age of twenty-five. The fact remains, however, that we do not find, in the bodies of children, histologically ill-developed ovaries lying latent, that is to say, not forming tumours. Again, the evidence of this evening's case tends to prove that histological arrest of development rapidly turns a small ovary into a large tumour.

As the above somewhat minute analysis of the left tumour may be confusing to the reader, I append the following brief recapitulation of the subject:

1. The tumour consisted of a cyst with a solid wall, which was thin, but thicker than the wall of a common multilocular cyst, and totally different in character.

2. The wall was made up of a highly reticulated tissue, consisting of trabeculæ greatly varying in thickness and spaces which were not true cystic cavities.

3. The trabeculæ were composed of collections of round-cells in a transparent matrix, which in some places showed evidences of fibrillation.

4. This arrangement of cells and matrix recalled the normal structure of the tissue of the parenchyma of the ovary in an earlier stage than that which the patient had in this case attained.

5. Hence the tumour appeared to represent uniform persistence and hyperplasia of the entire embryonic tissue of the parenchyma of the ovary (oöphoron), rather than round-celled sarcoma, which in adults, or even when congenital (Dr. Phillips's case), grows in circumscribed masses where embryonic tissue similar in character does not exist.

6. The evidence that any part of the growth originated within the Graafian follicles was weak; the evidence that it arose entirely from the interfollicular tissue was strong (see 4, 5).

7. The presence of Graafian follicles in some of the trabeculæ proved that the growth was in the oöphoron, and not in the hilum tissue (paroöphoron). Moreover, hilum cysts in the fœtus differ entirely in character from this specimen.

8. The spaces between the trabeculæ and also the great central cyst appeared to be formed by breaking down of the solid matter; these spaces bore no epithelial lining.

9. This tumour bore little or no resemblance to the common multilocular ovarian cyst, and therefore could not throw any satisfactory

Digitized by Google

light on the origin of that well-known form of tumour in which true cystic cavities and epithelial structures abound.

10. This tumour could hardly explain the significance of certain semi-malignant tumours of the ovary in the adult, on the theory that an ovary arrested in its histological development could remain latent for years, suddenly becoming a tumour. Such "latent" ill-developed ovaries are not found in children's bodies, and the evidence of the present case is entirely against latency, as the histological arrest of development turned each ovary into a tumour before the birth of the patient. *October 16th*, 1888.

---

25. *Columnar-celled carcinoma of the ovary.* (*Card specimen.*)

By SAMUEL G. SHATTOCK.

THE specimen was obtained from a case under the care of Mr. Pitts, to whom I am indebted for its exhibition. The diagnosis was uncertain, both as regards the nature of the growth and its seat, whether ovary or uterus.

On an exploratory operation being undertaken, there were found, when the peritoneum was opened, that there were the evidences of recent peritonitis, due, as it appeared, to the rupture of a cyst within the growth. The patient's condition became so critical during the procedure that further measures had to be abandoned. Death occurred about two days afterwards. The tumour lay over and above the uterus, but after death was readily separated from it.

The ovary is converted into a great lobulated oval tumour, eleven inches by five in its chief diameters, though noticed only about six months. There are few septa in the section, and these, which mark the superficial lobulation, nowhere extend into the central part of the mass.

The divided surface yields, on scraping, an abundance of "juice," and then displays a finely reticulated or alveolar structure. Here and there occur somewhat larger spaces filled with mucus. But the only cavities of any dimensions are those resulting from degeneration; these have highly irregular walls devoid of limitary

Digitized by Google

membrane; one of them reaches the surface, and ruptured during life into the peritoneal cavity.

Histology.—The tumour consists, without variation, of tortuous, loculated channels, of various forms according to the direction of their section, lined with remarkably tall, slender, and very closely pressed columnar epithelium, disposed in a single layer, and everywhere bounding a lumen. The stroma between the spaces is of a delicate richly-celled connective tissue, and is in about the same proportion as the tubular element. The contents of the spaces are sharply demarcated from the cells, and consist in many of an unstained, glassy, minutely-fissured substance, presenting very clear traces of concentric lamination. All gradations may be traced between this and what is in other of the spaces extravasated blood in which the forms of the individual red discs are quite obvious. The concentrically fissured material corresponds exactly in appearance with the blood of a thrombus previously to its "organisation."

This blood is mingled in other of the spaces with a finely stained vacuolated structureless substance, identical with that which occupies the spaces in the ordinary ovarian adenoma, and doubtless of the same nature, viz. mucus. In its histology, the growth follows the general rule which obtains in other glandular organs; the epithelium of the carcinoma is of the same kind as that of the adenoma arising in the same part, and in both it is a repetition or extension of that proper to the normal structure. As to the origin of the columnar epithelium in carcinoma of the ovary, the problem is the same exactly as that presented by ovarian adenoma. It is almost superfluous to repeat the common knowledge that the epithelium investing the ovary is columnar celled, and that from this by involution into the stroma are produced the different structures constituting the ova and Graafian follicles; and that the explanation of such a columnar-celled investment is to be found, according to the Hertwigs, in the origin of the pleuro-peritoneal cavity from the primitive intestine.

It may be pointed out, parenthetically, with regard to the primary origin of columnar-celled carcinoma in the peritoneum or pleura, that although the general epithelium of the membranes is at birth no longer columnar,[1] it is still credible that by the persistence of

[1] Many instances of epithelial mutation will suggest themselves. The epithe-

Digitized by Google

islets of the primitive epithelium, or reversion to the original type, the lining of either membrane might furnish the basis of a columnar-celled carcinoma. The cases as yet reported, however, although suggestive, cannot be regarded, on close criticism, as adequate to establish such an occurrence. [The specimen is in the museum of St. Thomas's Hospital.] *April 2nd*, 1889.

---

26. *Specimen of tubercular disease of ovary.*

By WALTER EDMUNDS, M.D.

SPECIMEN shows an ovary greatly enlarged, measuring two inches by an inch and a half. The enlargement is uniform, and the surface of the ovary is smooth. Attached to the ovary is seen a portion of the corresponding Fallopian tube, much thickened.

Microscopically, sections of the ovary show the enlargement to be due to tubercular infiltration, for tubercles and giant-cells are to be found in abundance. Sections of the Fallopian tubes also show microscopic tubercles with giant-cells.

The history of the case was as follows:—At the age of fifteen the patient suffered from pelvic pain and purulent discharge from anus. She noticed at this time a small lump on the right side in the lower part of abdomen. She was not laid up with her ailment till her twenty-first year, when she was admitted into St. Thomas's Hospital. A tumour posterior to the uterus was detected. There were also strumous glands in the neck. Abdominal section was performed, the right ovary and Fallopian tube being removed. There were numerous and firm adhesions binding the parts together.

Patient died on the fourth day. At the *post-mortem* examination there was found signs of former generalised peritonitis, and a sinus leading from an abscess in Douglas's pouch to rectum. Strumous glands in neck. No other tubercular disease.

Owing to the advanced stage of the disease it is impossible

lium of the bronchial tubes is columnar ciliated, that of the air-cells is flat, though they have a common origin. The œsophagus is at one time, like the trachea, lined with columnar ciliated epithelium, subsequently with stratified, though its glands retain the columnar, &c.

Digitized by Google

to say for certain where it had originated, but it seems probable that it started in the ovary, as that is the organ which is most altered.

Mr. Shattock has shown me microscopic sections from another case of tubercular disease of ovary which also occurred at St. Thomas's Hospital last year.

A married woman, aged 34, who had never been pregnant, had, six months before admission, severe pain in lower abdomen, and soon after passed *per vaginam* a "mass" the size of a walnut.

On admission an abscess was found deep in the right inguinal region, and was opened. A purulent discharge occurred at the same time from the vagina. Three months later abdominal section was performed, and both ovaries, both Fallopian tubes, and the fundus of the uterus removed.

The uterus contained numerous fibro-myomata ranging in size from that of a goose's egg to that of a pea. One or two of these were of a pale yellow colour, but microscopic examination showed that the change was one of degeneration only, without any inflammatory condition or anything of the nature of tuberculosis.

Both Fallopian tubes were distended. The right ovary had undergone suppuration, by which it was hollowed out. Sections of the ovary show well-marked miliary tubercles. The left ovary was the seat of cystic disease.

The parts have not been preserved, but the microscopic sections leave no doubt as to the nature of the disease. The patient died four days after the operation.

The *post-mortem* examination showed that there was no tubercular or other disease elsewhere in the body.

The following is also a case of tubercular disease in the pelvis, but it is not possible to say in what structure it originated:

M. J. B—, aged 30, was admitted to St. Thomas's Home under Dr. Cullingworth's care. She has been married four years, but had had no children. Some months before admission she had suffered from a sense of weight and a dragging pain at the groins. Four months before admission the abdomen commenced to distend; there was evidence of a large cystic ovarian tumour. On abdominal section the right ovary was found to contain a large cyst, and it was removed, together with the Fallopian tube, which was diseased; the left ovary was also enlarged, two by one and a half by one and a quarter inches, and the corresponding Fallopian tube

Digitized by Google

was distended; these too were removed. The peritoneum, both parietal and visceral, was studded with translucent granules. The right Fallopian tube was distended with cheesy material.

Microscopic section of the tube shows well-marked tubercles. Patient made a tedious recovery.

Remarks.—It is almost certain that the tubercular disease originated in the ovary in the second of these cases, and it is possible that it did so in the other two.

In conclusion, I have to thank the physicians and surgeons under whose care these cases were for permission to publish them.

November 6th, 1888.

---

27. *Tubercle of the ovaries.*

By W. S. A. Griffith, M.D.

The ovary and Fallopian tubes which form the subject of this communication were removed by Dr. Galabin from a nullipara aged 19 years. She had suffered from procidentia uteri for four years for which the operation of perineorrhaphy was successfully performed. A year after this operation Dr. Galabin found a retro-uterine swelling, which he at first believed to be an abscess discharging into the rectum, and for a time it appeared to diminish in size, but afterwards increasing it was removed.

The ovary was the size of a small apple, smooth uniform surface, moderately dense on section, containing numerous small cysts filled with viscid fluid. There was no appearance of caseation. The Fallopian tubes were also enlarged.

The disease was thought to be malignant, and a small portion only was preserved for microscopical examination, and the remainder is lost.

Further history.—The patient recovered from the operation and when last heard of was in good health.

Microscopical examination. Ovary.—The section shows rather dense, well-developed connective tissue; stroma infiltrated with small round-cells, containing scattered spherical nodules resembling new-formed non-caseating tubercles. Each of these is bounded by circularly arranged connective tissue, which is pro-

Digitized by Google

longed by branching processes into the centre, which is occupied by a giant-cell (often multinucleated).

There is no appearance of caseation in any part. A few newly-developed blood-vessels are seen traversing the section but do not appear to enter the nodules. There is little or no normal ovarian stroma. The peritoneal surface is thickened and consists of fibrinous exudation invaded by leucocytes.

Fallopian tubes.—The fibro-muscular wall is expanded and thin, the mucous membrane is thick and consists almost entirely of tissue similar to that in the ovary, only containing very few tubercles, and it is permeated everywhere by minute channels lined by a single layer of cubic epithelium or endothelium. These may be either blood- or lymph-vessels, the walls of which are irritated and the endothelial cells enormously enlarged. In some there is evidence of blood stasis.

Dr. Vincent Harris, who examined the sections for tubercle bacilli, adds "that although the staining was done with great care, no micro-organisms were found either in the giant-cells or in the surrounding tissues. The giant-cells are much branched and appear to show no differentiation into an outer coat and contents. They appear to be of quite recent formation and of rapid growth."

Literature. — The literature of tubercular affections of the ovaries is, so far as records of cases and specimens constitute literature, not quite so scanty as first inquiries seemed to promise. The references given below have in every case, unless otherwise stated, been verified, and this was especially necessary from the fact that cases of tuberous and tuberculated ovaries, such as that recorded by Renton (sometimes quoted as Henton) in the 'Edinburgh Medical and Surgical Journal,' April, 1827, No. 91, is undoubtedly a case of malignant disease of the ovaries and peritoneum, though generally referred to as a case of tubercle. Others are cases of dermoid cysts.

Tubercular disease of the ovary, so far as we know at present, unless the specimen under discussion is an exception, exists in two forms, firstly, in the form of minute grey miliary tubercles situated on the surface, in or beneath its quasi-peritoneal covering. This form generally occurs in cases of general peritoneal tubercle, and is probably commoner than the records seem to show. It may also occur in cases of general tuberculosis without peritoneal tubercle, as recorded by Talarmon.

Digitized by Google

The second form is that of numerous caseous masses in the substance of enlarged or cystic ovaries. This must be rare, as our museums, with the exception of St. George's, St. Thomas's, and Guy's, so far as I have been able to ascertain, contain no specimens, and the number I have found recorded is only thirty-four; but in all these, with one exception, the tubercle was caseous. There is only one specimen recorded, and this by Tonnelé, in which non-caseating tubercle was found in the substance of an ovary, but in this case caseating masses were also present. It is obvious that if caseous masses are absent, the presence of tubercle would very probably be overlooked.

The two cases of cystic disease of the ovary in which caseous masses were found are recorded by Sir Spencer Wells (the diagnosis having been verified by Dr. Wilson Fox) and by Baumgarten. Baumgarten was unable to find bacilli.

The specimen in the museum of St. George's Hospital, No. 26 A, series xiv, for permission to examine which, I am greatly indebted to the Museum Committee, is one of this kind. There is no history of the specimen but that it was presented by Mr. Cæsar Hawkins.

The ovary has been divided longitudinally, and the half preserved measures five and a half inches in length by three in breadth; it is kidney shaped, and contains several cysts, the diameter of the largest being about one and a half inches; the walls of the gut are for the most part thick, in parts are studded with minute cysts the result of mucoid degeneration of the stroma, and in parts are caseous.

The stroma of the non-caseous portion presents the characters of the well-developed connective tissue usually forming the walls of ovarian cysts, but there is a marked tendency to mucoid (?) softening of the fibres, which are atrophied and separated by translucent spaces. There is no general infiltration in these parts with lymphoid cells, but groups of large round-cells are occasionally seen; many of the cells have fallen out, but those that remain are similar to those seen in the caseating portions. In one instance a large nucleated cell, resembling a giant-cell, is seen lying by itself in the stroma, but close to a group of lymphoid cells.

The caseating portion consists of masses of large round-cells lying in a delicate reticulum of fibrin or connective tissue. In

Digitized by Google

places there is a very firm reticulum with corpuscles smaller than these, not unlike a very recent inflammatory exudation. Some patches of the large cells take the staining well, others badly, and are indistinct from caseation. Although many of these cells are so large as possibly to be giant-cells, typical giant-cells are not very numerous. There is much fatty granular matter scattered about.

There are no tubercle bacilli, but multitudes of micrococci indicating decomposition.

Tubercle of the ovary occurs almost invariably as a part of a general disease, the lungs, meninges of the brain, the bowels, peritoneum, or lymphatic glands being at the same time affected. I have not met with a case recorded in which there is satisfactory evidence of the disease being primary. In this respect it differs from tubercular disease of the Fallopian tubes and uterus, in which occasionally primary disease almost certainly occurs.

Tubercular disease of the Fallopian tubes is almost invariably present, and sometimes of the uterus, in cases in which the ovary is affected.

Tubercle of the female generative organs is less common than of the male, and with the exception of the extremely rare cases recorded of tubercular ulceration of the cervix (Friedländer) and of the vagina (Reynaud), the ovary is most rarely the seat of disease. The Fallopian tubes are most frequently affected, the mucous membrane of the body of the uterus much more rarely, and the ovaries still more rarely.

Comparing this with the seats of disease in the male organs, it is curious to note that though the Fallopian tube is not the homologue of the epididymis and vas deferens, yet that these are the commonest seats of the disease in both sexes, while the paroophoron and its duct, which in part persists throughout life and are the real homologues of the epididymis and duct, escape.

The age at which the patient died is given in some of the cases; the youngest was 5 years old and the oldest 55 years. Five cases occurred in children under 14 years, eleven between 14 and 45, and one at the age of 55. Eight cases occurred between the ages of 14 and 25.

Tubercle of the female generative organs possesses a pathological rather than a clinical interest. The almost invariable association of it with tubercle of other organs more important to life, the absence of important symptoms, and the great difficulties of exact

Digitized by Google

diagnosis are a sufficient explanation of this. Yet there is a clinical history to be worked out, on the lines, probably, of the disease remaining latent in some cases, the organs affected not being important to life or health, and the probability that in some cases the disease is eliminated by suppuration, and, if this process is not in itself fatal chiefly by leading to general peritonitis, the disease may be cured, leaving, however, the affected organs permanently damaged, and especially the oviduct, the organ most frequently affected. May not the so-called idiopathic cases of suppurative salpingitis in girls and young women, who are beyond suspicion of gonorrhœa, or other similar causes, be due sometimes to this? May not this be sometimes a cause of sterility, and even of extra-uterine gestation, in the rare cases, such as the cases I recorded in the 'Transactions' of last year, in which in the first pregnancy the ovum fails to reach the uterus, and, after death, the mucous membrane of both tubes is found damaged or destroyed, and there is no history of any severe illness before the fatal one?

Amongst the twenty papers on the subject, the references of which I have been able to verify, there is no one which can be selected as being at all exhaustive. Many of them are more or less imperfect records of cases or specimens, the others are papers on tubercle of the female generative organs as a whole, and little is said about tubercle of the ovary. The papers of Olshausen and Hegar are perhaps more important than the others, and there are four or five which I have been unable to obtain, including a paper by Geil, which is more frequently referred to by German authors than the others.

Cases are recorded by the following English authors:

By Mr. Tomlinson;—A lady, aged 55, who died with extensive caseous degeneration of the uterus, Fallopian tubes and ovaries. No other organ appeared to be affected. She had been ill for fifteen months, gradually losing flesh.

By Mr. Fletcher Beach;—A child, aged 7 years, died of tubercular meningitis. The ovaries and uterus were infiltrated with caseous material.

By Sir Spencer Wells;—A single lady, aged 22, from whom he removed a large ovarian cyst. Dr. Fox, reporting on the tumour, says that on the surface were numerous minute nodules. On section these were semi-translucent externally, with caseous centres.

Digitized by Google

The tissue round the nodules was injected, but the vessels did not enter the nodules. Fine grey miliary tubercles were scattered in the injected areas and elsewhere. The patient, who was very ill at the time of the operation, died, but no examination of the body was allowed.

Mr. George Pollock, in an interesting paper read before the Royal Medical and Chirurgical Society in 1852, records the frequency of disease of the female generative organs occurring in 583 *post-mortem* examinations made in the course of nine years at St. George's Hospital. Among these were four cases of tubercle of the ovaries, in two cases with pulmonary phthisis, in one with general tuberculosis, and in the fourth with tubercular peritonitis. In all the cases both ovaries were enlarged, and filled with caseous matter. The age of the youngest was 18, of the oldest 23 years.

By Dr. Bristowe;—The patient, aged 25 years, died with general tuberculosis; the uterus and tubes were caseous, and the left ovary contained two large masses,

Cases are recorded by the following French authors:

By Talarmon;—A girl, aged 6 years, died from tubercular meningitis; the ovaries were enlarged and transformed into yellow caseous masses, and embedded in a thick caseous exudation. There was commencing tubercular disease also of the tubes.—He also states that it is not rare to find minute miliary tubercles on the peritoneal surface of the ovaries and uterus in young girls who have died of general tuberculosis without any other signs of peritoneal tubercle.

By Senn;—A girl, 5 years old, died from tubercular pneumonia and enteritis; the uterus, tubes and ovaries were caseous.

By Tonnelé;—A child, 5 years old, died from tubercular meningitis; the ovaries were enlarged and contained many tubercles, some crude, others softening.

By Madame Boivin;—A girl, aged 16 years, died of general tuberculosis, the catamenia having been regular since 12 years of age. The left ovary was the size of a small hen's egg, was irregular, and contained several masses of tubercular matter, white, and easily crushed. The right Fallopian tube and uterus were also affected.

Louis mentions that he has seen tubercular masses in ovaries on two occasions, but gives no details.

Reynaud records a case of tubercle of the uterus and vagina, of a woman aged 45 years, who died of pulmonary phthisis. She

Digitized by Google

had had seven children the last ten years before her death. The uterus and tubes were caseous, the ovaries were cystic and full of friable tuberculous matter.

Cases are recorded also by most of the following German authors:

Hegar, in a recent valuable paper on tubercle of the female generative organs, remarks on the rarity of tubercle of the ovary,

Olshausen says little more, but gives some valuable references.

Rokitansky records one case in a woman, aged 44 years, of tubercle of the lungs, bowel and peritoneum, in which there were caseous masses in the ovaries and Fallopian tubes.

Kussmaul records a case of a woman whose father died of phthisis. She died at the age of 33, with general tuberculosis; there were several caseous masses in ovaries.

Baumgarten records a case of a girl 14 years old, from whom he removed an ovarian cyst, parts of which had undergone tubercular degeneration. There were no bacilli found.

Scanzoni saw one instance in a woman recently delivered, who died of tubercular peritonitis.

Klebs describes a specimen in the Pathological Institute at Prague, associated with tubercle of the uterus, and speaks of three or four cases he had seen, generally associated with adhesive perioophoritis (Olshausen).

Gusserow describes two cases of caseous masses in both ovaries, with degeneration of the uterine mucous membrane (Olshausen).

Mosler, whose thesis I have not been able to obtain, states that he found tubercle of the ovaries in seven cases (Olshausen).

Namias, an Italian author, records the case of a scrofulous girl, 12 years old; the ovary was the size of a pigeon's egg, and contained tuberculous matter (Olshausen).

References (Verified).

English.

Beach.—'Trans. Obst. Soc.,' vol. xv, p. 57.
Tomlinson.—'Trans. Obst. Soc.,' vol. v, p. 174.
Pollock.—'Dublin Med. Press,' February, 1852, vol. xxvii, p. 101.
Wells.—'Diseases of Ovaries,' 1865, p. 228.
Bristowe.—'Trans. Path. Soc.,' 1855.

French.

Talarmon.—'Annales de Gyn.,' t. ix, p. 416.

Digitized by Google

Senn.—'Arch. Méd.,' t. xxvii, p. 262.
Tonnelé.—'Journal hebd. de Méd.,' t. v, p. 149.
Boivin and Dugès.—'Traité Pratique' (translation by Henning), p. 174, and plate xvi.
Louis.—'Recherches sur la phtisie' (Sydenham Trans.), p. 119.
Reynaud.—'Arch. Gén. de Méd.,' series i, t. xxvi, p. 499.

German.

Hegar.—'Die Entstehung Diagnose, &c., der Genitaltuberculose des Weibes,' Stuttgart, 1886.
Olshausen.—'Deutsche Chirurgie,' Lief. lviii, p. 439.
Rokitansky.—'Allg. Wien. med. Zeitg.,' 1860, No. 21, p. 163.
Kussmaul.—'Würtzb. med. Zeitsch.,' 1863, p. 24.
Baumgarten.—'Virchow's Arch.,' Bd. xcvii, p. 11, 1884.
Scanzoni.—'Diseases of Women' (translation by Gardner), p. 289.
Lebert.—"Ueber Tub. d. weib. Geschlechtsorg.," 'Arch. f. Gyn.,' Bd. iv, p. 457.

Other References.

Namias.—'Sulle tub. dell' uter., &c.,' Venezia, 1861.
Gusserow.—'De Muliebrum genital. tuberc.,' Diss., Berlin, 1859.
Geis.—'Ueber die Tub. d. weib. Genitalien,' Erlangen, 1851.
Mosler.—Diss., Breslau, 1883.
Abrt.—Diss., Göttingen, 1880.
Klebs.—'Handbuch d. path. Anat.'

November 6th, 1888.

---

28. *Tubercle of the ovary.*

Additional notes by W. S. A. Griffith, M.D.

Since reading my paper on this subject I have received, owing to the kindness of Mr. Edmunds and Dr. Horrocks, some additional specimens and notes of cases, short abstracts of which are appended.

The histological characters as well as the naked-eye appearances are practically identical with those previously described, and I have succeeded in one specimen, namely, that sent me by Dr. Horrocks, in demonstrating the presence of tubercle bacilli. I am indebted for this to Mr. Robinson, of St. Bartholomew's Hospital, who has taken great trouble in preparing and examining many sections before we

Digitized by Google

succeeded in isolating them. They appear to be very scantily distributed.

I am indebted to Mr. Edmunds for the notes of the following cases; the specimens are preserved in the museum of St. Thomas's Hospital.

Case 1, aged 21 years.—At the age of 15 suffered from pelvic pain and a purulent discharge from the anus at the time of defæcation; a small lump was found in the right inguinal region. At the age of 21 she was admitted into St. Thomas's Hospital with the same symptoms and with strumous cervical glands. The left tube and ovary were removed; the ovary, measuring 2 by 1½ inches, contained caseating tubercular masses. The patient died on the fourth day, and the disease was found to be general.

Case 2, aged 34, married; no pregnancy.—Both ovaries and tubes removed, being much enlarged, and the seat of severe pain. The right ovary was caseous and suppurating, the left cystic. Patient died the fourth day. No tubercular disease found elsewhere.

Dr. Horrocks will publish his case in full. He removed an ovary from a girl aged 16 or 17 years, who came under treatment for ascites.

This ovary was considerably enlarged and contained rather dense caseous masses. The stroma consists of well-developed connective tissue, infiltrated with minute round, deeply-staining cells, and contains large giant-cells, in one of which, as well as in the stroma, we found tubercle bacilli.

There is also a case recorded by Kötschau, "Ein Fall v. genital Tuberkulose" ('Arch. f. Gyn.,' Bd. xxxi, p. 265; with plates), aged 45 years; five children. A caseous mass was found in the right lung, both ovaries and tubes, and in the fundus uteri.

May 21st, 1889.

Digitized by Google

29. *Sequel to the case of primary cancer of the Fallopian tube reported in the Thirty-ninth volume of the Society's 'Transactions.'*

By Alban Doran.

[With Plate XIII.]

Through the courtesy and vigilance of Dr. Amand Routh, I am enabled to exhibit this evening the pelvic viscera from the case of primary cancer of the Fallopian tube described in the Society's 'Transactions,' vol. xxxix, p. 208.

After suffering from a watery, ultimately sanious, discharge for three years, a tumour developing in the right side of the pelvis, the patient came under the care of Mr. Thornton, who, on March 1st, 1888, removed the tumour, which proved to be a cancerous Fallopian tube. The right ovary was infected, part of it was left behind. The left appendages were removed, being spoilt by old inflammatory changes. I could not find any morbid growth in either the left tube or the ovary. The stump of the left appendages, at the end of the operation, was certainly free from disease, an important fact in relation to the sequel. The uterus, in Mr. Thornton's own words, "was not so large as I thought at first, and seemed fairly firm and healthy, so that I rather doubted if there was any of the growth in it." Thus, excepting a small portion of the right ovary, no suspected tissue was left behind; but the ovary was found to be cancerous, through infection, I believe, from the tube where the disease formed a much larger growth. The general and microscopical appearances are represented in plates xiii and xiv accompanying the original paper.

In that paper I reported, "In August, 1888, she was in good health." That note was made early in August. Dr. A. Routh further noted, since the publication of the paper, that on August 10th the patient had an attack of acute obstruction of the bowels whilst at the seaside. On September 10th a large mass was discovered in the hypogastric region surrounding the uterus, but lying more to the left than to the right. The patient had suffered from chilliness, leucorrhœa, and pain in the back, hypogastrium, and legs for a week. The tumour was mobile. On October 23rd

Digitized by Google

the tumour was larger and less mobile. The patient, in the course of that month, came under the care of Dr. Calthrop, of Hornsey. He noted the increase of the tumour. There was little discharge, but considerable pain at times, especially with the action of the bowels. By the middle of December the tumour could be felt running up nearly to the level of the umbilicus. On the right side, on vaginal examination, "the whole parts were pressed out of shape by irregular masses of cancer. The pain was not so great, nor the sickness frequent." In the middle of January Dr. Calthrop writes, "Sudden sickness took place, followed by incessant diarrhœa, extreme prostration, and death on January 23rd, 1889. The mass was growing fast up to the end of the case."

Thus died the patient, aged 49, after four years of local illness. She survived the operation ten calendar months and twenty-three days.

Dr. A. Routh, with the aid of an assistant, examined the abdomen after death. He found the true pelvis blocked everywhere with cancerous masses. The intestines all round were involved and adherent. There were deposits along the glands, but the liver was free. As in many cases of intraperitoneal cancer the masses felt during life more or less like a single tumour, although their separate character was detected, as the above notes prove. They were always ill-defined, and for this reason, and possibly on account of irregular increase in size, and inflammatory changes in contiguous structures as well, it was not always easy to decide whether the disease was most marked to the right or to the left of the middle line.

The pelvic viscera were removed and brought to me. I immediately took them to the College of Surgeons, removing at once portions of the secondary deposit for microscopic purposes. The viscera were then washed and placed in spirit. They included the entire uterus, with the stumps of the appendages, the upper part of the vagina, the bladder, with part of the urethra, and a small portion of the anterior wall of the rectum.

The uterus measured three inches and a half from the fundus to the os externum. Broad membranous bands of adhesion passed between its anterior aspect and the serous investment of the back of the bladder, especially towards the left. Some of these bands were connected with the stump of the left appendages. One broad band passed from the fundus directly to the left to find

Digitized by Google

attachment to the stump, forming a pouch in front of the uterus, in which lay part of the left round ligament. These bands seemed to represent recent peritonitis; none passed from the right stump to the uterus or bladder.

The cervix was thick and soft. The os externum was circular and entire. In the vaginal portion of the cervix I found no trace of malignant ulcer, solid tumour or loss of tissue, but the surface was studded with minute secondary deposits.

The walls of the bladder were much thickened, and its cavity capacious. The mucous membrane was deeply injected; on its surface were streaks of dark congested tissue and abundant secondary deposits forming white specks slightly elevated.

Much fat lay in the subserous tissue, especially in front of the bladder and on the left side of the pelvis towards Douglas's pouch. Similar deposits of fat are frequently seen in cases of rectal cancer.

A spherical mass of new growth, three quarters of an inch in diameter, lay to the right of the cervix in Douglas's pouch. It evidently represented the portion of the cancerous right ovary which the operator was obliged to leave behind (loc. cit., p. 209). Mr. Thornton could not have left much of the diseased ovary in the pelvis, for the mass was not an inch in diameter at death, nearly eleven months after the operation. Hence the entire cancerous ovary must have been very small when Mr. Thornton operated. I may fairly urge that this fact strongly favours my original view, considering the large size of the tubal growth, that the ovary was not the seat of the primary disease.

The stump of the right appendages (which included the cancerous tube) had completely cicatrised, and was not the seat of malignant deposit.[1] On laying it open no trace of the ligature could be found. The portion of the canal of the tube which traverses the uterine walls was converted into an oval, perfectly closed cystic cavity, half an inch in long diameter. It was filled with grumous, partially decolourised clot, and its mucous lining was thickened, but free from any malignant growths. The uterine end of the amputated tube contained similar clot, and was also free from cancer (loc. cit., p. 210, and plate xiii, fig. 1, *b*). The uterine orifice of the tube was absolutely closed.

[1] See Mr. Thornton's note of the operation quoted in my original paper. I there observed that the diseased tissue, which he described, was probably decolourised clot.

Digitized by Google

The stump of the left appendages bore two tuberous masses new growth, each an inch in diameter. The uterine orifice of the left tube was closed. The infection of the left stump must have commenced after the operation, as the left appendages were then free from cancerous disease, though damaged by old perimetritis.[1]

On laying open the uterine cavity I found that the endometrium like the vesical mucous membrane, bore a number of small white elevations, caused by secondary malignant deposit, which in places extended into the muscular coat. The canal of the cervix was similarly affected, as was also the vaginal mucous membrane. No solid circumscribed tumour could be found in the uterine walls, nor was there any malignant ulceration of the endometrium.

Thus, cancerous infection had spread to the endometrium and to the stump of the left appendages. The remains of the cancerous right ovary had increased but slowly considering the stage of the disease. Portions of cancer cut through and left behind at operations usually grow quicker.

Considerable difficulty was experienced in making good sections of the cancerous growths as the spaces in which the cells were packed were wide, so that the cells fell out during the processes of cutting, staining, and mounting after the usual methods. By embedding pieces of tissue in celloidin after hardening, Mr. Targett succeeded in preparing the fine sections which I show to-night.

The tuberous masses found in the stump of the left appendages consisted of the most characteristic cancerous deposit, mixed with much healthy connective tissue and fat. The trabeculæ were wider than in the primary cancerous growth which grew in the right tube, and in the extension of that growth to the right ovary. The connective tissue of which the trabeculæ were formed was in parts densely fibrous as in scirrhus, in other places loose. Small-celled infiltration was marked at certain points, though less generally diffused than in the original growth. In the looser parts of the trabeculæ were numerous oval or circular holes regular in outline. At first I took them for thin-walled vessels, but no endothelium could be detected. Some of the holes might represent mucoid degeneration of the stroma. As, however, I found collections of large cells in many of them, I conclude that the holes were mostly very small areolæ.

[1] I could find no trace of the left ovary. Mr. Thornton evidently removed it entire, contrary to his opinion at the time.

Digitized by Google

The areolar spaces formed by the trabeculæ were well defined and often widely separated from each other, on account of the thickness of the trabeculæ. The cells which the spaces contained were large and similar to those which filled the spaces in the primary growth. The cells had not undergone advanced changes such as were seen in the growth which had invaded the right ovary (loc. cit., plate xiv, fig. 4). In no places did fibres from the stroma pass from the trabeculæ between individual cells. In fact, the appearances plainly indicated cancer and not sarcoma.

The drawing represents a section as seen under a half-inch objective (Plate XIII, fig. A). It displays those peculiarities in the cells and the trabeculæ which have just been described. If the border regions between the collections of large cells and the trabeculæ be viewed under an eighth-inch objective, the appearances will be very similar to what was seen in similar regions in sections from the original growth in the tube (loc. cit., plate xiii, fig. 2). On the other hand, a section from the original tumour, when viewed under a half-inch objective, bore a close resemblance to the section now exhibited. Of course, I refer to the actual cancerous deposit only, and not to the normal tubal tissues invaded by that deposit, nor to the remarkable tubular structures (loc. cit., pl. xiv, fig. 3), limited to the primary growth.

I found similar appearances in sections made through the cancerous deposits on the endometrium. The epithelium had disappeared, the deposit lying chiefly in the submucous tissue, although it invaded the muscular wall of the uterus in many places.

That the cancerous deposits in the uterus were secondary there can be no doubt. I have already recorded the evidence that the cancer of the right ovary was secondary also. Hence the disease was primary in the right Fallopian tube. The tumour which it formed was discovered by Dr. A. Routh about one year before operation. As I remarked last year, had the tumour been ovarian it would, according to my experience of malignant ovarian disease, have obtained a much greater size after twelve months' growth.

I am now able to add to my observations in the original paper some additional information on the experience of others in regard to malignant disease of the Fallopian tubes. Of primary carcinoma I find three cases satisfactorily recorded; of primary sarcoma, two cases. Of secondary carcinoma of the tube I need say nothing, for quite recently Dr. Orthmann has published a good summary of

Digitized by Google

cases, thirteen in all, though microscopic evidence is not always forthcoming. They are recorded in his article "Ueber Carcinoma Tubæ" ('Zeitschrift für Geburtshülfe und Gynäkologie,' vol. xv, part 1), and I find that only one case of primary cancer has occurred in Dr. Martin's practice. That case I noticed last year. The second case was that which I then described, and now have the opportunity of recording in full. The third occurred in the practice of Professor Kaltenbach, since the publication of Dr. Orthmann's paper and my own.

Before briefly recording Professor Kaltenbach's case, I must observe that I overlooked last year a second case of primary sarcoma of the tube. It occurred in Dr. Landau's practice, and is described by Dr. Gottschalk in the 'Centralblatt für Gynäkologie,' vol. x, 1886, p. 727. The patient was thirty-seven years old, and had borne three children. After she had suffered three months from pain, chiefly to the right of the hypogastrium, a tumour "as big as a walnut" was found to the right of the uterus, which lay in its normal position. Behind this tumour was a large mass "as big as an apple." Small firm masses could be felt in Douglas's pouch. The larger tumour proved, at the operation, to be a blood-cyst, lying between the sacrum and the ovary. The masses in the pouch were secondary deposits. The tumour, "as big as a walnut," lay in the abdominal portion of the right tube, the lumen (? ostium) of which was pervious. There was no mention of ascitic effusion. The patient died four days after operation; no necropsy was permitted. The tumour was a small-celled spindle-celled sarcoma. Unfortunately, as in Dr. Senger's case of sarcoma, no drawings have been published of the microscopic appearances of the tumour. Dr. Gottschalk's is the youngest case in which primary malignant tubal disease has been recorded.

The third case of primary carcinoma of the Fallopian tube is described in the 'Centralblatt für Gynäkologie,' No. 5, 1889, p. 74. The patient was fifty years old when she was operated upon by Professor Kaltenbach. For four years she had been subject to constant discharge of a sanious watery fluid. In this respect the case resembled that which I have described. For eight weeks before operation the patient suffered from severe pains in the right half of the pelvis, which radiated towards the epigastrium and lower extremities. Both tubes were found to be cancerous,—the left "as big as a plum," the right "the size of a fist." The operation

Digitized by Google

was performed on July 11th, 1888. When last heard of, over five months after operation, the patient was in good health. Both tubes were filled with medullary papillomatous growths which sprang from the mucous membrane and encroached on the muscular coat, precisely as in my own case. On the right side cancerous material projected under the peritoneal investment of the tube. The ovaries and uterus showed no signs of cancer. The case appears to represent simultaneous cancerous degeneration of papillomatous tubes. I understand that a more complete account will shortly be published by Dr. Kaltenbach.

The following table of the five cases of primary malignant disease of the Fallopian tube may prove useful for comparison and reference. As may be gleaned from the fuller accounts of the same cases already given in the present and the original papers, the sexual history is, in more than one instance, incomplete,[1] so that I have not introduced into these tables any columns with the heading "married or single," "number of children," &c.

The evidence which can be gleaned from this table tends to confirm certain opinions which I expressed at the end of the original paper on Mr. Thornton's case. Papilloma of the Fallopian tube appears to have an inflammatory origin. It may proceed till large masses of papillomata develop, these growths being perfectly innocent, although they may even provoke ascites and hydrothorax. On the other hand, the papillomatous vegetations may undergo malignant degeneration. In short, cancer of the tube appears to spring from papilloma of the tube. Carcinoma of the Fallopian tube occurs near the menopause, and is accompanied by vaginal discharge, generally sanious. Its course is apparently slower than that of cancer in most other organs; certainly far less rapid than in ovarian cancer. Evidence as to the origin and precise nature of sarcoma of the Fallopian tube is as yet very scanty. Only two cases have been recorded, and no drawings of either appear to have been published.

May 7th, 1889.

[1] In his paper, "Ueber Carcinoma Tubæ," loc. jam cit., Dr. Orthmann notes that Martin's patient, aged 46, was a widow. She had been married three years, and there was a doubtful history of abortion a year and a half before operation. When she became a widow is not stated. She menstruated about a month before operation. After the "lumps" were noticed in the abdomen during her convalescence from typhoid fever a moderate leucorrhœal discharge set in. The principal features of this case were recorded in my paper on cancer, published in the 'Transactions' of last year.

Digitized by Google

Cases of Primary Malignant Disease of the Fallopian Tube.

I.—CARCINOMA.

No.	Age.	Side.	Chief Symptoms.	Duration of Symptoms before Operation.	Result of Operation.	Character of Tumour.	Other Parts Involved.	Operator.	Reference.
1	46	R.	Tumour to right of uterus, then moderate leucorrhœa. Encysted serous perimetritis to left	About 1½ years	D. 6th day	Cancerous papillomatous masses	Cancerous nodules in vesico-uterine pouch. Enlarged pelvic glands. Large abscess of right ovary. Suppuration of left tube and ovary	Martin (Berlin)	Orthmann, "Ueber Carcinoma Tubæ," 'Zeitschr. f. Geburtsh.,' vol. xv.
2	48	R.	Sanious, watery discharge; perimetritis after scraping of endometrium. Then tumour to the right of uterus	3 years	Lived 10 months, 3 weeks	Large soft cancerous masses growing from tubal walls	Right ovary small, cancerous. Left appendages much diseased through old inflammation. Recurrence in stump of left appendages. Secondary deposits in uterus, bladder, vagina, and lumbar glands	Thornton	Author, 'Trans. Path. Soc.,' vol. xxix, p. 208, and present paper.
3	50	R. & L.	Sanious, watery discharge	4 years	Well 5 months after	Medullary papillomatous masses in both tubes	Apparently no extension to neighbouring organs	Kaltenbach	Kaltenbach, 'Centralbl. f. Gynäk.,' 1889, p. 74.

II.—SARCOMA.

1	51	R. & L.	None. Disease discovered after death of patient from diabetes	...	...	Two oval dilatations in each tube, containing papillary masses made up of round-celled sarcoma	...	...	Senger, 'Centralbl. f. Gynäk.,' 1886, p. 601.
2	37	R.	Hypogastric pain; tumour to right of uterus	3 months	D. 4th day	Small-celled spindle-celled sarcoma in abdominal half of tube	Secondary deposit in Douglas's pouch; blood-cyst behind ovary	Landau	Gottschalk, 'Centralbl. f. Gynäk.,' 1886, p. 727.

Digitized by Google

VI. DISEASES AND INJURIES OF THE OSSEOUS SYSTEM.

1. *An account of the skeleton of the Norwich dwarf.*

By JONATHAN HUTCHINSON, F.R.S.

[With Plates XVIII and XIX.]

THIS skeleton, which is the property of the museum of the Norfolk and Norwich Hospital, was lent to me for exhibition through the kindness of Mr. Cadge and Mr. Cross, the latter of whom is the custodian of the collection. The skeleton is that of a man who was executed for the murder of his child and attempted murder of his wife in August, 1819. The crime was effected by the administration of poison. His age was 35 years. The newspaper account of the case states that "his personal deformity was in singular unison with his moral depravity." His height from the crown of his head to the sole of his foot was four feet two inches. No particulars are forthcoming as to his character previous to the crime for which he was executed, but it is stated that at his trial "his countenance, which was as singular as his diminutive figure, remained unmoved and unaltered." It is added that he was exceedingly attentive to religious instruction, and received it thankfully but unimpressively. "To the last, in spite of his confession, his thoughts, incapable of spiritual reflections, were more employed on his vindication than his salvation." Although but few facts are forthcoming, it is clear that a general impression was formed that he was a man of very inhuman character. This fact becomes of great interest in connection with the singularly brute-like formation of the bones of his extremities. His dwarfed character was almost wholly due to the shortness of his legs, for there was nothing peculiar in the length of the vertebral column. His upper extremities were shortened in like proportion with the lower ones, the tips of his fingers only just touching his great trochanters. It may

Digitized by Google

be briefly stated that almost all the larger bones of his limbs were short and remarkably thick but that none of them were in any way curved as in rickets. They showed strongly-marked projections for the attachment of muscles, and were, indeed, developed on an exceedingly coarse type. His head, although ill-shapen, narrow, and rather high, was not smaller than the average. The following measurements of his limbs are taken from the account which was published after his execution and before the dissection:

His height from the crown of the head to the foot was four feet two inches.

Measuring from the same point to the top of the breast-bone the distance was	13 inches.
From the latter point to the extremity of the trunk	19 „
Length of the thigh	8 „
Length of the leg	8 „
Which with the foot made up the whole	50 „
Length of the upper arm	6½ „
Length of the lower arm	7 „
Length of the hand and longest finger	5½ „
Circumference of the wrist	6½ „
Circumference of the knee	14 „
Circumference of the ankle	8 „
Breadth of the shoulders	4 „
Breadth across the hips	12 „
Circumference of the skull	23½ „
Distance from the tip of the chin and crown of the head	9 „
Circumference of the neck	14½ „
Circumference of the trunk measuring round the lower end of the breast-bone	32 „

The following description of the skeleton is in part compiled from detailed measurements which were kindly made for me at the Royal College of Surgeons by Mr. Garson.

General statement as to the measurements of bones, &c.—Bones of trunk fairly normal. Bones of the limbs arrested in growth. Skull long and narrow, smooth, without marked prominences. Sutures open. There is a marked want of expansion of the upper part of the skull, and the frontal bone is very narrow. The spinal column is apparently normal, until the sacrum is reached. This bone is set almost at right angles to the spinal column. The ribs are somewhat heavier and more narrow than usual. The clavicles are arched upwards. The humerus is much shorter and thicker

Digitized by Google

Digitized by Google

EXPLANATION OF PLATE XVIII.

Illustrating Mr. Hutchinson's description of the Skeleton of the Norwich Dwarf. (Page 229.)

(From a photograph.)

The shortness of all the limbs, the thickness and coarse development of the principal long bones, and the peculiar shape of the sternal ends of the clavicles are well shown.

Digitized by Google

Digitized by Google

Digitized by Google

Digitized by Google

EXPLANATION OF PLATE XIX.

Illustrating Mr. Hutchinson's description of the Humerus and Forearm of the Norwich Dwarf. (Page 229.)

(From photographs.)

Digitized by Google

Digitized by Google

Digitized by Google

than natural. The radius is short and much bent by exaggeration of the normal curves. The hand and wrist normal in proportion.

The femur is diminished in length; the lower end suddenly expands into the condyles, like the head of a nail. The tibia is short, its shaft being normal. Foot normal, except in size.

The following is the detailed description by Dr. Garson of the principal bones affected: The humerus is much shorter and thicker than usual. The articular surface of the head is nearly normal; no anatomical neck may be said to exist as the articular surface is sessile on the shaft of the bone. The tuberosities are very strong and project upwards higher than the articular surface. The surgical neck is very thick, with rough and rugged ridges on it for the attachment of muscles. The deltoid insertion is exceedingly prominent, breadth across 35 mm., while the normal is 28 mm. The lower articular end is the same size as that of a normal humerus. The circumference of the surgical neck is 102, while an ordinary bone is 90 mm. The radius short and much bent by exaggeration of the normal curves of the bone. The attachment for the biceps is exceedingly developed, being broad and prominent. Muscular surfaces very strongly marked. The carpal articulation of the radius is larger somewhat than in an adult person.

The pelvic brim markedly reniform, the hilus being formed by the promontory of the sacrum. The breadth of the innominate bones is considerable in proportion to the height. The ilia are shorter than usual as is also the ischii. The crests of the ilia approach more nearly to one another than usual. The cavity of the true pelvis is absent, from the irregular position which the sacrum assumes, the latter arising almost at right angles to the direction of the spinal column. The pubic portion of the pelvis is normal. The sacrum is perfectly straight.

The femur is considerably diminished in length. The acetabular end is somewhat oval, instead of round. The neck is short and compressed from above and below, 24 mm. in width, from before backwards 39 mm. The trochanter major is well developed with rough surfaces for the muscular insertions. The top of the trochanter is higher than the level of the head of the bone. The trochanter minor is of large size, as is also the ridge running from the trochanter major to it. The shaft of the bone is short and has rough surfaces well marked. At its lower end the bone suddenly expands into the condyles, so that the condyles appear to be stuck on to the end

Digitized by Google

of the bone, somewhat like the head of a nail on to the shaft. The internal and anterior surface of the condyle is worn down.

The tibia is short, its shaft is normal, but the articular ends are modified. The anterior surface of the bone at the knee-joint is deficient, just as if the anterior part had been split off transversely and vertically. The whole articular surface is broad in proportion to the length. The lower articular end is large proportionately. The shaft suddenly expands into it.

Fibulæ, remarkable for the development of all the normal ridges of the bones, which are longer than usual for the limb and bowed. They are projecting backwards; the upper articular end is large.

The following points, in reference to the skeleton above described, appear to deserve particular attention:—First, the entire absence of indications of any stage of softness of the bones, with liability to bend. None of the long bones showed any abnormal curves whatever, nor did they exhibit any of the local developments of bone as splints which are so commonly seen in rickets. They were simply short, thick, and very strong, and with the prominences for the attachment of muscles remarkably large.

Secondly, the bones of the lower extremities, especially the femurs, showed remarkable expansion at their articular ends, much resembling the lips which are developed in connection with chronic rheumatism. It is possible that this may have implied a tendency to arthritic disease in very early life, but against such a supposition we may note that it is entirely absent in the upper extremities.

Thirdly, the alterations in form are not restricted to the long bones. The pelvis was remarkably small and its outlet narrow. The ossa innominata were not like the femora, thick and coarse, but smaller and lighter than natural. In the upper extremity the lightness and smallness of the scapula and clavicle were very noteworthy.

Fourthly, we must note the peculiarity of the clavicles, which presented a feature which I have never seen in any other skeleton. Instead of the thick knob-like end which the sternal end of a normal clavicle presents, terminating in an almost flat surface, these bones had the lower two thirds of their inner extremities wanting, so that they became almost pointed, and presented below an inclined surface, as if designed to slide backwards and forwards on the upper part of the sternum. Unfortunately no particulars as to the dis-

Digitized by Google

section of the sterno-clavicular joints are forthcoming. I do not at present see any special interpretation which can be given to this anomaly.

In speculating as to the causes of the peculiarities exhibited by this skeleton, I am inclined to doubt altogether that they have anything to do with rickets, properly so called. Not one of the features peculiar to rickets is present, nor does that disease, so far as I am acquainted with it, ever lead to simple arrest in the growth of bones without any accompanying tendency to bend. To the disease which has been described as "intra-uterine rickets" it is, however, quite possible that the case may have some affinity. The question remains, however, whether the name referred to is correctly applied. Many of our museums contain specimens of fœtuses either dead at birth or dying soon afterwards, which show remarkable defects in the growth of the limbs. I am not sure, however, that any of these exhibit the peculiarity of the Norwich skeleton, in that the spinal column, head, and ribs are not affected. I do not know of any adult skeleton in an English museum which shows conditions at all approaching to those which I have described.

Specimens 104 and 116 in the museum of the Charing Cross Hospital are of interest in connection with it. They are the two humeri and one femur of an old woman, of whom no history has been preserved beyond the fact that she was a dwarf. They resemble the bones of the Norwich skeleton in being thick in proportion to their length, and in having the ridges for muscular attachment unusually well marked. They do not, however, in these peculiarities, in any degree approach it.

Putting aside the hypothesis of rickets, in any correct use of that term, it may yet perhaps be admitted as somewhat probable that the conditions presented by this skeleton were due to some form of disease which occurred either during intra-uterine life or early infancy. It is perhaps not an improbable conjecture that the influence in question was exerted through the nervous system, and that the brute-like development of the bones of the extremities which it permitted was coincident with some correlated defect in the perfection of the brain itself. In the entire absence, however, of any history of the infancy of the subject it is not possible to go further than the conjecture.

The skeleton is clearly to be assigned to the category of short-limbed dwarfs. The term true dwarf has been claimed for those

Digitized by Google

cases in which the limbs, head, and trunk are all proportionately small. In another, and, I think, a large group, we have cases in which simply the lower extremities are short, the trunk, head, and upper extremities being of normal development. Lastly, in the third and most remarkable group, to which this case must be assigned, all four limbs are dwarfed, without any obvious implication of the spinal column and skull.

Amongst other instances of dwarfing recorded in the 'Transactions' of this Society I find one by the late Mr. Canton in 1860. It was that of a "true dwarf," the proportions of the limbs, head, and trunk being preserved. There was no evidence of rickets, and it is stated, as in the Norwich case, that the tuberosities, grooves, &c., were unusually well marked. The height of the individual is unfortunately not stated, but the dwarfing of the limbs did not approach that of the Norwich dwarf, for the humerus measured eleven and a half inches and the femur ten inches, whilst in the latter the humerus measured six and a half inches and the femur eight inches. Dr. Robert Barnes, in our Volume for 1848, has also recorded the particulars of a dwarf. It was apparently a case of arrested development in connection with chronic hydrocephalus. The child was nine years old, and his height only twenty-eight inches. As the child was still living we have no special information as to the peculiarities of the bones.

I believe it is very unusual for anything very noteworthy to occur in reference to dwarfing in the lower animals. Our museums do not contain skeletons of dwarf dogs, horses, or cattle, nor do I know of many records of such in life. Darwin has recorded the occurrence of short-limbed sheep, of which the breed was purposely preserved, as they possessed an advantageous disability in respect to getting over fences. I have recently had an opportunity for watching a young dog in which, during several months, it seemed likely that we were going to have a very remarkable example of dwarfing. This dog when a puppy from a month to two months old suffered from what was apparently general rheumatism. After he had shaken this off he presented for several months a very comical appearance of being "all head," and his limbs were so short that he could only just walk; his dentition was also much delayed. When he was about six months old, however, his limbs began to grow, and at the time of his death, a few months later, of distemper, his dwarfdom had ceased to be conspicuous. There could be no doubt

Digitized by Google

that in this case a severe infantile illness, rickets or rheumatism, or both, was the cause of the arrest of growth.

---

2. *Notes on a case of dislocation of shoulder without rupture of capsule.*

By D'Arcy Power, M.B.

J. B—, aged 69, salesman at Smithfield Meat Market, admitted into St. Bartholomew's Hospital on December 21st, 1887, under Mr. T. Smith, having fallen a distance of eighteen feet on to the pavement, pitching on his right elbow and side. On examination he was found to have a compound T-shaped fracture of the lower end of the right humerus, with dislocation of the right shoulder. The dislocation did not answer exactly to the description of either the subcoracoid or subclavicular varieties, the head of the bone being more prominent than is usually the case with the one and less so than is usually the case with the other. The coracoid process could not be felt and no crepitus was noticed.

The reduction of the dislocation was easily effected under an anæsthetic. The patient, a stout, plethoric man, and unaccustomed to confinement to bed, died twelve days after his admission of acute broncho-pneumonia.

At the autopsy the head of the humerus was in its proper position and the capsule of the joint was quite intact. It was rather lax, and its attachment to the anterior border of the glenoid cavity was slightly raised, but still quite continuous with the periosteum. The coracoid process was torn off the scapula, but still remained attached to the short tendon of the biceps; and the muscles surrounding the joint were intact, with the exception of the subscapularis, which was lacerated, and into which there had been some extravasation of blood. On opening the capsule the joint was seen to be blood-stained, and on protruding the head of the bone there was visible on the posterior part of the articular surface a groove, which on redislocation fitted the lower part of the anterior margin of the glenoid cavity. The groove was about three quarters of an inch long, and implicated the cartilage on the margin of the

Digitized by Google

anatomical neck. The capsular ligament showed signs of injury where the head of the bone had impinged against it at the moment of dislocation, and there was a small piece of the articular cartilage lying loose in the joint. The lower end of the humerus showed a good specimen of a T-shaped fracture, the olecranon being wedged between the separated condyles.

Remarks by Mr. D'Arcy Power.—In the unavoidable absence of Mr. Claude Evill, who has gone to Calcutta, I have undertaken to show this specimen. It is, I think, an extremely interesting one, but it is not quite unique, for Brigade Surgeon Lloyd tells me that there is a similar preparation[1] in the museum of Guy's Hospital; and Mr. Eve showed an almost identical case at the meeting of the Royal Medical and Chirurgical Society, held on May 4th, 1880. That specimen has been preserved in the museum of St. Bartholomew's Hospital, and I produce it for your inspection to-night. In each instance the chief interest of the case lies in the fact that the head of the humerus was so far separated from the glenoid surface of the capsule as to be completely dislocated, and this too without rupture of the capsule. In the two cases which I exhibit to-night the capsule of the joint has been partially separated, and in both, on exposing the joint, there is seen to be a well-marked indentation or groove on the posterior part of the articular surface of the head of the humerus. The presence of this groove is very remarkable, and I cannot but agree with Mr. Eve, who thinks that it was produced by the forcible impact of the humerus against the anterior margin of the glenoid cavity. From the position of the groove too it is clear that the head must have been completely separated from the glenoid cavity, so that neither of these cases can be considered as merely a subluxation. The main shock of the injury, as I read the pathological appearances, fell upon the coracoid process, which was therefore fractured. If it had been applied to the head of the humerus there would either have been an ordinary dislocation of the shoulder, or the groove might have been so far deepened that the head would have been separated, and thus the case would have been transformed into a fracture of the anatomical neck, the head at the same time slipping inwards on to the anterior surface of the scapula, with its articular surface directed forwards. As an instance of such a fracture through the anatomical neck of the humerus with dislocation of the head of the bone into this position I show

[1] No. 1019.

Digitized by Google

a good specimen. It is interesting to note that in each of the four cases of this variety of dislocation of the shoulder the head of the humerus has always been found to lie beneath the coracoid or clavicle. This coincidence is, I think, more than accidental, and is to be explained by the fact that in subcoracoid or subclavicular dislocation the excursion of the head of the bone is necessarily less than in the subglenoid or subspinous varieties, in which the capsule must be ruptured before the head of the bone is brought to a standstill.

The specimen described in this paper is preserved in the museum of St. Bartholomew's Hospital, No. 1019 *a*.

December 18*th*, 1888.

---

3. *The late Dr. Carnochan's specimen of the so-called congenital dislocation of both hip-joints; sent from New York.*

Exhibited by WILLIAM ADAMS.

[With Plates XX and XXI.]

THE specimen which I have the honour of exhibiting to the Society this evening, is one of interest as an example of the so-called congenital dislocation of both hip-joints in a female of about sixty years of age; but it is also one of historical interest as being the original specimen from which the late Dr. Carnochan, of New York (who died on the 28th October, 1887, at the age of seventy years), took his description of this affection forty years ago,[1] and published two lithograph plates of its dissection (plates vi and vii) in his well-known work on "Congenital Dislocations of the Head of the Femur," published in New York in the year 1850.

Dr. Carnochan had left a request that this, together with other specimens and drawings, should be sent to me in recognition of the interest which I had taken in his early labours on this subject, and they arrived in England on the 12th October last. I may

[1] This case was originally published in the 'New York Journal of Medicine,' in the xxxi number for July, 1848.

Digitized by Google

here remark that I am entirely indebted to Dr. Carnochan for my knowledge of this affection, which he pointed out to me in the year 1844, when he visited England, and demonstrated this subject to the staff of St. Thomas's Hospital, exhibiting a boy aged 18, Benjamin Gott, the subject of the so-called congenital dislocation of both hips, when I was demonstrator at St. Thomas's. Of this case a model exists in the museum of this hospital.

The specimen now exhibited was removed by Dr. Carnochan from the body of a woman about sixty years of age, brought to the dissecting-room, and therefore no history of the individual during life could be obtained. Dr. Carnochan recognised the condition of the hip-joints, and described the external characters before making the dissection. It consists of the pelvis, with portions of both thigh-bones, and the three lower lumbar vertebræ in a dried condition. In all the essential points it corresponds with the specimens exhibited at this Society on the 19th April, 1887, by Mr. Bowlby, Mr. D'Arcy Power, Mr. Shattock, Mr. Morgan, and myself. These were figured in vol. xxxviii, 1887, of our 'Transactions.'

The deformity of the pelvis is, however, greater than seen in any of the other specimens, and this is no doubt due to the severity of the case, and the age of the patient. All the bones are very light.

THE HEAD OF THE FEMUR has not been symmetrically displaced on both sides. On the *left side* the head of the femur was displaced directly backwards, with an inclination upwards, towards the anterior border of the sciatic notch, where a flattened circular depression indicates the spot in which the head of the femur chiefly rested, though still within the capsular ligament. The upper border of this circular depression is very little above the upper border of the notch, and two and a half inches, vertical measurement, below the crest of the ilium. On the *right side* the head of the femur was displaced towards the centre of the dorsum ilii, an inch and a quarter higher up than on the left side. The lower border of the flattened circular depression made by the head of the femur is very little below the upper margin of the sciatic notch; the upper border of the circular depression is only one inch and a quarter, vertical measurement, below the crest of the ilium.

The effect of this unsymmetrical displacement must have been to produce a shortening of the right leg to the extent of one inch

Digitized by Google

Digitized by Google

EXPLANATION OF PLATE XX.

To illustrate Mr. William Adam's paper on Congenital Dislocation of the Hip-joint. (Page 237.)

The two figures represented in this Plate, with the accompanying descriptions, are copied from Dr. Carnochan's work referred to in the text, Plates VI and VII.

FIG. 1.—Front view of a dissection of a female pelvis, with double congenital dislocation of the femurs upon the dorsa of the ilia.

a. Anterior and superior spinous process of the ilium.
b. Trochanter major.
c. Trochanter minor.
d. Anterior part of the original capsular ligament.
e. The original capsule laid open.
f. The annular opening, by which the head of the femur escaped upon the dorsum ilii.
g. The original acetabulum become now triangular.
h. The cavity of the original capsule laid open by removal of its anterior wall.
i. The neck of the femur grasped by the annular opening in the capsule through which the head passed.

FIG. 2.—Posterior view of a dissection of the same pelvis, with double congenital dislocation of the femur upon the dorsa of the ilii.

a. The crest of the ilium.
b. The dorsum ilii.
c. Posterior surface of the new capsule entire.
d. Trochanter major.
e. Trochanter minor.
f. Head of the femur lying in the new capsule.
g. New capsule laid open, showing its interior.

Digitized by Google

Fig 1.

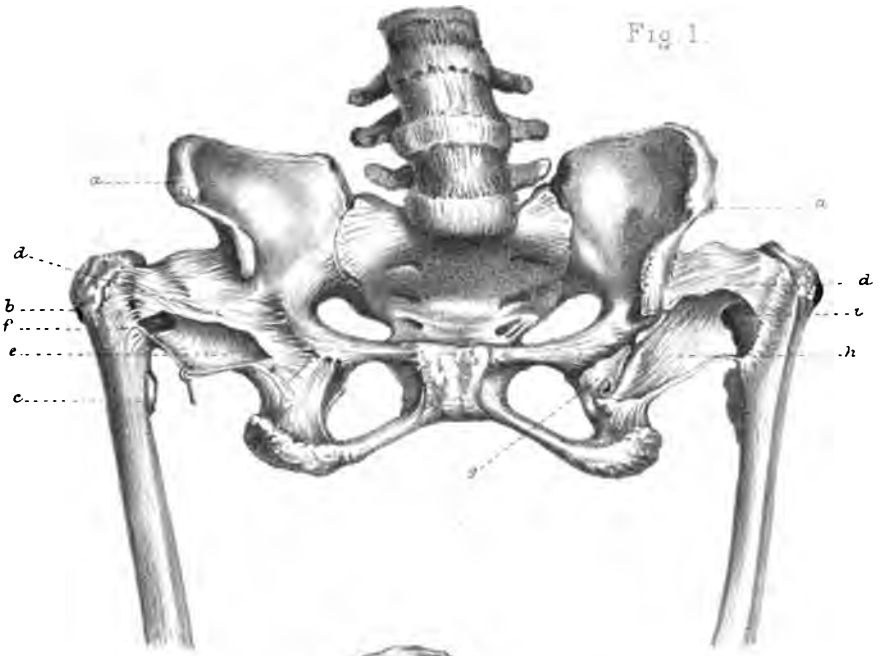

Fig 2.

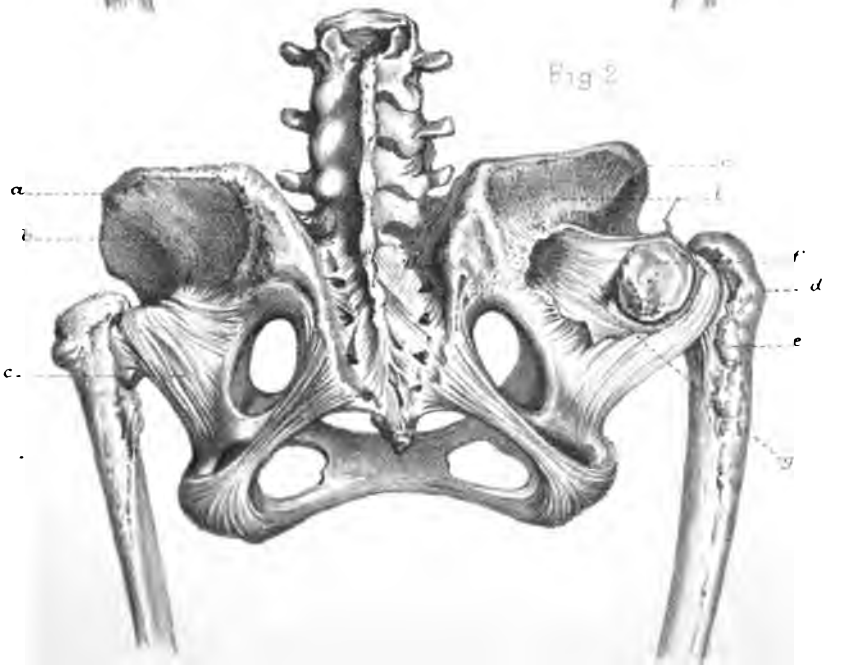

Digitized by Google

Digitized by Google

Digitized by Google

EXPLANATION OF PLATE XXI.

To illustrate Mr. William Adam's paper on Congenital Dislocation of the Hip-joint. (Page 237.)

The two figures represented in this Plate are taken from the same specimen as that shown in Plate XX, after it had been macerated and allowed to become dry. In the dried condition this specimen was not represented in Dr. Carnochan's work, nor has it been described.

FIG. 1.—Front view of the specimen, exhibiting the alterations in the pelvic bones and altered diameters of the pelvis described in the text; the triangular depression representing the acetabulum; and the lateral curvature of the spine, consequent upon the unsymmetrical displacement of the head of the femur on the two sides, in addition to the lordosis always occurring in these cases.

a, a. Anterior superior spinous process of the ilium on either side.
b, b. Anterior inferior spinous process of the ilium on either side, curved outwards.
c, c. Deep groove beneath the anterior inferior spinous process on either side, in which the conjoined tendons of the psoas and iliacus muscles played in their altered direction upwards and backwards to their insertion in the small trochanter.
d, d. Triangular depression, leading upwards from the obturator foramen representing the acetabulum.
e, e. Tuberosity of the ischium on either side, showing their abnormal separation and eversion.
f, f. Great trochanter on either side, the right being much higher than the left.
g. The three lower lumbar vertebræ, showing lateral curvature of the spine to the right side, caused by the inequality in the length of the legs by the unsymmetrical displacement of the head of the femur on the two sides.
h. Transverse process on the right side of the fifth lumbar vertebra altered in shape, flattened from above downwards, and horned upwards by resting on the crest of the ilium.
i. Sacral prominence projecting abnormally forwards and narrowing the antero-posterior diameter of the pelvic cavity.

FIG. 2.—Posterior view of the same specimen, showing the position in which the head of the femur was displaced on either side.

a, a. Head of the femur on either side. The head of the left femur is much diminished in size and altered in shape, but it is still surrounded by a portion of the capsular ligament, *b*, in a dried and damaged condition. The head of the right femur has been broken away and generally destroyed by rough usage.
c, c. Circular depression on either side, in which the head of the femur chiefly rested. On the right side this corresponds nearly to the centre of the dorsum ilii. On the left side the depression is close to the anterior border of the sciatic notch.
d, d. Sacro-sciatic notch on either side, elongated and altered in shape.
e, e. Tuberosity of the ischium on either side, abnormally separated and everted.
f. The sacrum, which has assumed almost a horizontal position.
g. The three lower lumbar vertebræ, showing a lateral deviation as well as the lordosis always occurring in these cases.

Digitized by Google

Fig. 1

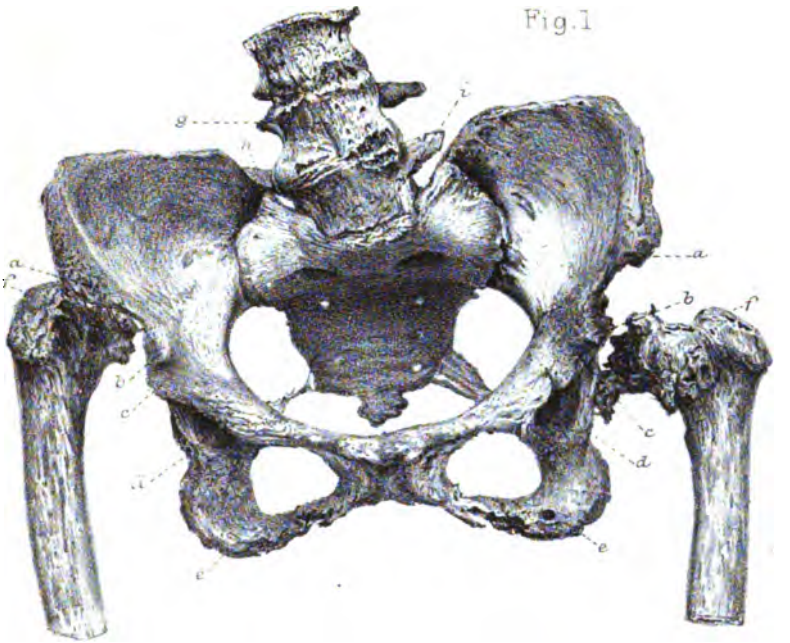

Fig 2

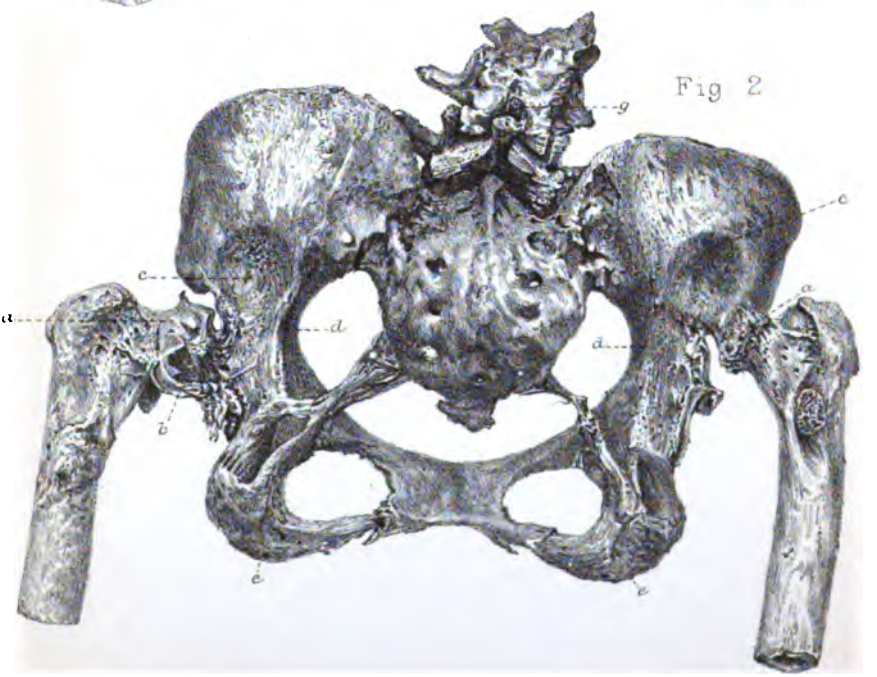

Digitized by Google

West, Newman, lith

Digitized by Google

and a quarter, and the lateral curvature of the spine seen in the specimen necessarily followed this shortening.

The head of the *left* femur is seen to be much diminished in size and altered in shape, its articular surface being flattened. It is still surrounded by the capsular ligament in a dried and somewhat damaged condition, but yet sufficiently perfect to be distinctly recognised.

The head of the *right* femur has altogether disappeared by rough usage in the course of time, but as represented in the drawings of the specimen made during the dissection, and shown in plate vii of Dr. Carnochan's work, it appears to have been rather larger than the head of the left femur, but a good deal misshapen.

THE CAPSULAR LIGAMENT.—The form and altered relations of the capsular ligament, on either side, cannot be shown in the present dried condition of the specimen, although in an imperfect condition it still remains on the left side. All this is well represented in the original drawings made during the dissection, and now presented to the Society; and is also well shown in plates vi and vii in Dr. Carnochan's work. It will be seen by reference to these drawings and plates that the head of the femur on either side remained at the time of death still distinctly within the capsular ligament, which had become elongated and enlarged in the direction of the displacement. Dr. Carnochan considered, however, that the upper portion of this capsular ligament was of new formation, and he describes it as a *new capsule* which he thought had formed after the head of the femur had escaped from the original capsular ligament of the joint. The gradual dilatation and elongation of the capsule under the influence of the weight of the body, and the absence of the acetabulum, seems to me the more probable explanation, and to derive some support from the fact observed by Dr. Carnochan that the head of the femur moved readily in a direction upwards and downwards through a space of two inches. In the course of his description of the external characters presented previous to the dissection, Dr. Carnochan remarked, p. 176, "The heads of both femurs enjoy free motion upon the dorsa of the iliac bones, and while the trochanters can be pushed upwards and outwards, so as to be within half an inch of the crests of the ilia, when traction on the opposite direction is exerted they are felt to descend through a space of nearly two inches, and become nearly on a level with a direct line drawn

Digitized by Google

transversely from the depressed anterior and superior spinous processes."

THE ACETABULUM—With regard to the acetabulum, there is a total absence of the deep spherical cup-like cavity which this naturally forms; and the innominate bone, in the region naturally occupied by the acetabulum, is considerably narrowed, presenting a narrow elongated appearance; and the form of the sciatic notch is altered to a corresponding extent.

The only trace of the acetabulum is to be found in an elongated triangular depression, the base of which corresponds to the border of the obturator foramen in the situation of the notch through which the articular vessels pass into the joint, and the apex corresponds to a point which would be naturally a little below the centre of the acetabulum. In the present specimen this triangular depression is larger in the left than on the right side; on the left side the base measures three quarters of an inch, the upper margin runs below but parallel with the body of the pubic bone, extending a little higher, and measures one and a half inches in length; the lower border runs backwards, and also measures one and a half inches in length. On the right side the base measures half an inch, and the upper and lower margins measure one and a quarter inches.

The congenital deficiency has evidently been chiefly in the absence of the large segment of the acetabulum, with its projecting lip, formed by the ilium, and with this also a deficiency of the cotyloid ligament.

New acetabulum.—No attempt whatever has been made to form a new acetabulum for the reception of the head of the femur in its displaced position, as in cases of traumatic dislocation; no periosteal thickening or new bone has been thrown out. A circular, smooth, and shallow depression on the ilium, an eighth of an inch in depth, alone indicates the position in which the head of the femur habitually rested, whilst still contained in the capsular ligament. In the present specimen this circular depression on the right side is about the centre of the dorsum ilii, above the sciatic notch, and measures an inch and a half in diameter; in the centre of this depression the ilium is so thinned as to be quite transparent. On the left side the circular depression is just in front of the sciatic notch, an inch and a quarter lower than on the right side, and measures an inch and a quarter in circumference.

Digitized by Google

These appearances are easily explained by the fact that the head of the femur always remains enclosed within the capsular ligament, which therefore intervenes between the two bones, and no periosteal irritation is excited.

THE PELVIC BONES present some other deviations in form, and peculiarities formed in adaptation to the congenital defects in the ileo-femoral articulations, and the displacement of the thigh-bones. The axis of the pelvis is entirely altered, and in the present specimen the anterior superior spinous processes are both tilted forwards and downwards, whilst the sacrum has assumed a horizontal position, thus narrowing the antero-posterior diameter of the pelvis. The lumbar vertebræ, three of which remain in the specimen, are therefore carried forwards, producing a severe degree of lordosis.

The alæ are rather more vertical and less expanded than generally seen in the female pelvis. In this specimen they appear to be smaller than natural, and present angular prominences along the borders of the crests, as well as being otherwise misshapen. This is described by Dr. Carnochan, who also directs attention to the fact that the anterior inferior spinous process on either side is much more prominent than usual, and everted. At p. 192 he observes, "Immediately below the anterior and inferior spinous process of the ilium, on each side, the superficial groove in the healthy bone, over which the conjoined tendons of the psoas magnus and iliacus internus pass, is converted into a *semicircular deep depression* or gutter, giving a more than usual projecting appearance to the anterior inferior spine of the ilium."

In the neighbourhood of this process, in the present specimen, some irregular periosteal outgrowths of bone have been thrown out, and on the right side a remarkable cord-like ossification of fibrous tissue takes the direction of the conjoined tendons. When describing the altered relations and direction of the muscles observed during the dissection, Dr. Carnochan remarks (p. 181), "The psoas magnus, taking its usual origin from the bodies and transverse processes or the last dorsal and lumbar vertebræ, passes downwards, and becomes tendinous about its middle. Where it passes over the brim of the pelvis, and becomes mixed with the iliacus internus, a strong cord-like tendon results from the junction of these two muscles, which, instead of passing downwards and outwards to the usual point of insertion, hooks, as it were, over the margin of the pelvis, below the anterior inferior spinous process of the ilium,

Digitized by Google

where it forms a deep groove; it then takes a course upwards, outwards, and slightly backwards, to the extent of nearly three inches, to join the trochanter minor. It is important to bear in mind the reflected course of the tendon of the psoas magnus, as it accounts anatomically for the curvature forwards of the lumbar region, and also operates in conjunction with the shortened state of the adductors in materially impeding the abduction of the limb." A large irregular bursa is then described in this situation.

At p. 192 Dr. Carnochan also observes, "*The descending rami of the pubes*, and the *ascending rami of the ossa ischia* seem spread laterally, and pass almost transversely outwards, giving to the arch of the pubes more of a semicircular appearance than of an obtuse angle, which is observed in the natural condition of this part of the osseous structure. The long diameter of the foramina obturatoria, instead of running nearly parallel with the body, takes almost a transverse direction."

The SACRUM, as described by Dr. Carnochan (p. 192), is somewhat stunted, showing a greater curvature upon its anterior aspect than in the natural bone, and at its junction with the vertebral column the sacro-iliac angle is seen to be more prominent than usual. In direction also the sacrum is much altered, and during life must have assumed almost a horizontal direction. Dr. Carnochan also observes: "The SPINAL COLUMN in the lower part of the dorsal and lumbar regions presents anteriorly a remarkable convexity, corresponding to the concavity seen in the loins during life." In the specimen three lumbar vertebræ have been preserved, and in addition to Dr. Carnochan's description it may be seen that a decided *lateral curvature* exists in this region, with the concavity towards the right side, and this is to be explained by the head of the femur on the right side having been displaced upwards on the dorsum ilii an inch and a quarter higher than the head of the femur on the left side. The fifth lumbar vertebra has undergone a certain amount of rotation on the first bone of the sacrum towards the left side, so that the longitudinal axis of the sacrum no longer corresponds with that of the lumbar vertebræ. The body of the fifth lumbar vertebra is compressed on the right side, and measures a quarter of an inch less in its vertical diameter.

The oblique articulating process of the fifth lumbar vertebra on the *right side* is much altered in shape, and in the direction of the articulating surface, which is irregularly flattened from above

Digitized by Google

downwards, with periosteal outgrowths at the articular margin; the sacral articulating process has undergone alterations to a corresponding extent. These changes result from the weight of the body having been thrown towards the right side by a mechanical cause, *i. e.* inequality in the height at the ileo-femoral articulation, practically causing a short leg on the right side. The transverse process of the fifth lumbar vertebra on the *right side* has consequently become somewhat depressed and misshapen, being flattened from above downwards and horned upwards, whilst the transverse process on the *left side* is flattened from before backwards, as it naturally should be, and is more horizontal in direction.

These structural changes are of interest in connection with lateral curvature of the spine in the lumbar region, and resemble in a minor degree those described by me in the case of rotation of the lumbar verterbræ, removed from the body of Dr. Gideon Mantell in the year 1852, and figured in the 'Med.-Chir. Trans.,' vol. xxxvii, 1854, and also in my work on lateral curvature, the specimen being now in the Museum of the Royal College of Surgeons.

As a general result of the changes above described in the pelvic bones, which are more altered in shape than in any other specimen I have examined, Dr. Carnochan has described important deviations in the pelvic measurements such as would interfere considerably with parturition. At p. 191 he observes: "In comparing the denuded pelvis with that of a healthy female, the most prominent difference observed, in a practical point of view, is that between the upper and lower straits. In the present pathological specimen the *upper strait* is found to be generally below the usual measurements, both in the transverse and anterior posterior diameters; the latter, however, is proportionably much more contracted than the former. In a dried healthy female pelvis before me, the transverse diameter is five and a quarter inches, while in the morbid specimen it is four and seven eighths (in the dried pelvis I can now only make the measurement four inches and five eighths, W. A); the antero-posterior diameter in the natural specimen is three and seven eighths inches; in the other instance, it is only two inches and three quarters.

The *inferior strait* in the morbid pelvis is still more anomalous. Between the apex of the coccyx and the arch of the pubes the measurement is one and seven eighths inches, against four

Digitized by Google

inches in the healthy pelvis; while the distance between the tuberosities of the ischia, making up as it were for the small antero-posterior diameter, is five and three eighths inches (in the dried specimen I can now make the measurements only four and three quarters inches), the healthy pelvis in this dissection being only four and a quarter inches (*vide* Plate VII).

The pelvic deformities are therefore not only very considerable, but of extreme importance to the welfare of the patient when occurring in the female. *January 29th*, 1889.

---

4. *A case of tubercular teno-synovitis.*

By C. H. Golding-Bird, M.B.

In the next room I have placed under the microscope a section taken from a ganglion of the wrist, and which presents all the characters which are familiar as accompanying, or rather as composing a tuberculous deposit.

There is nothing new or specially interesting in it as a specimen, but the object I have in view in presenting this short note of the case is to elicit the experience of members as to the frequency of tubercular infiltration of the synovial membranes investing tendons, as distinct from arthritic tubercular changes which are daily met with. So like an ordinary case of circumscribed ganglion of the wrist did the present case appear, that I was only led to examine the material removed from it, microscopically, from the fact of its more than usual solidity; and the question that has since then often presented itself before me, is whether many cases now regarded as merely examples of ordinary ganglion, diffuse or circumscribed, may not be of tuberculous nature; and if so, whether they present any pathological peculiarities, other than microscopic, whereby they may be recognised in an early stage; for instance, whether they would be more likely to be multiple than single, or subject to attacks of subacute inflammation, after the fashion of similar deposits, with thickening, in joints. My own case gave me no clue to any special characteristics.

Harriet O—, aged 20, applied at the out-patients', Guy's Hospital,

Digitized by Google

31st October, 1885, for swelling over the right wrist that had been coming for one year. She was herself delicate looking, but had nothing else the matter with her beside the tumour under notice. Her mother was stated to be consumptive. Over the tendon of the right extensor carpi ulnaris, and extending three inches upwards from its insertion, was a swelling precisely like that of ordinary ganglion, except that in two places it projected above the general level of the tumour, in hernia-like fashion, under the integuments; the whole tumour fluctuated, but with gelatinous sensation, and was monocystic. There was no creaking nor sensation of "melon-seeds;" it was painless; the wrist movements normal, and the superjacent structures free from any signs of inflammation. Nothing was observed to suggest its being otherwise than an ordinary, though rather large, synovial ganglion.

Blistering, with subsequent use of Ung. Hydrarg. with pressure, nearly cured her in a fortnight, only slight swelling remaining; but three weeks later, as it had again swelled up, I laid it open under full Listerism. A solid transparent granulation or "pulpy" tissue thickening was found, in which was embedded the tendon of the extensor carpi ulnaris, and out of which the tendon seemed to emerge as the stalk from the head of a bulrush. It was confined to the visceral synovial layer, the parietal being free and easily distinguished, though red and injected. On forcible pressure some synovial fluid escaped by the incision; the solid part was then excised or scraped as thoroughly as possible.

Complete and quick convalescence, without any inflammatory symptoms followed, and the patient seemed cured. But in April of 1886, or four months later, she returned and was readmitted into Guy's Hospital in precisely the same state as at first. The operation was repeated on April 16th, and the scraping, &c., carried out, if possible, more thoroughly than on the first occasion. She made again a rapid recovery. When seen in July, 1886, there was some local thickening, but not having been seen since it is to be hoped the cure is permanent.

The appearance of the tumour was the same on this second occasion, except that now the visceral layer of the sheath was involved; which with the growth was freely cut away with scissors. A few "melon-seeds" were found in the small quantity of synovial fluid that was present.

Macroscopically and microscopically, the tumour had all the

Digitized by Google

appearance of the familiar "pulpy" material found in tuberculous arthritis. Its ultimate structure was of the same retiform character, with foci or nodules dotted all about it, containing in the centre of each a large multinucleated mother-cell.

The appearance here described has been well figured in Mr. Croft's admirable paper upon tubercle in the thirty-second volume of this Society's 'Transactions.' He refers to tubercle of the synovial membranes, but only of those composing joints; nor does he in his exhaustive summary of the literature of the subject of synovial tuberculosis refer at all to that of the teno-synovial membranes; nor do I find a case of tubercular teno-synovitis reported in the last ten years before this Society.

There can, I think, be no reasonable doubt as to the primary character of the malady in the synovial membrane. The wrist-joint was normal; nor did I find anything in the patient to suggest infection from any pre-existing deposit in her body; nor, lastly, was there any history of strain or of injury that would have lowered the vitality of that particular part, and thus account for the selection of it by the bacterium as a specially suitable soil.

If over-use, over-strain, exposure to variations in temperature and to blows are (as does not seem unreasonable) to be regarded as favouring tuberculous selection of the knee-joint, it seems strange that such a tendon-sheath as that of the extensor carpi ulnaris should have been selected; when its near neighbours the extensors of the fingers are exposed infinitely more to all the above-mentioned risks and disabilities.

Volkmann[1] describes tuberculous disease of the tendon synovial-sheaths as being of the diffuse fungous form, or in the form of isolated deposits; to the former of these my case will be seen to belong; but in the absence of any special local symptom or evidence of tuberculous disease elsewhere in the patient, I did not suspect its true—and may in the light of modern knowledge say—malignant character. *February 5th*, 1889.

[1] Rich. Volkmann, "Verhandlungen der deutschen Gesellschaft für Chirurgie," Vierzehnter Congress, 1885, p. 236.

Digitized by Google

5. *Cases of talipes.*

By D'Arcy Power, M.B.

I find on looking through the text-books on orthopædic surgery that comparatively few observers have had opportunities of dissecting feet which during life have been affected with the various forms of talipes. Every observation therefore which can be made in this manner is worth placing on record, so I have taken the opportunity of bringing before you to-night several dissections which I have recently added to the museum of St. Bartholomew's Hospital, and which illustrate various deformities.

For each and all of these specimens I am indebted to the kindness and unwearying energy of my friend, Mr. Bowlby, with whose permission I bring them forward.

It is of interest to observe how completely these preparations bear out the observations made by Messrs. Parker and Shattock in that most valuable, I might even say with our Teutonic neighbours, that epoch-making paper on the pathology and ætiology of club-foot, which appears in the 35th volume of our 'Transactions,' and by Mr. William Adams in vol. iii.

The following specimens exemplify the changes which take place in the bones in cases of talipes varus and equino-varus. The first two preparations are the feet of a newly-born infant at full term which had well-marked talipes varus. The bones of the right foot have been disarticulated to show the modifications which they have undergone as the result of the congenital deformity. The trochlear surface of the astragalus is extended backwards nearly as far as the posterior edge of the lower articular surface, whilst the neck is very greatly lengthened and is directed inwards with an unnatural obliquity. The articular surface of the head is prolonged on its inner side, and instead of being uniformly convex, it is divided into two parts, the planes of which meet at an obtuse angle. The inner and larger corresponds with the scaphoid, whilst the outer portion, which looks forwards, is unopposed owing to the displacement which the bone has undergone. The internal malleolar facet is much smaller than usual. In the calcaneum a considerable portion of the upper posterior facet was uncovered and was marked

Digitized by Google

off from the rest by a low ridge. It articulated with the posterior border of the external malleolus. The inner portion of the posterior facet is continuous with that of the sustentaculum tali. The plane of the cuboidal facet is directed unnaturally inwards and its outer border is less prominent than usual. The posterior articular surface of the scaphoid is very considerably distorted in order to allow it to articulate with the modified articular facet in the astragalus. The remaining bones of the tarsus, and the metatarsal bones are normal.

The second preparation is the left foot from the same fœtus as the preceding. It has not been disarticulated, but, so far as can be seen, the tarsal bones show the same modifications as in the last specimen. The foot is in a condition of extreme talipes varus.

The third and fourth specimens are taken from a somewhat older child than the first two, but from one who was also affected with severe equinus. As in the preceding case, the right foot having been stripped of its muscles and ligaments, has been disarticulated to show that the astragalus, scaphoid, and os calcis have undergone almost the same modifications as have already been described, whilst the rest of the bones are normal. The neck of the astragalus in this case is not so elongated as in the previous example, but it has the same inward direction.

From the left foot of the same child I have stripped off the skin and muscles, whilst I have subsequently divided the internal lateral ligament in its whole extent. The foot, however, still retains its distorted shape, and it cannot be brought back into position without using so much force as to open up the mid-tarsal joint. I am therefore led to suppose with Dr. Bissell (an abstract of whose paper on the anatomy of talipes equino-varus appears in the 'Lancet,' vol. i, 1889, p. 545), that the deformity is due entirely to bone changes, and not, as Messrs. Shattock and Parker believe, to the ligamentous structures which immediately surround the joint. The articular surfaces of the scaphoid and astragalus are united by delicate fibrous bands although the cartilages appear to be perfectly healthy. This fact is of interest, for it seems to show that such adhesions may be formed even in perfectly healthy joints which have been kept at rest, and it may serve to illustrate one of the causes of stiff joint in persons who have been long confined to bed, whilst it emphasises the treatment of such cases.

Digitized by Google

The next specimens were obtained from the body of a child aged 4 weeks who had congenital deformity of both feet associated with a spina bifida. The left foot is affected with talipes varus. When the body was placed in the erect position the inner side of the foot was drawn up so that the whole extent of the border of the fifth metatarsal bone was in contact with the ground. The muscles of the leg appear to be well developed and of a normal size. The tendon of the tibialis anticus is unduly prominent, and is shorter than natural; it raises the anterior annular ligament into a ridge at the point where it passes beneath it. The tendons of the peronei muscles are slightly displaced from their natural groove on the outer surface of the os calcis. The tendon of the extensor proprius pollicis is somewhat more prominent than usual as it passes over the dorsum of the foot, but the extensor communis is natural. I have not dissected out the ligaments of the foot, as I was unable to do so without spoiling the specimen for a museum preparation, but so far as I have been able to do so they agree with the description given by Messrs. Shattock and Parker in the paper to which allusion has already been made. The right foot of the same child is in a condition of slight talipes calcaneus. The foot forms an acute angle with the leg and in the fullest extension cannot be carried beyond a right angle. When the body was placed in a standing position the heel alone came into contact with the ground, the toes being raised and the sole pointing somewhat forwards. There is, however, no flattening of the back of the os calcis, owing no doubt to the fact that the child had never learnt to walk. All the toes are flexed upon themselves at their metatarso-phalangeal joints. On extending the foot the tendons of the tibialis anticus and flexor proprius pollicis became more tense than the tendon of the extensor communis digitorum. The tendo Achillis is well developed, but the gastrocnemius and soleus muscles are so small that the back o the leg has a flattened or almost concave appearance. The peronei muscles and tendons are large. In this, as in the previous case, I did not consider it advisable to dissect out the ligaments.

The last specimen which I shall trouble you with this evening is the right foot and leg from a boy aged 14 years, who had long-standing disease of his right knee with double talipes equino-varus, cavus, and clawed toes. The trouble with his feet was said to have begun when he was six years old. He then went to Charing Cross Hospital, where the plantar fasciæ were divided, the feet being

Digitized by Google

afterwards put up in splints. On admission to St. Bartholomew's Hospital eight years subsequently, both feet were found to be in a condition of talipes cavus, flexed slightly inwards with some equinus. The flexion of both feet inwards at the mid-tarsal joint was accompanied by partial dislocation backwards of all the toes at the metatarso-phalangeal joints. This dislocation is especially marked in the great toes. There was much wasting of the right leg. The right foot and leg affected with talipes equino-varus, cavus, and hammer-toes. The foot is drawn upwards, and is turned somewhat inwards, whilst the toes are bent in a characteristic manner. The extensor muscles appear to be well developed, and have not undergone any degenerative changes. The tendons of the extensor longus digitorum, of the extensor proprius hallucis, and of the tibialis anticus are, however, somewhat tightly stretched, as if these muscles had been shortened. The first phalanx of each toe is drawn towards the dorsum of the foot, whilst the distal phalanges are strongly flexed. In the hallux, as is usual in these cases, the ungual phalanx is alone bent. The tendo Achillis is much shortened, and stands out sharply defined at a considerable distance from the back of the tibia. The heel is dragged upwards by the shortening of the tendo Achillis, so as to draw the foot into a condition of talipes equinus. The plantar fascia was so thin as to be practically absent, but all the muscles, including the interossei, are well developed. The twist of the foot inwards has caused the abductor hallucis to assume a more lateral attachment, so that its main origin is from the external annular ligament, a slip of muscle only passing backwards to the inner tuberosity of the os calcis. This alteration in the axis of the foot leaves a gap between the contiguous sides of the abductor pollicis and the flexor brevis digitorum, in which can be seen the flexor longus digitorum. Microscopical examination of the anterior and posterior tibial nerves failed to show that they had undergone any degenerative changes.

The specimens are preserved in the museum of St. Bartholomew's Hospital, Nos. 3509, *a*, *b*, *c*, *d*, *e*, *f*, and 3514 (*a*).

March 19*th*, 1889.

Digitized by Google

6. *Cast of a child's feet, taken shortly after birth, in a position of talipes varus and valgus.* (*Card specimen.*)

By W. G. SPENCER, M.B.

THE original cast is in the museum of the Surgical Klinik, Halle a. S., given to Mr. Spencer by Professor von Volkmann for the museum of St. Bartholomew's Hospital.

The cast illustrates the origin of both deformities by position. The left foot was dorsal flexed, everted, and placed across the right, so that the left calcaneo-cuboid joint rested on the front surface of the tibia, an inch above the ankle of the right leg. The right foot was in the position of extreme varus, the sole looking upwards, the right heel rested against the plantar surface of the head of the fifth left metatarsal, and the head of the first right metatarsal against the plantar surface of the left internal cuneiform bone.

May 7th, 1889.

---

7. *Disease of shoulder* (*Charcot's joint*). (*Card specimen.*)

By JOHN R. LUNN.

THE right shoulder-joint was removed from the body of a man, aged 75, who was admitted into the New Marylebone Infirmary, Notting Hill, January 10th, 1889. When he was first admitted his right shoulder-joint was much enlarged, there being a tense fluctuating swelling on the front of it. The movement was limited; no grating in the joint was noticed. The acromial end of the clavicle seemed displaced backwards. The patient complained of no tenderness on pressure. The swelling of the shoulder continuing it was aspirated, when ten ounces of darkish fluid was drawn off. The fluid, under the microscope, only showed a few pus-cells.

The patient gradually became worse and died. His temperature upon one or two occasions went up to 101° Fahr. He had no nerve symptoms, nor any signs of cancer. There was no history

Digitized by Google

of gout or cancer in his family. He had always enjoyed good health.

Autopsy.—The right shoulder joint was completely disorganised, and a piece of the head of the humerus was separated from the main shaft, as though there had been an old fracture.

May 21st, 1889.

---

8. *Osteo-porosis of the calvarium, shown in the fragments of a skull found on the Island of Lamoo, Zanzibar, June 8th*, 1888.

By JOHN FREDERICK BRISCOE.

MR. PRESIDENT AND GENTLEMEN,—These parts of a skull I obtained while searching among a number of skeletons on a sandy shore mound, Shella Point, Island of Lamoo, Zanzibar. A battle occurred at this place in 1805 between the natives of the island and those from the adjoining island of Patta. Two thousand people were killed and left on the sand shore, with several animals, such as camels. This, the only pathological example which I observed, shows the greater part of the frontal and parietal bones, and is white and polished like porcelain. Judging from the several diameters of the vault, although, owing to the fragmentary condition of the specimen the measurements are more or less approximate, it would appear that the specimen belonged to a child six years old. The conjugate internal diameter is five and a quarter inches, and the greatest transverse four and a quarter inches. The inner surface of the skull appears to be normal. The outer surface presents large prominences, which are thickest over the frontal and parietal eminences. The surface presents, especially in the parietal area, a spongy, porous appearance; the thickening of the frontal bone is only slightly perceptible in the neighbourhood of the frontal sinuses, which in this case are not developed. Laterally, the bosses on the frontal and parietal eminences are continuous, and along the middle line the elevations upon the parietal bones blend with one another by a thin, shelving margin, while those in the frontal are almost of uniform thickness transversely. This thickening only

Digitized by Google

affects the extreme upper limits of the temporal aspects of the frontal and parietal bones; the orbital plate of the frontal presents a but slightly perceptible deposit upon the inner part of its lower surface.

On a transverse section through one of these prominences it becomes obvious that the elevations are the result of the formation of cancellous bone upon the outer surface of the original skull, the outline of which can be readily defined in different portions of this specimen. The inner compact layer is apparently of normal thickness, but the outer layer is completely absent, so that the more or less horizontally arranged cancelli of the original bone communicate directly with the more or less vertically arranged cancelli of the bone which has been deposited on the outer surface. This difference in the direction of the cancelli is most obvious in the thickest portion of the section, and is hardly distinguishable at the margins of the elevation. There is no indication of the presence of sutures. The greatest thickness of the skull at one of these elevations is five eighths of an inch.

On comparing this specimen with the thickened crania at the Royal College of Surgeons, the Middlesex and Guy's Hospital Museums styled "osteo-porosis, osteitis deformans, and rachitic," it is very dissimilar. The mesh of the cancellous tissue of this specimen is larger and more defined, differing from the usual osteoporetic skulls, and there is a want of uniformity in the calvarium different from osteitis deformans. The remarkable appearance of the cancellous tissue of these fragments of a skull makes this specimen almost as unique as that enormously thickened dense skull in the Middlesex Hospital Museum. I have been unable to find a similar specimen in the museums to compare my specimen with; it appears to me to be quite unlike the usual pathological calvaria. If the subject to which this skull belonged was affected with congenital syphilis, it is of interest as showing that the disease existed in this part of the world prior to this century; should it be rachitic it is equally interesting, since I believe that this disease does not exist among savage tribes in their native state. It appears to me that much uncertainty exists as to what bone changes are syphilitic in origin and what rachitic. No doubt some frictional changes have occurred in this specimen owing to years of exposure to a shifting sand-hill; certainly its bleached condition is remarkable.

Digitized by Google

The littoral of Zanzibar was conquered in 1784, and a Sultan of Oman of Arabia came over. Syphilis was probably then introduced. The Persian Gulf and the Gulf of Oman are adjoining. The former was once a great slave-trading coast, and it is interesting to know that Muscat, the chief town of Oman, has held little intercourse with Europe, chiefly trading with India, Batavia, the Persian Gulf, and Yemen. *March 5th*, 1889.

Report of the Morbid Growths Committee on Mr. John Frederick Briscoe's specimen of osteo-porosis.—Your committee is unanimously of opinion that the changes in the child's skull exhibited by Mr. Briscoe are the result of an extreme degree of rickets, and corresponds with the form which is relatively common in animals.

THOS. BARLOW.
FREDERIC S. EVE.
SAMUEL G. SHATTOCK.
June 14th, 1889. J. BLAND SUTTON.

---

9. *The structure of the eburnated substance in two specimens of advanced osteo-arthritis.*

By SAMUEL G. SHATTOCK.

IT is unnecessary to define what is meant by the eburnated or porcelaneous surface presented by the articular ends of the bones in joints affected with osteo-arthritis. But doubt is often expressed in regard to the true nature of the dense substance of which the surface is thus highly polished.[1]

Is it true bone, or is it a calcified substance in which the original osseous trebeculæ are embedded, a substance resulting from calcification of the medulla within the cancellous spaces, and akin to the so-named horny dentine produced by the filliug-in of the dentinal tubuli with calcareous material at the seat of lesions involving the dentine?

The cancellated tissue of the articular end of a long bone is, as

[1] It is hardly necessary to say that this remarkable appearance obtains only in the macerated and dried bone; the whiteness is of course absent, though the polish is present in the recent state.

Digitized by Google

well known, closed in beneath the cartilage by a thin layer of compact substance less than half a millimetre in thickness, and this, although once assumed to be true bone, is now shown from more minute histological examination to be constituted superficially by calcified cartilage, and more deeply by a bony lamella of varying thickness continuous with the osseous trebeculæ beneath. This fact may be kept in mind for two reasons:

Firstly, because it renders feasible the view that the eburnated tissue closing the articular surface in osteo-arthritis *might* result from a process of calcification as distinguished from that of ossification.

Secondly, because after the fibrillation and removal of the cartilage in such joints this original layer, so exposed, is the first to present the polished porcelaneous character, and the eburnated substance would not in fact at this stage be wholly osseous, but to some extent constituted by the original stratum of calcified cartilage.

In order to dispose of the latter possibility, I have selected for examination two specimens in which the changes had progressed so deeply that none whatever of the original substance could be concerned.

One of the microscopic sections is from the patellar surface of a femur worn into deep grooves; the other is from the upper end of a femur of which the entire head has been destroyed, the articulating surface being constituted by the stump of the neck and the broad rim of new bone produced around it (D 100^4, D 63 St. Thomas's Hospital Museum). In both of these specimens (and the fact is true generally) the eburnated substance extends to no great depth. It forms a layer of fairly uniform thickness, a millimetre in one, a millimetre and a half in the other, closing in the cancellated tissue, and where the outer surface is grooved, the deep presents reversed irregularities.

The histology in both preparations is the same.

The limiting substance is composed up to the very surface in process of erosion of extremely compact, true osseous tissue. The channels of the Haversian systems are either small and regularly defined, or wider and festooned by absorption, and several of each kind open on the eroded surface. The lacunæ are of normal form, are arranged conformably with the vascular spaces, and furnished with typical canalicular systems. There is no disposition of the

Digitized by Google

bone after the manner of circumferential laminæ. The Haversian systems are worn away exactly as they happen to lie, and it is noteworthy that in many places the canaliculi [filled with air and black as viewed by transmitted light] can be traced opening on the very surface undergoing erosion, in which process, therefore, whatsoever of the soft structures in the bone is exposed, is worn away after the same manner as are interarticular ligaments or fibro-cartilages in the same disease.

In regard to the technique of preparation, a thin slice of the bone was ground smooth on a hone, brushed in spirit, dried, and then cemented to a glass slide by melting a small piece of solid Canada balsam on the latter. The slice was then ground down from the opposite aspect till of the required thinness. It was then detached by immersing the slide in chloroform, pencilled, and allowed to dry. Some of the sections were finally mounted in the ordinary mounting fluid, others in solid balsam liquefied by heating, the advantage of the latter plan (as is well known to histologists) being that the air is not removed from the lacunæ and canaliculi, which are mapped out as black objects when the section is viewed with transmitted light. *April 16th*, 1889.

---

10. *Pedunculated chondroma removed from the knee-joint.* (*Card specimen.*)

Exhibited by SAMUEL G. SHATTOCK.

[With Plates XXII and XXIII.]

A FLATTENED pedunculated chondroma, 2·5 cm. × 2 cm. in its chief diameters, and 1 cm. in thickness, which was tethered by a stout pedicle of fibrous tissue to the capsule of the knee-joint. The pedicle, which is connected with the body near to one of its ends, is 1·3 cm. in length, and ·5 cm. in thickness. The body is throughout of homogeneous cartilage, invested with a thin and inseparable layer of fibrous tissue. On one aspect it is convex, on the opposite it is, centrally, concave (as is usually the case), and its surface is everywhere smooth and polished.

Histologically, the growth is composed of pure cartilage,—the

Digitized by Google

Digitized by Google

Fig. 1.

Fig. 3.

Fig. 2.

Fig. 4.

S. G. Shattock del.

F. Huth, Lith.r Edin.r

Digitized by Google

EXPLANATION OF PLATE XXII.

Illustrating Mr. Shattock's paper on Pedunculated Chondroma. (Page 256.)

FIGS. 1 and 2.—Vertical sections of patella from an osteo-arthritic joint showing epi-articular ossifying chondrosis. (Museum of St. Thomas's.)

FIG. 3.—Section through one of the femoral condyles from the same joint, showing (*a*) epi-articular, (*b*) peri-articular, (*c*) and subsynovial ossifying cartilaginous formations.

FIG. 4.—Lower end of right femur, showing a nearly detached body lying in the substance of the articular cartilage. (Museum of St. Thomas's.)

Digitized by Google

Digitized by Google

Digitized by Google

Fig. 1.

Fig. 4.

Fig. 2.

Fig. 3.

Fig. 5.

S. G. Shattock del.

F. Huth, Lith.r Edin.r

Digitized by Google

EXPLANATION OF PLATE XXIII.

Illustrating Mr. Shattock's paper on Pedunculated Chondroma. (Page 256.)

FIG. 1.—Section of head of femur, showing peripheral ecchondrosis. (Museum, College of Surgeons.)

FIGS. 2 and 3.—Sections of head of femur, showing a considerable involvement of the original cartilage in the new formation, as seen by the traceability of the deep outline of the articular cartilage and articular lamina of the bone.

FIG. 4.—Part of the lower end of humerus, viewed from behind, tipped with new bone and showing a nodular formation in the tissues around in opposition with the outgrowths from the bone.

FIG. 5.—Piece of articular cartilage with a scale of subjacent bone, which formed a loose body, removed from the knee-joint by Sir John Simon.

Digitized by Google

Digitized by Google

matrix finely granular, the cells in fusiform groups, the groups, however, devoid of any orderly disposition. Towards the surface the matrix passes by fibrillation, more or less concentric, into investing fibrous tissue, the groups of cartilage corpuscles being replaced by elongated connective-tissue cells. At the very surface the fibrous tissue reaches a high degree of density, its fibres maintaining a concentric arrangement, and being well provided with much elongated corpuscles.

History.—The specimen was removed by Mr. Clutton, October 27th, 1888, from the knee of a man who had fallen from a horse three years previously. Eighteen months after the fall there appeared symptoms such as are usually thought to be characteristic of displacement of the external semilunar cartilage. Before operation a lump could be felt at the back and outer side of the joint. A vertical incision was first made over the external semilunar cartilage, under the impression that the body behind the knee had not caused the symptoms of which the patient complained. The semilunar cartilage being found normal, a finger was introduced into the joint and the body behind found to be movable, and capable of being brought by traction to the front of the joint. An incision was made through the skin over the body behind the knee during this proceeding, but it was so readily extruded through the opening on the outer side that its pedicle, which was apparently attached to the capsule, was easily divided with a pair of scissors. The joint suppurated, but the patient recovered with a useful though somewhat stiff knee. He has since developed signs of pulmonary phthisis.

Remarks.—This specimen is a typical one of the ordinary loose or (as in this case) pedunculated body which occurs in the joints; commonly, however, the cartilage is more or less calcified, or has undergone some amount of ossification. The otherwise healthy condition of the joint is noteworthy; and when the loose body is single, this is often the case. Such bodies as that under notice are best regarded as tumour formations and classified as chondromata. About their mode of origin in Rainey's processes of the synovial fringes there is no dispute. The specimen exhibited was still attached by its stalk at the time of operation. And in another specimen (D 104^3, Museum St. Thomas's Hosp.) removed by Mr. Mason from the knee-joint of a young man, aged 16, although the body was free, the ruptured stalk is still attached to it. The patient

Digitized by Google

in this case struck the inner side of the right knee against the sharp point of a stone buttress whilst playing football; acute synovitis followed, and from this the history of the symptoms of loose body some months later dated. This visible demonstration of their mode of origin, however, is not common. It is a noteworthy fact that whilst the bodies found in the joints are of cartilage,[1] no such tissue occurs in those from synovial sheaths and bursæ. There is one exception to the latter statement, but in reality it is within the rule. In bursæ, in the neighbourhood of some of the joints, loose cartilages have at times been found; and I have seen them in synovial herniæ in osteo-arthritis.

The explanation of course is that, in the case of the joints, the secondary processes of Rainey normally contain the elements of cartilage. But what is the explanation of this last fact? There are in the early stage of development no articular cavities between the cartilaginous matrices of the future bones; the cavities are formed subsequently by the disappearance of the intervening mesoblastic tissue. And apart from embryological data, the formation of articular cavities by secondary softening is observable in later life, *e. g.* in the interpubic fibro-cartilage. In the cartilage, again, of the first rib, a diathrodial joint forms in those cases where the cartilage becomes ensheathed in bone, with the result of preserving the capacity of the sternal movement in respiration. The adventitious joint results from fibrous metaplasia of the cartilage and secondary softening of the new tissue at a spot about half an inch from the outer extremity of the cartilage.[2]

The presence, then, of cartilage elements in the synovial fringes of the joints is, I submit, to be explained by regarding those elements as relics of the cartilaginous basis about the primitive sites of joint-formation; and as the same mode of formation does not obtain in the case of ordinary bursæ and tendon sheaths, so there are no such residues from which chondromata may arise. Although intra-articular loose bodies of cartilage, calcified or ossified, commonly arise as pedunculated chondromata, there are other more obscure modes of origin about which there is still

[1] For an account of some of the rarer forms of bodies found in joints, see a paper by Mr. Bowlby and another by myself in the preceding vol. of the Society's 'Transactions.'

[2] The process has been described by Mr. Arbuthnot Lane, 'Path. Soc. Trans.,' vol. xxxvii, p. 393; and it is not difficult to confirm.

Digitized by Google

much to be cleared up. That loose bodies ever arise by the immediate traumatic detachment of portion of a normal articular surface has been doubted. There are amongst the different specimens in London museums and elsewhere, as Mr. Marsh has pointed out ('Brit. Med. Journ.,' April 14th, 1888), a few in which the loose body is, either certainly or probably, a fragment from an articular surface; but I agree with him in thinking that of these there is only one to which an origin by immediate traumatic detachment can be surely assigned. The only specimen extant which presents appearances such as might be expected under these circumstances is one in the museum of St. Thomas's Hospital (D 110[1]), which was removed by Sir John Simon in 1864 ('Path. Soc. Trans.,' vol. xv) from the knee-joint of a young man who, in falling, had wrenched his knee. He came into the hospital for some inconsiderable synovitis which followed the accident, and while under treatment was found to have a loose body in the joint.

As soon as the acute symptoms had subsided, about three weeks after the injury, Sir John Simon removed the loose body, and the patient recovered without interruption. The above is Mr. Marsh's extract of the original account. The specimen is a quadrilateral piece of cartilage 1 cm. × ·6 cm., with a subjacent scale of well-formed bone. The cartilage measures, where thickest, ·3 cm., and the subjacent bone, along its thickest edge, measures the same. On three of the four borders the cartilage is sharply split and vertically striated in a way such as normal articular cartilage would be; along the fourth the smooth surface of the cartilage is continued to the thin edge of the subjacent bone. At Mr. Marsh's request I made a vertical microscopic section of the cartilage, and it shows nothing incompatible with this origin. The matrix is throughout homogeneous, and its cells are arranged in groups set vertically in the deeper, and horizontally in the superficial parts. It is quite conceivable that the prominent inner tubercle of the tibial spine might be broken off by a lateral jar against the outer border of the inner condyle of the femur, or that a limited piece of this border might be detached by impact against the tubercle. The body under consideration does not correspond in appearance with a fractured tubercle, but it might be a detachment from the border of the articular surface of either the femur or the tibia.

In extreme flexion of the knee the inner border of the patella comes to be in contact with the outer border of the internal

Digitized by Google

condyle, the highest of the three external facets lying at the same time upon the outer condyle. The central portion of the patella in this position is unsupported by the trochlea, and under these circumstances, again, it is conceivable that direct violence might lead to the detachment of the marginal part of either bone.

The other cases cited by Mr. Marsh are ones in which the detachment of portions of the articular surface has been effected after necrosis. Some of these (such as Teale's) are quite clear, some dubious, others (*e. g.* 647 Roy. Col. of Surg. Museum, 722 St. Bart. Hosp. Museum) can hardly be regarded as portions of normal articular surfaces for the reason that the cartilage presents a smoothly rounded edge which overhangs the bone, and is even continued for some short way beneath it. The precise mode of origin of such bodies (of which other examples might be added) has still to be cleared up. I could refer to different preparations as offering some facts bearing on this, but to none conclusively showing what the real nature of bodies of this kind is before they are found loose. Of methods in which loose bodies of cartilage may arise, there is, however, I think, another illustrated by a specimen which Mr. Edmunds showed at the Society (vol. xxxvii), and which is now in the museum of St. Thomas's Hospital (D 104). As no explanation has yet been given of this specimen I venture to offer one, especially as Professor Humphry, who has an explanation for most things, was quite at a loss as to how to deal with this.

In this specimen there is in the inner condyle of each femur an almost loose body, symmetrical in size, form, and position. To take the right femur: in the proper articular surface of the inner condyle to the front and inner side of the intercondylar notch, there is embedded an oval body 1 cm. in chief diameter, ·6 cm. in thickness, attached by its inner and anterior borders, almost wholly of osseous or calcareous substance, and considerably surpassing in thickness the articular cartilage around. There is a surrounding zone of fibrous metaplasia about ·5 cm. in extent, and a projecting outgrowth from the edge of the condyle beyond. On raising the body from its bed, the opposed surfaces were found, on microscopic section, to be composed of fibro-cartilage. In the left femur there are symmetrical changes, but there is in addition a body attached by a broad, short peduncle to the margin of the intercondylar notch and the crucial ligament. There is the ordinary osteo-arthritic lipping, and there were free bodies in both joints. Now,

Digitized by Google

these cannot be regarded as portions detached by quiet necrosis for the following reasons:—Each body is of a regularly oval shape, its thickness considerably exceeds that of the normal articular cartilage, it is calcified or ossified almost throughout, the pit in which it rests is, like the under surface of the loosened body, invested with fibro-cartilage. I submit, then, that these bodies are of the same essential nature as the outgrowths from articular margins, but that in place of growing exogenously they have arisen in the substance of the cartilage covering the normal bone. If we conceive a localised hyperplasia in the substance of the articular cartilage, a central calcification or ossification of the new formation, and a differentiation, by fibrous metaplasia, of such an enchondrosis from the surrounding cartilage, we should have, I think, a fairly satisfactory explanation of this curious specimen. That articular cartilage may be involved in the production of new tissue not merely at its marginal, but in its more central parts, is a fact not generally known. As an instance of outgrowth as purely marginal as may be, one might select the osteo-arthritic head of the femur, 1911 Roy. Coll. of Surg. Museum. But in certain cases the growth extends for some distance into the original substance of the cartilage, as was long ago pointed out by Mr. William Adams ('Path. Soc. Trans.,' vol. ii).

Mr. Adams's account and figures are from a specimen (D 59) in the museum of St. Thomas's Hospital. It is the lipped and partially eburnated upper end of a femur, and the section shows quite plainly the more superficial and the deepest part of the original articular cartilage continued over and beneath the osseous outgrowth for a distance of about 2 cm.

In other sections from the same specimen, as Mr. Adams pointed out, although the cartilage is not traceable on the deep aspect of the new bone, the original limitary line of the head is still clear, but the new is fused with the original bone.

In macerated specimens of osteo-arthritic joints it may not uncommonly be observed that the marginal outgrowths are continued for varying distances over the articular surfaces, so as to upraise their original contour. Such specimens as the preceding give the explanation of this.

As examples of extreme deformity of articular surface arising from involvement of the more central parts of the cartilage in the new formation, I may adduce No. 1923 Roy. Coll. Surg. Mus., and

Digitized by Google

D 97 St. Thomas's Hosp. Mus., both specimens of knee-joints, and remarkably alike. To take the latter,—which is also briefly alluded to by Mr. Adams,—there are the usual changes of advanced osteo-arthritis and the articular surfaces of the patella, of the femoral trochlea, and inner condyle are not, like other parts, worn and eburnated, but are raised up in numerous rounded and differently sized eminences, so as to present a coarse warty character. Now, the interesting thing shown by sections carried through these parts is that the normal surfaces of the original bone and the articular cartilage upon it are quite plain beneath the new formation of ossifying cartilage which hides them.

In the patella the osseous tissue in the sessile projections is seen in certain sections to be connected with the main substance of the bone.

These epi-articular ecchondroses are associated with the ordinary marginal outgrowths. But the osseous tissue in such formations is not always continued into the subjacent bone. In the same specimen, for instance, there are among the nodular projections over the border of the trochlea some nearly half an inch in diameter, which, though sessile, admit of some degree of movement, and which a vertical section shows to overlie the original cartilage. It is noteworthy that the epi-articular growths, though closely connected by fibrous tissue to, are in places sharply demarcated from, the articular cartilage they cover. This seems to show that they are to some extent outgrowths which overlap and have become adherent to the subjacent surface; their seat of origin from the cartilage may be, probably, either marginal or central; and more than this, it is not unlikely that independent subsynovial formations growing in the immediate vicinity of the articular margin might come to overlap and adhere to the surface of the articular cartilage in unused portions of a joint; that such subsynovial formations may abut against the proper ecchondrosial outgrowths in osteo-arthritic joints, many specimens show. No. 1914 Mus. Coll. Surg., *e. g.*, shows a row of additamentary processes along the inner border of the sigmoid cavity of the ulna, hinged on by connective tissue, and others abutting upon the new bone formed about the capitellum. *May 7th*, 1889.

Digitized by Google

11. *Osteoma of the metacarpal bone.*

By J. Hutchinson, jun.

The most interesting problem with regard to tumours is perhaps their causation; and it is as a contribution to this subject that the present specimen is brought forward. The tumour was an oval one, growing from nearly the whole length of the second right metacarpal bone, measuring two inches long by one and a half across. It filled the second interosseous space, and had flattened the middle metacarpal bone in a remarkable manner by its pressure without being adherent to it. It was smooth and rounded on

Woodcut 3.

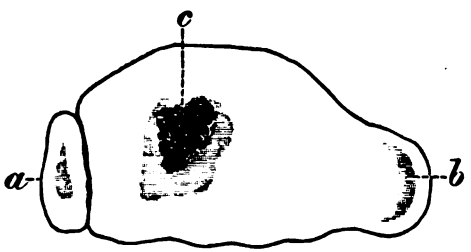

Transverse section of the tumour. *a*. Third metacarpal bone. *b*. Margin of the cancellous bone. *c*. Necrotic area.

its surface, and on section was seen to consist of cancellous bone continuous with that of the shaft of the index metacarpal. Almost in its centre was an area of bone of granular appearance, of quite a different colour (brownish-grey) to the rest of the tumour, lying in a bed of soft granulation tissue. In other words, it was evident that the centre of the osteoma was partially necrosed, although there was no trace of suppuration. The area alluded to measured about one centimetre in diameter. The specimen was obtained from an elderly man, who had no other osseous tumours; and the history is that he had sustained an injury to the hand many years before, after which the growth had formed. No further details could be obtained, and of course such a history must be accepted with reserve. But it seems not improbable that the injury had set up some ostitis of a very chronic nature, that a small central or sub-periosteal sequestrum had been formed, and that the irrita-

Digitized by Google

tion of this had led to the gradual development of a dense wall of bone around it. It is now admitted that such a process ("quie necrosis," a necrosis without suppuration) may lead to the formation of a large amount of encasing bone, as shown in the cases recorded by Sir James Paget and Mr. Morrant Baker. I have known of a case in which amputation at the hip was proposed for an apparent tumour of the upper end of the femur. An exploratory incision was made into the swelling, and a sequestrum removed from the great trochanter, which had become greatly enlarged.

In one of Mr. Baker's cases—quiet necrosis of the shaft of the femur—amputation was actually performed in the belief that there was a new growth.

Another theory as to the present specimen might be that the tumour was really an ossified enchondroma, the centre of which had undergone necrosis. Against this are the facts that it was a solitary tumour (enchondromata of the fingers being nearly always multiple), and that necrosis of the centre of a bony tumour is not, so far as I am aware, a recognised pathological occurrence. On the whole the view advanced would appear to be the most probable one. *May 7th*, 1889.

---

12. *Synostosis of upper cervical vertebræ.* (*Card specimen.*)

By L. A. Dunn.

The specimen shows the whole of the cervical spinal column obtained from a subject in the dissecting room at Guy's Hospital. It consists of five segments only. The upper segment represents the first three cervical vertebræ fused together. The anterior arch of the atlas and the bodies of the next two vertebræ are so welded together as to present a slightly undulating but otherwise uniform surface. So, too, with the posterior arches; but here the outline of the laminæ and the spinous processes of the second and third are still plainly visible. On the left side, which is about double the height of the right, are seen two well-formed transverse processes, whilst on the right side only one exists.

Digitized by Google

The spinal canal is formed by a solid ring of bone, broken only on the left side by the intervertebral notch above and below, and in between by two foramina, evidently for the passage of the second and third cervical nerves, whilst on the right, in addition to the two intervertebral notches (the lower of which is very large, and when articulated with the vertebra next below forms a foramen sufficiently capacious to admit of the little finger), there is a tiny foramen capable only of admitting a small bristle. The upper articular facets are flattened, so that when articulated with the correspondingly flattened occipital condyles they form arthrodial joints. Between the anterior extremities of these facets is a small pealike mass of bone, the remains of the odontoid process. The lower articular facets are fairly normal, except that that on the left side is markedly expanded and surrounded by a thickened upturned bony margin.

The remaining segments are also fairly normal, except as regards the articular processes of the third and fourth vertebræ on the left side. These resemble the one just mentioned, but are more expanded and thinned (so much so that one is perforated), and the bony margin is more thick and irregular.

The fusion of the upper three vertebræ, I take it, results from disease in early life, whilst the changes in the articular processes are probably due to pressure produced by the altered position of the head. However, no history of the case could be obtained.

January 13*th*, 1889.

---

13. *Epiphysitis of the upper extremity of the humerus.* (*Card specimen.*)

By L. A. Dunn.

The specimen represents the upper extremity of the right humerus removed *post-mortem* from an infant aged 8 months.

The cartilaginous upper extremity is quite loose, and can be moved freely upon the shaft of the bone. At the line of separation there is a quantity of pulpy material (reddish yellow in colour before the addition of spirit), which extends upwards at

Digitized by Google

one point into the cartilage so far as to reach the ossific centre, which is lying loosened in its cartilaginous bed. The upper end of the shaft is rough, and covered by pulpy material.

The joint itself was healthy, except that it contained an excess of clear synovial fluid.

History.—The infant, which was the subject of congenital syphilis, was attacked three weeks before I saw it with pain and swelling of the right shoulder. There was no history of injury.

When seen at the Shadwell Hospital the right upper extremity hung helplessly at the side; the right shoulder was much swollen, tense, and glazed, with enlargement of the superficial veins, but no redness. There was marked tenderness on palpation. No other epiphysis was affected. The child was treated with mercury, but died at its home in convulsions twelve days later.

The shoulder was the only part examined, and this with considerable difficulty. *February 5th*, 1889.

---

14. *Syphilitic disease of the knee-joint and kidneys.*

By JONATHAN HUTCHINSON, jun.

[With Plate XXIV.]

THE right knee, which appeared to be the only joint affected in the body, was slightly flexed (about 10°), and the leg very considerably rotated outwards, and somewhat displaced backwards, so that the external condyle projected prominently in front of the outer tuberosity of the tibia below it. Slight flexion was possible in the joint, the patella could still be moved, and rotation was also permitted to a small extent, but extensive fibrous adhesions on the inner side of the joint and the extraordinary alterations in the shape of the bone surfaces prevented any one movement being performed to nearly the normal extent.

The patella was partially dislocated outwards and articulated by a nearly vertical groove with a prominent ridge on the outer condyle. It was very greatly thickened by deposit of new bone on its posterior surface, so as to measure at the lower extremity (which is of course usually the thinnest) an inch in depth. The liga-

Digitized by Google

Digitized by Google

1.

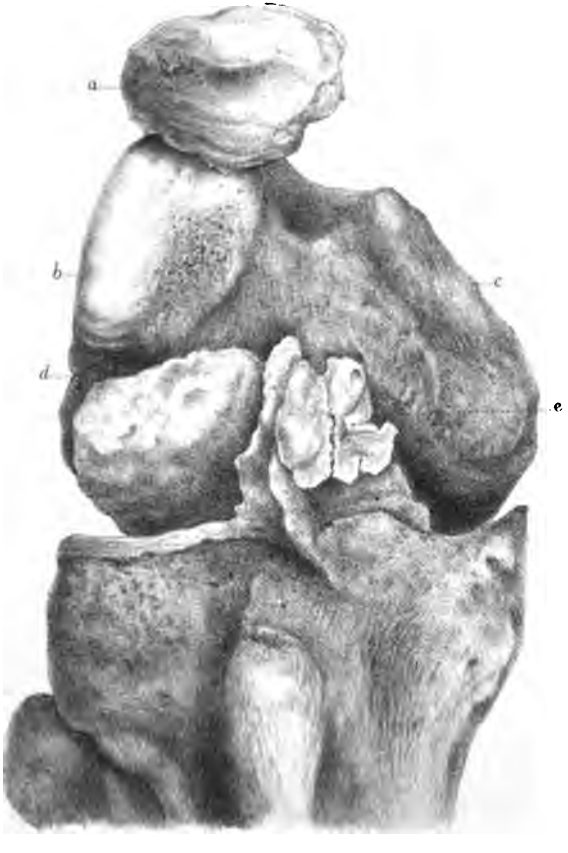

2.

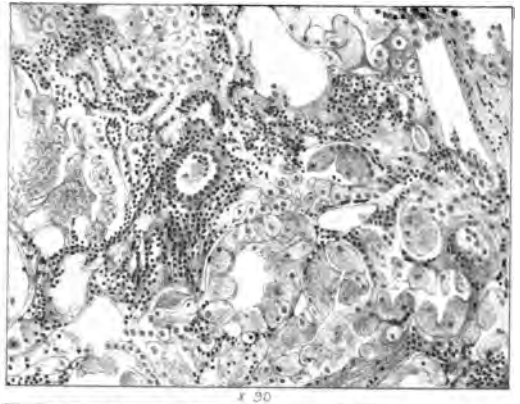

3.

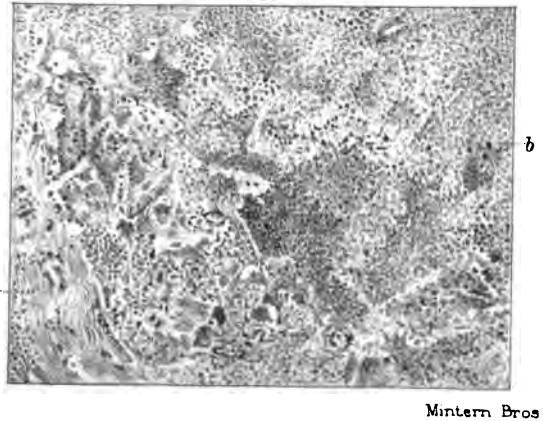

Mintern Bros. lith.

Digitized by Google

EXPLANATION OF PLATE XXIV.

To illustrate Mr. Jonathan Hutchinson, jun.'s paper on Syphilitic Disease of the Knee. (Page 266.)

a. Lower boder of patella, much thickened.
b. Ridge on external condyle, on which the patella moved.
c. Internal condyle, almost deprived of cartilage.
d. Deep groove between surfaces for patella and tibia.
e. Gumma in ligamentum mucosum.

Digitized by Google

Digitized by Google

mentum patellæ and the quadriceps presented nothing unusual, except that the muscle was somewhat atrophied. The normal articular surface on the front of the femur for the patella was represented by a deep groove wholly destitute of cartilage. The internal condyle, considerably altered in shape, was connected with the corresponding facette of the tibia by numerous bands of adhesion, in which was merged the internal semilunar cartilage. The external facette on the tibia was uneven on the surface from irregular thickening of cartilage and bone, and a few scattered fibrous bands and pedunculated processes were present, especially in connection with the external semilunar cartilage, which was ragged at its margin. The corresponding surface on the femur was separated from the ridge for the patella by a deep groove, in which lay a delicate fibrous band, possibly the remains of extensive granulation tissue. It might be suggested, however, that this deep groove was produced by the pressure, when the bone was in an inflamed and softened condition, of the lower border of the patella, which, as already mentioned, was greatly thickened. Of course, normally, the patella has very little lateral movement, but supposing that the dislocation outwards in this case took place slowly, it is possible to conceive that in its gradual passage it led to the formation of the groove. The latter has lost its cartilage, the bone beneath being quite smooth, and there is certainly great thickening of the cartilage, both above and behind the groove, *i. e.* on the surfaces for the patella and external tuberosity of the tibia. The disease was essentially one of the joint, and greatly altered as are the bone surfaces taking part in the articulation, neither femur nor tibia appear to be enlarged or otherwise diseased as soon as the limits of the joint are passed. At first sight the head of the fibula appears to be abnormally wide, measuring just an inch across; but on vertical section the bone seems quite healthy, and it is doubtful whether the thickening is more than simple hypertrophy, since few bones are more variable in size and configuration than the fibula. The tibio-fibular articulation, when opened, shows a thin partial system, no doubt a rudimentary interarticular fibro-cartilage, such as is seen sometimes in the acromio-clavicular and other ginglymoid joints.

It is extremely difficult to give in a description a correct idea of the morbid changes present, and it may be well to recapitulate the chief features of this remarkable joint. There has evidently been some slow inflammatory process which has led in part to absorption

Digitized by Google

of the cartilage without eburnation of the bone (over a large area of both condyles of the femur), in part to thickening of this layer with deposit of new bone (over both tuberosities of the tibia, the patella, and the margin of the external condyle). The synovial membrane was fringed at parts, but was comparatively slightly affected. In fact the disease would appear to be one chiefly of the cartilages of the joint, and in this respect, as in the curious grooving and outgrowths of the surface, to resemble chronic rheumatic arthritis, with the addition of firm fibrous adhesions between the inner condyle and tuberosity. But no one would, I think, consider the case to be one of chronic rheumatic arthritis for the following reasons:

1. There is no eburnation of bone, and no true "lipping" of the condyles.

2. The wearing away of bone at one part and the outgrowths of bone and cartilage at another are more extensive than is seen in any but very severe cases of this disease.

3. The patient was quite a young man, and the right knee was the only joint affected in the body.

I have reserved to this point notice of a feature which, to my mind, gives the clue to the real nature of the case. The ligamentum mucosum, although thickened and continuous with the adhesions on the inner side of the joint, did not appear to be materially diseased until a section of it was made. Then a firm, leathery, yellow mass, oval in shape and nearly an inch across, was exposed. This mass, which was well defined at its margin from the surrounding fat, was exactly like a gumma in its quiescent stage, and such the microscope indicated it to be. Surrounded by tough fibrous tissue the whole of it was composed of ill-defined cells, most of which were so degenerated that their outlines could hardly be made out. Interspersed were bands of connective tissue and a few remains of small vessels. I obtained sections of the whole mass, and in no part was there the slightest suggestion of tubercle. The case would then seem to be one of very chronic syphilitic arthritis, in which the changes were almost confined to the cartilaginous surface and subjacent bone.

But little, if any, attention has been called in this country to this form of syphilitic joint disease, although the formation of periarticular nodes and gummata is well recognised. Mr. Howard Marsh's work on 'Diseases of the Joints' contains several ex-

Digitized by Google

amples of the latter form of tertiary synovitis. In these 'Transactions' for 1887, page 288, my father and I recorded an example of syphilitic node of one condyle of the femur (under the perhaps unfortunate title of "? Sarcoma of the Knee-joint").

M. Lancereaux has given in detail the description of another case, in which it is interesting to observe that the chief feature was a gumma situated in the ligamentum mucosum, exactly as in the present case. Both knee-joints were diseased, and in both a gumma was found in this situation.

We have now to note what other evidence of syphilis existed in our case. The patient was a young Swedish sailor, aged 23, who came under care for disease of the rectum—a large firm stricture, accompanied by considerable ulceration. It was certainly not a cancerous growth, and probably no one would hesitate to admit it as being of tertiary syphilitic origin. There were, however, no gummata in the liver or other viscera, but both kidneys were greatly enlarged, firm, and paler than normal. Microscopical examination showed them to be affected with diffused cellular intertubular deposit; and the Malpighian bodies were degenerated in varying degrees. The patches of round-cell growth were scattered throughout the kidney, and in some places were in process of forming fibrous tissue. The tubules themselves appeared to be only secondarily affected. It seems most probable that this diffuse interstitial nephritis was also of syphilitic origin. Although rare, it is a well-recognised form of nephritis; and Mr. Barthélemy has collected a number of cases of syphilitic disease of the kidney in the 'Bulletin Médical' for May 22nd and 29th, 1887. My friend Dr. Perry suggests that in the present case there may have been amyloid degeneration present; unfortunately I cannot speak positively on this point. The patient was a Norwegian sailor who could speak hardly any English, and hence a history as to secondary syphilis could not be obtained from him.

To answer those who would see in this specimen only an example of chronic rheumatic arthritis, we may observe that Professor Virchow four years ago pointed out how closely some cases of syphilitic disease of joints imitate the former disease; that a form of chondritis, due to syphilis, may develop, leading to the substitution of fibrous tissue for the articular cartilage, and to various changes in the joint surfaces. Virchow's observations, which appear to be the first made upon the subject, are recorded in the 'Berliner

Digitized by Google

klinische Wochenschrift,' August 18th, 1884. So far as I know, the present case is the first brought forward in this country which confirms his view, which is plainly of importance both from a pathological and clinical standpoint.

M. Voisin ('Des Arthropathies Syphilitiques,' p. 89) describes a case in which both knees were affected with syphilitic disease; they had been indolently swollen previously, and then presented enlargement of the patellæ, bony outgrowths of one condyle, and what seemed to be small gummatous swellings behind the ligamentum patellæ of each side. This writer records no less than ten cases of tertiary joint disease, but in none was the diagnosis verified by dissection, and in fact the *post-mortem* evidence is somewhat scanty. The specimen from my case is in the museum of the Royal College of Surgeons. *October 6th*, 1888.

---

15. *Syphilitic osteitis of tibiæ.* (*Card specimen.*)

By G. N. Pitt, M.D.

Walter G—, aged 23, cabdriver, admitted October 24th, 1888, under Mr. Lucas. For two weeks a painful swelling had been noticed behind the left malleolus; there was no fluid in the joint. This swelling was incised; no pus was let out, but the bone was found to be bare.

October 29th.—A swelling appeared over left shoulder.

November 1st.—Pain and swelling in the left knee, right carpo-metacarpal joints, &c.; temperature high, 100°—103°. The diagnosis at first pyæmia, was afterwards modified to acute rheumatism, and he was transferred to Dr. Goodhart on November 13th. He had taken quinine, and then salicylic acid, which produced delirium, and was at this date free from pains, and his ankle was granulating up. Dr. Goodhart considered the patient to be suffering from syphilitic osteitis of tibia with phthisis, of which there were well-marked physical signs.

The patient had extreme tenderness of his bones. He became delirious, had severe diarrhœa, and died on November 21st. No tubercular bacilli were found in his sputum during life.

Post-mortem examination.—The excision behind the left malleolus extends down to the bone.

Digitized by Google

Lungs: There is a large cavity at the right apex, while the whole upper lobe is fibroid. There are a few nodules of caseous bronchopneumonia and also some in the other lung.

There were two symmetrically placed ulcers on the edge of the epiglottis which exposed the cartilage, also two symmetrically placed deep ones above the false vocal cords, of which one extruded through into the right sacculus. On the trachea were scars of healed ulcers one third to half an inch across, with radiating bands of connective tissue.

Heart 14 oz.; left ventricle hypertrophied and dilated.

Liver 76 oz.; there is congestion and extensive cell-infiltration along the portal and hepatic vein areas; but in addition there is an extensive destruction of the liver-cells occurring locally, and not unlike that seen with acute yellow atrophy.

Spleen 14½ oz. with some tubercles.

Kidneys 16 oz.; tubal nephritis, with some interstitial change.

Tibia (right): There is an abscess containing two drachms of pus, separating the periosteum from the bone over an area one and a half inches square. This was situated on the internal and posterior surfaces commencing three inches above the lower end.

Immediately above this on the posterior margin is a wormeaten depression half an inch by three eighths and one eighth inch deep; a second similar depression five sixteenths inch across on the inner surface six inches from the lower end and three inches from the lower end on the same surface is an elongated, flat, raised sheet of bone one quarter inch long, one third inch broad, and less than one twentieth inch thick. On making a longitudinal section there is seen to be extensive disease in the cancellous tissue. Three inches from the top is a yellowish-white irregular sequestrum one and a half inches long by one inch by half inch, which consists of denser bone than that adjacent. Lower down there are several small patches of cancellous tissue which are whitish in colour and changed in structure, and there is a fibrous or gummatous looking material scattered about. Although there is disease throughout the lower part there is no sequestrum. The periosteum is thickened in a great part of the shaft. On stripping off the periosteum the surface of the shaft is found to be irregular, and thickened by periosteal changes in the middle portion of the inner and posterior surfaces.

Left: The surface of the left tibia is but little changed, but the bone is somewhat bowed, as in rickets. On section the medulla is

Digitized by Google

extensively diseased; there are sequestra in similar positions to those in the right tibia. Two and a half inches from the upper end is a sequestrum of thickened caseous bone, extruding for two inches. Below this is a diffuse fibro-gummatous change, and at the lower end, one inch up, is a dense yellowish-white sequestrum, one inch long, which is not separated but is rather loose.

The lesions in the tibiæ may be summed up as:—1. A periosteitis, which has occurred in patches and led to an irregular deposit of bone on the surface, together with spots where small pits of bone have been eroded by thickened periosteum. 2. A diffuse osteitis, which has led to a local condensing osteitis, together with the formation of sequestra; while the tibia are decidedly bent.

The question to be decided is whether these lesions are tubercular or syphilitic. A careful review of the whole case has led me to the conclusion that the latter is the true explanation, which also agrees with Dr. Goodhart's view of the case. The healed ulcers in the trachea, with scarring and the ulcers in the larynx, are undoubted evidence of the coexistence of syphilis. The periosteal changes in the bone, which in places consisted of excavated pits corresponding to thickened fibroid periosteum, showed no tubercle microscopically, and are unlike tubercular changes. The osteomyelitic changes also agree with syphilitic changes in bone, as described by Hill and Cooper. The tibiæ, however, are undoubtedly very abnormal. *May 21st*, 1889.

---

16. *Defective development of right fibula.* (*Card specimen.*)

By L. A. Dunn.

The child, aged 8 years, is the subject of a defect in the development of his right fibula. The foot is everted, and the inner malleolus is very prominent, giving rise to the appearance of a Pott's fracture. The external malleolus is present, but does not reach lower than the inner one. About an inch above the tip it seems to end. The upper third of the bone appears fairly normal, but gradually fades away into the peronei muscles. In the interval the bone appears to be entirely absent. There is no history of

Digitized by Google

accident, and the foot has been noticed to grow out ever since he was two years old. The tibia is slightly curved inwards and forwards, but is otherwise healthy. *April 2nd*, 1889.

---

17. *Spina bifida.* (*Card specimen.*)

By J. Bland Sutton.

The parts exhibited consisted of the vertebral column removed from a child which had survived its birth three weeks. The sacral region of the column was occupied by a cyst shown of natural size in the drawing (Woodcut 4). Ten days before the child died, a portion of the cyst wall sloughed and cerebro-spinal fluid

Woodcut 4.

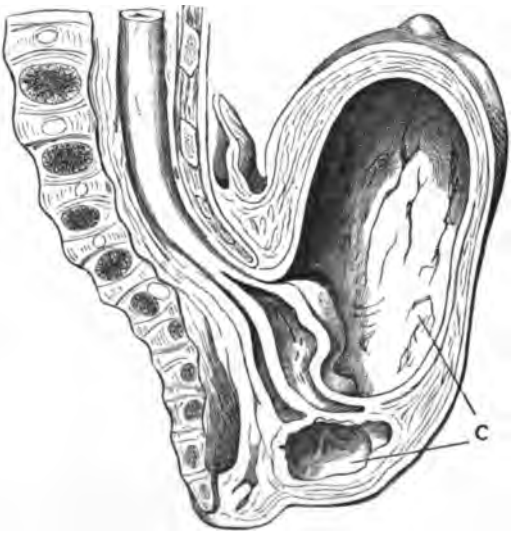

Section of a spina bifida cyst in the sacral region. The cavity containing the arrow is the dilated central canal of the cord.

drained away continually. On splitting the column longitudinally, the cord was found to occupy the whole length of the neural canal

Digitized by Google

instead of terminating at the upper border of the second lumbar vertebra. Opposite the junction of the coccyx and sacrum the central canal of the cord suddenly dilates into a cyst, a syringo-myelocele. This cyst projects into, but is quite distinct from, the cavity of a larger cyst formed by a hernia of the dura mater through the imperfect arches of the sacrum. Thus the spina bifida is a combination of a meningocele and a syringo-myelocele. The small cyst lying quite at the bottom of the sac is formed of dura mater only. The membranes and cord were surrounded by a layer of soft greenish-yellow lymph. *November 20th*, 1888.

Digitized by Google

VII. MORBID GROWTHS AND TUMOURS.

1. *The "crateriform ulcer of the face," a form of acute epithelial cancer.*

By JONATHAN HUTCHINSON, F.R.S.

[With Plate XXV.]

THE form of malignant disease of the face which I have to describe differs very widely from what is known as rodent ulcer, although it occurs on the same parts and under very similar conditions. It is a disease of very rapid growth, whilst rodent is well known to be very slow, and it produces appearances very different indeed from rodent, and I think from all other varieties of cancer of the skin hitherto described. I have for many years been in the habit of calling it the "crateriform ulcer," a name more or less appropriate on account of its taking on the form of a large elevated boil (or beehive), and then breaking down into a deep hollow in the centre. Microscopic examination, which has been made in at least four cases, has always revealed conditions considered characteristic of epithelial cancer, but with a large mixture of the elements common to chronic inflammation. As no other peculiarities have been noted, I shall not trouble the Society with more details on this subject. It is one which in the future must receive more attention.

The growth which I have to describe begins as a painless papule, often, I suspect, in something which was of the nature of a mole, and in the course of a few months lifts itself to the height of a quarter or half an inch or more. Its base is rounded and usually, but not always, well defined and free from inflammation. At the end of a few months a process of breaking down begins in the centre, and a large cavity is excavated. At all stages the substance of the growth, although not hard, is very firm. On several occasions I have attempted to scrape these growths away and found them too firm to permit of its being easily done. As regards implication of the lymphatic glands I have no positive evidence

Digitized by Google

to offer. I have never as yet seen the glands enlarged, but then I have not watched some of my cases for prolonged periods. In one case I know that after excision of the growth the patient has remained for some years without local recurrence or gland disease, and in two or three others in which I have lost sight of the patients I have reason to believe (but without certainty) that they have remained well. A very remarkable feature in the disease, and one which is especially so when we take it in connection with its rapid development in the first instance, is that the disease after excision does not appear to be prone to recur. Thus far I have not in any single instance seen a re-development on or near to the same place. In one instance a similar growth to that first removed developed subsequently on the opposite eyebrow. This is the only instance in which a patient has returned to me for any form or kind of recurrence of the disease. In making these statements, however, it is to be admitted that my total number of cases is not large. I have seen a few of which I have not been able to find any notes. The following is a brief statement of the particulars of the cases which I have seen. I have preserved portraits of most of them.

Case 1.—A man, named James E—, aged 62, under care at the London Hospital in 1872. He had an ulcer on the cheek under the outer angle of left eyelids. It presented a roundish beehive-shaped lump, an inch and one third across, and three quarters of an inch in thickness. It was inflamed and reddened. It was from four to six months' growth. It was excised freely with much adjacent skin, and a flap of skin transplanted into the wound. I believe that there was no recurrence (see fig. 1).

Mrs. B—, a woman between 60 and 70, living near Victoria Park, under care in 1880 at the London Hospital. She had a growth exactly like that described in the preceding case, but placed on the right side of the nose near to the inner angle of the eye. It was of three months' growth, freely excised, and so far as I know never returned (see fig. 2).

Case 2.—A woman, named Sarah M—, aged 62, under care at the London Hospital in 1880. In this case I had excised two years before, the whole of the right upper eyebrow on account of a large crateriform ulcer, at the same time transplanting a flap of skin. The parts remained sound, but two years later a growth of a precisely similar kind developed on the opposite eyebrow. Attempts were made to cure this by scraping and cautery, but

Digitized by Google

Digitized by Google

EXPLANATION OF PLATE XXV.

Illustrating Mr. Hutchinson's report on the Crateriform Ulcer of the Face. (Page 275.)

FIG. 1.—A portrait of James E—, aged 62.

FIG. 2.—A portrait of Mr. B—, aged between 60 and 70.

FIG. 3.—A portrait of Sarah M—, aged 62. On the right side a transplantation had been done two years before. The little boss at root of nose was caused by the twitching of the neck of the flap. There was no return of the disease here. The opposite side shows an independent growth which presents exactly the appearances of the one for which the right eye was excised.

Digitized by Google

Fig. I

Fig. II.

Fig. III

E. Burgess del.

Digitized by Google

Digitized by Google

when I last saw the patient it had not healed. The woman ceased her attendance at the hospital. I have done my best since to find out what became of her, but have been able only to ascertain through the Registrar-General's office that a woman of the same name and age and living in the same locality died of disease of the brain two or three years ago. This case is the subject of figure 3 in the coloured plate.

Case 3.—An old woman, nearly 70, under care at the London Hospital, in whom the growth occurred on the side of the nose. It had developed in a few months to the size of the end of a small thimble. It was excised, and so far as I know did not return.

Case 4.—A man of about 60, originally under the care of my colleague Mr. James Adams at Moorfields. The growth was of only a few months' duration, and was somewhat larger than in the preceding case. It was excised, and I know that there was no return for a year or more.

Case 5.—I am doubtful whether the following case ought to be placed in the same group, as I did not see the patient whilst the disease was in the crateriform stage. It is an example, however, of epithelial cancer of the face, of a kind quite different from the ordinary rodent ulcer, and it is not improbable that it represents the later stages of the growth which is crateriform in its early stage. A gentleman, aged 44, from Scotland, had a fungating growth in the middle of his cheek. We believed that it had begun in a mole. It had developed rapidly, and had been treated with caustics in Edinburgh before I saw him. Its condition at this latter date is well shown in the portrait which I possess, and which is copied in my 'Illustrations of Clinical Surgery.' It had not produced any gland disease. After free treatment with chloride of zinc paste it showed a remarkable tendency to sprout up again, and repeated applications had to be made. It recurred six months later, and the same treatment had to be adopted; after that, I believe, it remained well.

Case 6.—A gentleman, aged 66, who was brought to me by Dr. Hingston Fox, January, 1889 (my most recent case and the one from which sections were shown to the Society). He believed that the growth had originated in a mole. It presented the usual characters, but on a smaller scale than any of the others. It had been growing about three months. I excised it freely, taking the whole thickness of the skin. As only nine months have elapsed since the perform-

Digitized by Google

ance of the operation, I cannot speak as to the return. In this case my son made a careful microscopic examination. The sections showed typical squamous epithelioma, with well-marked nests, and a great amount of small-celled infiltration which had a tolerably well-defined boundary. The down-growth broke up and branched feebly, as in the more malignant forms of epithelial cancer. Well-marked prickle-cells were observed in them (see page 280).

Case 7.—One of my most important cases is that of a man, whose portrait I have already given in my 'Illustrations of Clinical Surgery,' see pl. xcii. He was 40 years of age, and the growth had been developing only two months when he came under observation. He was sent to me by Dr. Vores, of Yarmouth, February 28th, 1883. The growth was ill-defined at its borders, and involved the whole of the right side of the lower half of the nose, extending very near to its tip and near to the border of the ala. It had the thickness of a third to one half of an inch, and was just beginning to break down in the middle. The man, who was an intelligent observer, assured me that nine weeks was the very utmost duration of the growth, and that it was very rapidly increasing. He had never had syphilis. There was more tendency to infiltration, and much less of the production of the beehive form than I had seen in any other case. The extreme rapidity of growth induced the suspicion that it must be rather of the nature of chronic inflammation than a neoplasm. But a careful investigation of the evidence, and the entire absence of any suspicion of syphilis, pointed to the latter conclusion. Before proceeding to an operation I took the precaution of getting the opinion of Sir James Paget, who wrote to me, "I think it certain that this is a case of what may be called acute epithelial cancer, and I would remove it at once and freely, though with fear of rather speedy recurrence." I excised the whole of the side of the nose. Microscopic examination confirmed the opinion that the growth had the ordinary elements of epithelial cancer, mixed with the changes of chronic inflammation. The parts were left to heal without any attempt at closing the wound, and the man has since worn a shield to cover the gap. Six years after the operation, in the early part of 1889, I heard from the patient that he still remained quite free from any return of the disease, either in the scar or glands, It is needless to say that the very unexpected result of permanent immunity as regards return in this case is a most encouraging fact in reference

Digitized by Google

to the performance of operations. As a rule, I think the more rapid the development of cancer in the first instance, the more early do the lymphatics become implicated, and the same statement is probably true as regards the age of the patient. Yet here we have extremely rapid growth in a comparatively young patient, and yet there has been no return. A very marked contrast is presented with what we know of epithelial cancer when occurring on the tongue and on the genitals. In these regions the implication of the lymphatics is so early that it is but seldom that we are enabled to operate early enough.

Case 8.—A lady, aged 55, who was sent to me by Dr. Thursfield, of Leamington, had a growth on her cheek which should, I think, be placed in this category, though it had not in her case gone so far as the crateriform stage. It was round, its base being about as large as a sixpence, and it was assuming somewhat of the beehive form. She said that it had developed in a mole which she had had all her life. This mole had begun to get bigger about a year ago, but had only taken on rapid growth quite recently. This growth was excised by Mr. Marriott, of Leamington, and presented the usual conditions. It was on its surface granular, and as if about to ulcerate. I believe that the lady has remained (one year) without return.

I have looked through several collections of portraits in the Hospital museums, in the hope of finding representations of the crateriform ulcer. At the Hospital for Cancer I was fortunate enough to find one which represented almost exactly the state of things depicted in the portrait published in my "Illustrations." Dr. Purcell, under whose care the patient had been, was kind enough to allow me to see her. She was a woman of about 66, in good health, and she stated that she had only known of the growth for a few months before the operation. The case is therefore an extremely close parallel to the one to which I have referred. There was no gland disease. Dr. Purcell had excised the growth about six weeks before I saw the patient, having taken, as I did in my case, the whole ala and almost the whole of the side of the nose. The parts were just healed at the time of my examination (December, 1888). The growth had been diagnosed as epithelial cancer. Specimen 485 (see vol. i of the 'Catalogue of the Royal College of Surgeons),' is the left side of the face of a woman aged 60, showing a large mass of epithelial cancer involving the eyelid. It was presented

Digitized by Google

by Dr. Lediard, of Carlisle, and is of some interest in connection with the present subject. Clearly it was not of the nature of rodent ulcer, for it had been growing only for about six months before the patient's death. For three years, however, the patient had noticed a little spot "like a mole" on the left side of her forehead. An attempt had been made to destroy the growth by chloride of zinc, but the growth had recurred and a gland in front of the ear had enlarged. Death had been brought about by repeated hæmorrhages. The borders of the cancer on the forehead at the time of death were everted, elevated, and sinuous; and it presented a deep ulcer. I think it very possible that this specimen represents the later stage of the growth which I have described. It is classed in the Museum Catalogue as epithelial cancer, but without any detail as to its microscopic examination. Mr. F. Eve has recently informed me that he has recognised in the museum of the Hospital St. Louis in Paris, a cast which presents very exactly the conditions present in the crateriform ulcer, and that it is there described as "epithelial cancer of sebaceous gland origin."[1]

The following is my son's report of his examination of the growth in Case 6, which was the one submitted to the Committee.

The microscopical anatomy of the crateriform ulcer excised from Mr. — (Case 6).—The tumour examined was a small rounded one, having a diameter of nearly half an inch. On a vertical section the floor of the central depression and the ridge round it were seen to be of a yellowish-white colour, and to have a slightly lobulated form, suggesting epithelial down-growth. This was confirmed by the microscope, the tumour being a squamous-celled epithelioma, with well-marked cell-nests scattered throughout it. The edge of the epithelial growth was generally well defined, and around it was an abundant small-cell deposit. This also had a fairly sharp outline, more so than is commonly seen in sections of epithelioma and the adjacent corium. The activity of the tumour's growth was in-

[1] Since my communication to the Society, a portrait has been published in the 'Illustrated Medical News' by Mr. J. Burns, which shows a near resemblance to the conditions described in a malignant growth on the face. Microscopic examination, however, revealed the conditions of sarcoma, and not of carcinoma. Still later, and whilst the proof slips of this paper are under correction, Mr. Anderson, of St. Thomas's Hospital, has published in the 'Journal of Dermatology' for September another case with some important remarks confirmatory of my conclusions.

Digitized by Google

dicated by the multiplication of the nuclei and the presence of numerous free nuclei amongst the cells.

Many sebaceous glands and hair-bulbs were present at the edge of the growth, but it is very doubtful whether the epithelioma had started from either of these structures, for in some parts prickle-cells, like those of the surface epithelium, were to be found. It may, however, be noted that at the deepest part some of the epithelial processes were curiously tubular in aspect, somewhat like distorted sweat-glands. The edge and floor of the "crater" were lined throughout with squamous epithelium.

Report of the Morbid Growths Committee on Mr. Hutchinson's specimen of crateriform ulcer of the face.—The above description has been confirmed by our examination of the specimens. The microscopic characters seem to us to establish the view, suggested by Mr. Hutchinson's note, that the case is one of epithelioma (squamous-celled carcinoma).

NORMAN MOORE.
H. H. CLUTTON.

April 2nd, 1889.

---

2. *Congenital cyst of the tongue.* (*Card specimen.*)

By H. A. LEDIARD, M.D.

THIS cyst was removed from the tongue of a child aged 6. It was noticed at birth, but had been growing rapidly of late. With difficulty the lips could be closed over the tongue, and the usual state was for the mouth to be open and for the globular end of the tongue to protrude between the lips like a large plum. Speech was very indistinct. Some of the incisor teeth had been shed from pressure, and the alveolar margins of the jaws were displaced forwards from the same cause. The frænum of the tongue was ulcerated away.

The cyst was found lying within the muscular structure of the tongue; it was centrally placed, and extended backwards nearly to the hyoid bone. It was separated easily from its loose attachments, and the child made a good recovery.

The cyst measures two inches in length, and has an hour-glass

Digitized by Google

contraction towards one end; the widest part measures rather more than an inch. The walls of the cyst are thin and semi-translucent; the contained fluid was of a light brown colour, and rather like thin gruel in consistence.

Microscopic examination showed mucous corpuscles, fatty granules, epithelium, crystals of triple phosphate, and cholesterine.

April 2nd, 1889.

---

3. *Pedunculated chondroma from knee-joint.* (*Card specimen.*)

By S. G. Shattock.

Of pure cartilage. Removed by H. H. Clutton, Esq. The peduncle was divided at the operation. *May 7th*, 1889.

---

4. *Myxo-lipoma of the spermatic cord.* (*Card specimen.*)

By J. H. Targett, M.S.

History.—This specimen was removed from a gentleman, aged 35, married. It formed a large tumour in the right scrotum, and had been growing for five years, at first slowly, but much more rapidly during the last two years. It measured vertically twelve inches, and was a source of inconvenience and pain from its size and weight. It was soft, semi-fluctuating, and not translucent. When punctured nothing came out.

The tumour was excised by Mr. Bryant, and it was found to have involved the testis and extended up the spermatic cord. This was ligatured, and the growth removed. The wound suppurated, and a large quantity of liquid fat or oil was discharged with the pus. Death occurred twenty-five days after the operation from peritonitis. Before death a swelling was found in the right iliac region, which was considered to be a new growth. No *post-mortem* examination was permitted, but by enlarging the wound in the scrotum the hand was passed along the inguinal canal into the peritoneal

Digitized by Google

cavity. In doing so pus was evacuated, which was due to the peritonitis. A mass was now felt a little below the level of the right kidney, but not actually in the iliac fossa. It was adherent to the intestines, and could only be removed by tearing it out with the hand. Hence its relations are not known, but it seemed distinct from the perinephric fatty tissue. The kidneys were quite healthy.

Description of specimen.—A median section has been made, exposing the healthy testis and part of the epididymis below and in front of the tumour. The vas (stained red) is seen in part of its course, and the parietal layer of the tunica vaginalis is covering a portion of the tumour. The tumour itself consists of two distinct masses, the one white, lobulated, composed of fatty tissue, and in close contact with the testis; the other grey, encapsuled, semi-translucent in appearance, and situated higher up the cord. The latter mass is hemispherical in shape, four inches in diameter, and is composed of myxomatous tissue infiltrated with fat-globules.

At the back of the jar one half of the mass, which extended up the inguinal canal to the abdominal cavity, is shown. It is nine inches in length, and adding to this the length of the tumour excised from the scrotum, we obtain fifteen inches as the minimum length of the fatty cord from the abdomen to the bottom of the scrotum. The points worthy of note are the side affected (*right*),[1] and the circumscribed myxomatous formation in the midst of the adipose tissue. The specimen is preserved in Guy's Museum; see also Catalogue of College of Surgeons (No. 4293 A).

May 7th, 1889.

---

5. *Epithelioma of floor of mouth, tongue, and lower jaw.* (*Card specimen.*)

By Raymond Johnson, M.B., B.S. (for Mr. Heath).

G. C—, male, aged 59, was admitted to University College Hospital, under the care of Mr. Heath, on December 3rd, 1888. The duration of the disease was twelve months. He had

1 Hutchinson, 'Trans. Path. Soc.,' vol. xxxvii, p. 456.

Digitized by Google

been operated on three months after the disease in the floor of the mouth was first noticed. Recurrence soon occurred, and when admitted there was a large ulcerated cavity in the floor of the mouth, involving the tongue and the lower jaw. The parts exhibited were removed by operation.

Invading the floor of the mouth is a ragged ulcerating growth. It is extending into the substance of the tongue from below. The front of the lower jaw is completely destroyed, the body ending on either side in the position of the bicuspid teeth in a ragged surface. The growth has extended forwards into the soft structures of the chin and on to the posterior surface of the lower lip. It extends downwards below the jaw into the muscles, passing to the hyoid bone. The specimen includes the whole tongue, a small piece of the lower jaw on either side, and the skin of the chin which was invaded.

After the operation the patient was fed with a long tube and did well until the ninth day, when the breathing became difficult. Râles were heard at both bases, and the temperature was 102·4°. Death occurred on the eleventh day. Some patches of lobular pneumonia were found in the lower lobes of both lungs.

January 29th, 1889.

---

6. "*Tumour*" *of skin* (*cylindroma carcinomatodes*). (*Card specimen.*)

By R. G. Hebb, M.D.

G. G—, male, aged 68, was admitted into the Westminster Hospital November 26th, 1888, under Mr. Macnamara for a "tumour" on the bridge of the nose, which had the seeming characteristics of rodent ulcer. The "tumour" was ovalish, measuring an inch by three quarters of an inch. It began two years before as a "pimple," which broke, leaving an ulcer with central depression and somewhat thickened edges.

Microscopically the "tumour" consists of cells resembling those of the columnar layer of the skin, and from which there is evidence that the neoplasm springs. The new growth is arranged in irregu-

Digitized by Google

lar clumps or areas, each of which is limited by an outer layer of columnar cells, and is made up of a ramifying network of cells, arranged so that the inosculating strands leave a series of cavities.

The character of the cells, their disposition, and the presence of the holes, serve to distinguish the growth from rodent ulcer, for which it was mistaken. It closely resembles a tumour of the skin described by Mr. Clutton in the 'Transactions of the Path. Soc.,' vol. xxxvii, p. 479, and is not unlike the skin cancer of Ziegler, cylindroma carcinomatodes. For pointing out these resemblances, and also for the references, I am indebted to Dr. Sharkey.

April 2nd, 1889.

---

7. *Duct cancer of breast.* (*Card specimen.*)

By H. Betham Robinson, M.B.

E. W—, aged 42, married, was admitted into St. Thomas's Hospital, under the care of Sir William Mac Cormac, on June 25th, 1888.

A month before admission she noticed a small lump in the right breast, which gradually increased in size. There was occasionally shooting pain in the breast, especially at night, but it was not severe. There was tenderness on pressure. She had lost flesh for the preceding eight months.

On admission there was a nodule about the size of a marble in the upper and inner part of the breast at its extreme margin. Its surface was fairly smooth, and it appeared to be freely movable in the breast tissue. There was no reddening of the skin and no retraction of the nipple. There was a little thickening to be felt at the upper part of the axillary margin of the pectoralis major.

The tumour was removed on June 30th. It was almost circular, of an inch diameter. The growth had a fairly well-defined capsule, was very soft and granular, and bulged on section; it was of a milky-white colour. On scraping it a large amount of epithelium could be removed.

Microscopically, the capsule is composed of softish fibrous tissue,

Digitized by Google

with well-marked trabeculæ of the same material connected with it, and composing the stroma of the growth. In the capsule are several small patches of granulation-cells, among which, under a high power, are seen sections of ducts lined with columnar epithelium; this is evidently the earliest stage of the new growth. The trabeculæ are covered with epithelium several layers in thickness; the deepest layer is columnar with oval nuclei, but the other layers are made up of cells spheroidal in shape.

April 16th, 1889.

---

8. *Tumour removed from Scarpa's triangle.*

By SYDNEY JONES.

THIS tumour, the size of a small cocoa-nut, was removed by me from a man aged 35, admitted into St. Thomas's Hospital on December 14th, 1888. He stated that, about five and a half years previously, he first noticed a lump in Scarpa's triangle on the right side. It was then about the size of a walnut. He could not move it about. It grew slowly but steadily for about five years; and eight months previous to his admission into St. Thomas's he applied at the Salisbury Infirmary. The tumour was there aspirated, and 24 oz. of clear fluid, it is said, were drawn off. The tumour soon refilled, and three weeks later was tapped again, when 26 oz. of what the patient supposed to be pure blood were drawn off. A drainage-tube was inserted and kept in for some time. Iodine lotion was frequently injected. The sinus remained open and discharging until a week previous to his admission into St. Thomas's. The size of the tumour was diminished since the tapping. There had never been any pain in the tumour, though its bulk and position interfered much with his occupation as brakesman.

The tumour at the time of admission was hard, tense, and about the size of a cocoa-nut, filling up the whole of Scarpa's triangle, apparently fixed to deep fascia, but not to bone. It was movable both laterally and vertically, there was no fluctuation, no increased heat, no enlarged glands. The saphena vein ran over the front of the tumour. The femoral artery was felt running beneath the

Digitized by Google

upper part of the tumour; lower down was running on the outer side. The Sartorius skirted the outer edge of the tumour.

On December 19th I proceeded to remove the tumour. The saphena vein being in the way was divided and ligatured. The femoral artery was pushed upwards. The superficial femoral was flattened and embedded in a groove on the outer surface of the tumour. About one and a half inches of its length had to be removed. The femoral vein pierced the dense connective tissue at the upper part of the tumour, and was also divided. The deeper part of the tumour was connected with the fascia covering the pectineus and adductor longus. These muscles were quite exposed. Nothing was seen of the psoas.

The tumour was hollow, with dense fibrous walls, about an inch or more in thickness, and nodules apparently of more recent growth cropped out on the exterior. In the interior of the cyst was some clear yellow fluid, mixed with shreds of lymph; and lymph was adherent to the interior of the cyst.

Of course, after division and removal of some length of the femoral artery and vein, also of the saphena vein, one looked with some anxiety as to the progress of the case. The limb, at first cold, on the following day regained its warmth; and with the exception of some œdema of foot and leg which showed itself some nine or ten days afterwards, but which soon subsided, no untoward symptom occurred; and the wound healed and the patient left the hospital well on March 1st. *March 19th*, 1889.

Report on Mr. Jones's specimen of tumour of the thigh by Mr. Shattock.—In some sections the main structure is dense fibrous tissue, in places the seat of hæmorrhage, as evidenced by collections of red discs or elongated groups of brownish-red pigment granules; and merging into this occur patches of spindle-celled tissue disposed in intersecting fasciculi. Sections from other parts are less simple in structure. The tissue is of small cells, somewhat irregularly shaped (at least their nuclei are so), and with little intercellular substance, though the latter varies, and is in parts in considerable relative amount. The most striking objects, however, in these parts are freely scattered spaces, circular or oval for the most part, the nuclei of a single series of the cells around which are set more or less radially; and in some a flat-celled, endothelial-like lining is discernible. A few of these spaces are empty, a few

Digitized by Google

hold fragments of a nebulous, unstained substance; most, however, hold a similar substance in varying degree, including stained elements of round or oval form like nuclei.

The nucleated substance is often somewhat stellate, but confined to the lumen of the containing space. Different views may be taken of the nature of this specimen, which on this account was submitted to the Morbid Growths Committee.

One such is that it is bursal. In its position it corresponds with no recognised bursa, though when the true nature of bursæ is considered, this counts for little. On the hypothesis that the tumour is a bursa, it would be difficult to find, by reason of its deep situation, a traumatic cause adequate to produce inflammation enough to lead to so thick-walled a sac; had there been a history of syphilis, a specific inflammation might have been invoked as sufficient for the result.

The spindle-celled tissue present in places, however, may be looked upon not only as possibly indicating parts in which the final term of an inflammatory process has not yet been reached, but as being sarcomatous. Sarcoma-growth may have supervened in a bursa the seat of previous inflammation, or the sarcoma tissue itself may have undergone fibrification. In any case the existence of irregularly-distributed inflammation is evident in collections and lines of leucocytes in the fibrous parts of the tumour.

Another view, and one which I offer for consideration, is that the tumour has arisen in a lymphatic gland. The amount and nature of its contents and its position by the femoral vessels are in favour of this.

It may be remembered that two years ago Mr. Treves reported a series of cases of malignant cysts in the neck, secondary epitheliomata, some of which were distended in a remarkable manner with clear, yellow serous fluid, which Mr. Treves suggested was retained lymph; and he quoted a case reported in the 'Mémoires de la Soc. de Chir. de Paris,' 1852, of a man in whom a large tumour of the neck contained transparent serum, and its solid portion resembled the tissue of a lymphatic gland. It is possible, therefore, that the cyst under notice is of a similar nature, and has arisen in a lymphatic gland affected with sarcoma.

As a proof that contents similar to lymph may occur in sarcomatous tumours, *not* arising in connection with lymphatic glands, I adduce a specimen in St. Thomas's Hospital Museum (*c* 249[1]).

Digitized by Google

It is a large central tumour involving the lower end of a femur, and hollowed out in a capacious cyst. The cyst in the tumour is thickly lined with a whitish, succulent, structureless substance, such as lymph coagulum might be after preservation in alcohol. In this case it is recorded that the fluid within the cyst was straw-coloured and clear, and that it coagulated immediately on being let out. I have examined the tumour microscopically in two situations, and find it to be a typical spindle-celled sarcoma. But the medulla in the ends of the long bones is allied to lymphatic tissue.

Report of the Morbid Growths Committee on Mr. Sydney Jones's specimen of tumour of Scarpa's triangle.—The tumour at first sight closely resembles a bursa, but besides the fact that there is no such structure existing normally in this position, the living membrane does not show any of the reticulation or of the rounded nodules so commonly present. Instead it is particularly smooth.

The great hardness and thickness of the wall seem opposed to the lymphatic origin of the growth as is the fact that nothing resembling lymphatic tissue can be seen by the naked eye; nor to our observation is there any lymphoid tissue present either in the microscopical sections submitted by Mr. Shattock or in those which we have ourselves made. In our opinion the specimen is best described as a myxo-sarcoma with a central degeneration cyst. The sections show a matrix in some parts densely fibrous, in others homogeneous or finely fibrillated, and besides these appearances there are irregular areas of hyaline material, taking the logwood stain deeply and apparently identical in structure with the ill-developed hyaline cartilage found in parotid tumours, more especially in those undergoing degeneration, and in which cysts are common. The cells found in the matrix differ in different parts of the section, many are round and spindle, while others, especially those in the hyaline part of the matrix, closely resemble the angular cells which form so constant a feature of parotid tumours. The spindle-cells in their characters and arrangement exactly correspond with those of fasciculated sarcoma. In other parts, well-formed myxomatous tissue with branching cells is visible. Three forms of spaces in apertures are seen in the sections; those with muscle-cells and nuclei are evidently small arterioles; others with well-defined walls and a single layer of cells

Digitized by Google

but without muscle coats we are also inclined to consider vascular, while the third form contains the homogeneous coagulum and cells described by Mr. Shattock. We think that the formation of these last spaces can be traced in softening of the myxomatous matrix and cells, and to this origin we would attribute their existence. By a similar process in all probability the central cyst was formed. The impossibility of explaining all the peculiarities of such a tumour on any one theory is obviously difficult, the great density of the walls, for instance, not being in accord with what is usually found in myxo-sarcomata. This aspect of the question has, however, been fully dealt with by Mr. Shattock in his report upon the specimens, and we must await the result of further observations in support of his view, or of that which we submit as being more in accord with the naked-eye and microscopical characters of the tumour.

CHARTERS J. SYMONDS.
May 20th, 1889. ANTHONY A. BOWLBY.

---

9. *Hæmorrhagic sarcoma.* (*Card specimen.*)

By J. A. ORMEROD, M.D.

SEVERAL rounded masses were found in the abdomen, looking like soft, red, recent blood-clot. Some of them were, however, firmer, and seemed to have a certain amount of structure. One had a firm capsule, and contained granular decolourised stuff like an old clot.

The masses were attached to the colon and to the pancreas and back of the stomach.

Microscopic section of one of the softest tumours shows it to be a sarcoma into which hæmorrhage has taken place.

In addition to the tumours the abdomen contained a large quantity of free blood. *May 21st*, 1889.

Digitized by Google

10. *Myxo-sarcoma. Six recurrences in twenty-three years. (Card specimen.)*

By H. Handford, M.D.

The microscopic specimens shown are from the third, fifth, and sixth recurrences, and I am indebted for the material to my surgical colleague, Mr. Wright, under whose care the patient has been during the whole period, and who has performed all the operations. The patient is a woman, now in her fifty-ninth year, with no sign of any secondary growths in the viscera, but in very feeble health from valvular heart disease.

The first tumour was removed from the left groin twenty-three years ago, after it had been growing several years No mole or other congenital growth or mark preceded the original tumour. The tumours have all been somewhat painful, and have always recurred within one and a half to two years of removal, in the immediate neighbourhood of, but not always on the exact site of, the previous one. The very extensive cicatrices, though all the growths except the fourth have been small, show that the tendency to recurrence has been in close proximity to, but not always on the exact site of, the old growth. There is one cicatrix nearly the whole length of Poupart's ligament; another about three inches long, roughly parallel with, but one and a half inches below, the former. There is a third well-defined scar half an inch below the last, and two and a half inches long. And in addition there is some ill-defined cicatricial tissue extending over several inches.

The first three growths I did not see, and I have no information about them except that they were small, appeared to originate in the deeper parts of the true skin, and resembled in consistence and appearance those subsequently removed. None of the growths have involved the muscles or bone. The fourth tumour (third recurrence) had been growing for five or six years, was removed in 1881, and was given to me for examination. It was about one pound in weight, and of soft, gelatinous consistence. Even after hardening the sections were so sticky as to be extremely difficult to manipulate. It evidently arose in the deeper part of the cutis vera, and in some places presented the structure of a granulation-

Digitized by Google

tissue sarcoma, small round-cells, spindle-cells, and irregularly-shaped cells being mingled together in a finely fibrillated, granular matrix. In other places the tissue resembled a pure myxoma, showing abundance of stellate, branching cells with long, delicate processes, between which were clear spaces filled with mucus in a very finely fibrillated meshwork. In some of the softer parts of the growth an *alveolar network of blood-vessels* could be plainly made out.

The fifth tumour (fourth recurrence) was small, and was not preserved.

The sixth and seventh (fifth and sixth recurrences) were small growths, and closely resembled each other.

The last (seventh recurrence) was removed in March, 1889.

The portions of the seventh growth were dark in colour from numerous small hæmorrhages, and consisted of two distinct kinds, one very soft and gelatinous, and the other firmer and lighter in colour. The latter on section was shown to consist almost entirely of small granulation cells, with a little myxomatous tissue here and there. The softer growth contained a framework of the same structure, abundant hæmorrhages, much mucous tissue, and in places a cavernous arrangement, the spaces of which were filled with granular mucus. These numerous spaces, of very varying shape and size, filled with mucus without any cellular elements, formed a very striking feature in this as in the sixth growth.

The tendency to local recurrence shown by spindle-celled sarcomas led to their being termed "recurrent fibroids." This case, among others, shows that the tendency to purely local and repeated recurrence is by no means confined to the spindle-celled sarcomas, but is shared by other varieties.

I have watched another case of sarcoma of the skin through two recurrences in six years, and here again it was not of the spindle-celled variety. It occurred in a gentleman, aged 30, who had had a pigmented mole in the middle of the instep since birth. It was bruised by a man treading on his foot, and then it began to grow rapidly. It was removed within the year, and proved to be an alveolar melanotic sarcoma. The peculiarity of it was the shape of the cells, which, when examined fresh in scrapings, were oval or lemon-shaped, but when hardened and shrunk they appeared nearly round. There were but few spindle-cells. The growth recurred in the cicatrix twice within three years, and the

Digitized by Google

structure was the same on each occasion, except that in the recurrent growths there was an absence of pigment. He has now remained well for three years. *May* 21*st*, 1889.

---

11. *A complete case of ossifying sarcoma.*

By D'Arcy Power, M.B.

[With Plate II, fig. 1.]

Many specimens of ossifying sarcoma, or "osteo-sarcoma" as they were formerly called, have been shown before this Society, and are recorded in the various volumes of its 'Transactions.' None, however, are so complete as the present one, and I therefore need not apologise to the members present to-night for occupying their time whilst I give a short account of the preparations.

The patient, a girl aged 13, was at the Blue Coat School at Hertford. Eleven months before her death she first noticed a slight pain and stiffness in the left knee, which came on after a long country walk. The stiffness continued, in spite of treatment, for three months, but it was not severe, and the patient was able to do her ordinary school work. Three months after the first appearance of the stiffness the knee was observed to be swollen, and the girl was sent home as an invalid; she then came under my care at the Metropolitan Dispensary, where I treated the case as one of tubercular synovitis. As the swelling rapidly increased, and an enlarged and densely hard gland appeared in the groin, the patient was admitted into St. Bartholomew's Hospital under the care of Mr. Savory. The thigh was amputated in its middle third, and a month later the enlarged gland in the groin was removed. A mass of new growth was, however, shortly afterwards detected in the pelvis, and a month before death there were symptoms of a secondary deposit in the lungs.

The first specimen consists of a vertical section through the lower third of the femur, showing a large ossifying sarcoma surrounding the condyles, and extending along the shaft of the bone for a distance of six inches, reaching higher on the posterior than

Digitized by Google

on the anterior surface. The tumour consists of a very dense osseous substance, and it appears to have commenced at the junction of the diaphysis with the lower epiphysis on its posterior surface and beneath the periosteum. It has invaded and obliterated the medullary canal for some distance above the point where it terminates externally. Microscopically, the growth consists of large round sarcoma cells embedded in a matrix, which is comparatively loose, and apparently consists of cancellous bone. The new growth has invaded and is destroying the original bone.

One month after the thigh had been amputated it was deemed expedient to remove from the groin the gland, of which this specimen formed one half. The gland was circular in outline, and measured two inches in diameter. It is infiltrated with ossifying sarcoma to such an extent that it appears to be a mass of bone. It was so firmly attached posteriorly to the sheath of the femoral vessels that an inch of the femoral vein had to be removed with it, and the remains of the vein is still seen lying in a groove at the back of the specimen. Three and a half months after the amputation through the thigh the patient died, and at the *post-mortem* examination the left os innominatum was removed with the stump. The shaft of the femur is flexed and strongly rotated inwards, and in consequence of this alteration in the axis of the limb the vertical section has passed through the great trochanter, leaving the head of the femur untouched. The rami of the pelvis and ischium are very greatly thinned, and are almost completely decalcified. A large masss of new growth projects from the iliac fossa and extends downwards along the inner side of the thigh almost to the point where amputation had previously been performed. The shaft of the femur is undergoing rarefying osteitis, whilst the medulla is infiltrated with a caseous material. The rib shows an infiltration of ossifying sarcoma at the junction of its shaft with the costal cartilage. The clavicle in section shows that its sternal end is infiltrated with the same kind of growth as in the preceding specimens. The new growth has invaded the whole substance of the bone for a distance of half an inch from the cartilaginous extremity. Like all the new growth the infiltration is densely hard.

The lungs were so adherent to the thoracic wall that they could only be removed by lacerating their structure. Both organs presented on their surfaces numerous circular patches of ossifying sarcoma.

Digitized by Google

In the left lung the largest of these new growths on the convex surface measures half an inch across, whilst the smallest is no more than one sixteenth of an inch in diameter. The patches are lightish brown in colour, and appear to originate from the under surface of the pulmonary pleura; they do not extend for any distance into the substance of the lung. On the concave surface the patches are much more extensive, and a portion of the pericardium has become firmly adherent to the lung immediately below its root. In the right lung the patches show a greater tendency to coalesce into large plates; indeed, along the posterior border a mass of solid bone-like substance extends for a distance of three inches. Microscopically, the growth in the lungs consists essentially of a sarcomatous tumour, the cell-elements of which are for the most part round. The cells are enclosed in well-defined trabeculæ, which have the appearance of cancellous bone. No true bone-corpuscles are developed, nor is there any cartilage.

The growth is permeated by large blood-vessels, and there is no lung substance visible. Mr. Marks's drawing well exhibits the characteristics of the growth as they appear under a high power of the microscope (Pl. II, fig. 1).

The specimens, with the drawings, are preserved in the museum of St. Bartholomew's Hospital. *February 19th*, 1889.

---

12. *Retro-peritoneal sarcoma.* (*Card specimen.*)

By Raymond Johnson, M.B. B.S. (for Mr. Heath).

The specimen is a large retro-peritoneal tumour measuring seven and a half inches by seven inches. Over the whole of its posterior surface it was fixed to the back of the abdomen, involving the left psoas muscle.

The left kidney, which is much flattened, lies on the outer and upper surface of the tumour, but it is not involved by the growth. The ureter for a distance of four inches is embedded in the front of the tumour, and below the point at which it emerges there is an oval deposit in the wall of the tube. The aorta is displaced and

Digitized by Google

lies along the inner border of the tumour, through the upper part of which the left renal vessels pass.

The pancreas lies on the anterior surface of the tumour at its upper part. The spleen is normal and not involved.

The central portion of the tumour is degenerated into a gruelly mass; the solid outer part had when fresh a pinkish white colour.

The right lobe of the liver contained two secondary deposits the size of peas. Microscopically the growth is a small round-celled sarcoma.

The specimen is from a man aged 41, admitted to University College Hospital under the care of Mr. Christopher Heath, on September 24th, 1888. He had suffered pain in the left side of the abdomen since December, 1887. The tumour was detected in July, 1888. There had been troublesome constipation but no urinary trouble.

On admission the left side of the abdomen was found to be occupied by a solid tumour, the size of a child's head. It reached upwards beneath the ribs and downwards beyond the umbilicus. Inwards it extended two inches beyond the middle, whilst posteriorly it passed back into the loin. It was dull on percussion, and moved slightly with respiration. There was no upward extension of the splenic dulness, but its lower limits could not be defined from that of the tumour. Urine diminished in amount but otherwise normal. A retro-peritoneal sarcoma, possibly renal, was diagnosed.

On October 3rd, Mr. Heath made an exploratory incision in the left linea semilunaris, but the extensive posterior attachments rendered any attempt at removal impossible.

The patient died on the second day after the operation.

October 16th, 1888.

---

13. *Lympho-sarcoma of kidney.* (*Card specimen.*)

By R. G. Hebb, M.D.

C. M—, female, aged 4, admitted November 6th, 1888, into Westminster Hospital, under the care of Mr. Davy, for an abdominal tumour, of a softish nature, situate in the left flank

Digitized by Google

and apparently connected with the spleen or kidney. The child was rickety and much emaciated. The mother has recently (1889) had the cervix uteri excised for epithelioma. The child died December 15th, 1888.

At the *post mortem* examination it was found that the left kidney, which had retained its shape roughly was invaded by a soft new growth, to such an extent that very little renal tissue was left. The neoplasm occurs in soft white masses, mottled here and there with red from the presence of extravasated blood. There were secondary growths in the pelvic and abdominal glands, in the liver and in the lungs. The left kidney measures seven by three and a half inches. The right is quite normal.

Microscopical examination showed the neoplasm to be a lympho-sarcoma which had evidently started in the kidney. The secondary deposits in the lung show, besides the irregular aggregations of the indifferent cells, gland-like tubules the origin of which is doubtful. None of these were found in the kidney.

April 2nd, 1889.

---

14. *Sarcoma of forearm growing into a large vein at the bend of elbow.* (*Card specimen.*)

By Frederic S. Eve and J. H. Targett, M.B., M.S.

The specimen was sent to the Royal College of Surgeons Museum for dissection by Mr. John Wood.

Description.—An elbow-joint with the upper part of the forearm. Projecting from the flexor surface of the forearm and occupying the flexure of the elbow is a sarcoma which springs from the muscular structures and fasciæ, being apparently unconnected with bone. Its section is moderately firm, and intersected by bands of fibrous tissue. It measures five inches in length by four and a quarter in breadth. The brachial vessels and the median nerve are embedded in the tumour, and immediately above the elbow-joint one of the *veins* is distended by a large pale thrombus, distinctly continuous with the morbid growth. The muscles are thickly studded with trichinæ.

Digitized by Google

In minute structure the tumour was composed of round- and spindle-cells intermingled with ill-developed fibrous tissue. The extension of the growth into the brachial vein was also made up in part of round-, oval, and spindle-cells embedded in granular material, while the remainder consisted of leucocytes and fibrin.

It may be generally observed that tumours extend in the direction of least resistance, and having broken into a vessel would therefore grow along it. This artificial injection demonstrates one of the modes in which dissemination may take place in sarcomata.

February 18*th*, 1889.

---

15. *Granuloma tumour of skin ? lupus.* (*Card specimen.*)

By R. G. Hebb, M.D.

The tumour was removed in February, 1889, by Mr. Spencer from the cheek of a woman aged 25. It was first noticed about fourteen days before the operation. It lay immediately below a pigmented mole equidistant from the ala of nose and the internal and external canthi. The patient is suckling an infant six months old which looks perfectly healthy. No family or personal history of importance.

The tumour, which is about the size of a small pea, lies directly subjacent to a pigmented mole. It consists of a spheroidal mass of indifferent cells (lymphoid) among which are numerous giant-cells. The central part seems very soft and is apparently commencing to break down. The tumour lies in the subcutaneous connective tissue. The mole is composed of aggregations of large sarcomatous cells separated by thin fibrous partitions.

No micro-organisms were found.

From the microscopical appearances the tumour would seem to be lupus.

April 16*th*, 1889.

Digitized by Google

VIII. DISEASES, ETC., OF THE DUCTLESS GLANDS.

1. *Congenital goitre.* (*Card specimen.*)

By H. A. Lediard, M.D.

The infant from whom this goitre was taken was born at full term, and died on the fifth day.

The labour was complicated by hydramnios of very decided proportions.

The child was cyanotic, breathed with much difficulty, was unable to swallow, and when it cried the face became very dusky. The neck was very bulky, and the middle and lateral portions of the thyroid gland were easily felt to be considerably enlarged. The goitre is seen to surround the windpipe and œsophagus like a ring, whilst the latter more especially is compressed. In other respects the infant was healthy.

It is interesting to note that the same patient had previously had hydramnios with a nearly stillborn child, which had a very large neck. (*Post-mortem* examination was not made.)

Spiegelberg (p. 490, vol. i, New Sydenham Soc., 1887) speaks of congenital goitre as one of the rarer fatal diseases.

April 2nd, 1889.

---

2. *Disease of suprarenals; ? nature.* (*Card specimen.*)

By H. H. Taylor.

Patient, male, aged 32. Dark complexion. No symptoms of Addison's disease. Advanced phthisis both sides. Suprarenals enlarged; on section are tough, pale fawn colour.

Microscopically consisted chiefly of fibrous tissue, no tubercular structure, and no tubercle bacilli. *May 7th*, 1889.

Digitized by Google

3. *Lympho-sarcoma of right suprarenal body; the right kidney.* (*Card specimen.*)

By Arthur Davies, M.B.

The right kidney taken from a lad, C. H—, aged 18, with a mass of new growth involving and replacing the right suprarenal body. The growth consists of an abundant round cellular tissue, and exactly resembles that found in the growths in the left lung, liver, ilium, and lymphatic glands. *May 21st*, 1889.

---

4. *Symmetrical tubercular disease of the suprarenal capsules in which tubercle bacilli were found, from a case of Addison's disease.* (*Card specimen.*)

By D'Arcy Power, M.B. (for Dr. Vincent Harris).

The suprarenal capsules are large and firm; the right is larger than the left, and it measures ten and a quarter inches in breadth. The right capsule consists of yellowish hard patches surrounded by a bluish-white tissue, which cut like cartilage and closely resembled that tissue in its naked-eye appearances. The yellow patches look like caseating material, but they are hard and firm, cutting like horn with a knife. There is no appearance of healthy tissue left. The left capsule is apparently affected in a similar manner, but the yellow material is not so marked, and is confined to the medullary portion, where it looks like a corpus luteum.

From a married woman aged 23, who was admitted to the Victoria Park Hospital on July 5th, 1886, with the following history. She had been married six years, during which time she had become the mother of four children, of whom the youngest was born in November, 1885. She had never been really strong since the birth of her first child in September, 1880. During the past three winters she had suffered from a cough, but for the last six months she had been much worse in her general health, and

Digitized by Google

had a considerable expectoration of yellow phlegm; she had become thinner and weaker, and during this period she had noticed about her the appearance of spots on the skin. She had a strong family history of phthisis on the female side.

Condition on admission.—A bright good-looking young woman with brown hair and blue eyes, apparently well nourished and not looking at all ill. Fingers not clubbed. The patient complained of being very short of breath on making any exertion, of considerable weakness and of a tendency to faint.

Her complexion is sallow, the skin of her face, neck, and the backs of her hands are tinted of a very light brown. In the same situations are numerous bright, brownish-black spots, which do not disappear on pressure; they vary in size from a pin's head to a split pea, and are especially numerous and well marked about the ears, cheek, and neck. There is no great development of pigment elsewhere except about the nipples. The darkness of the skin is not marked in the lower extremities, nor are the spots numerous. There is, however, a slight indication of a deposit of pigment at the junction of the hard and soft palate, as well as at the margin of the lips. The patient had noticed that the spots came out in crops and then gradually died away and were succeeded by fresh crops.

On physical examination it was found that there was impaired resonance with prolonged expiration at the right apex, with here and there a few crepitations scattered throughout both lungs, most marked behind. The heart-sounds were clear and the pulmonary second sound was accentuated.

The urine was normal.

The patient continued under observation until her death, on September 13th, 1886, and during the whole time, although she continued cheerful and full of hope, there was a steady downward tendency. The spots continued to appear in successive crops, and the weakness and shortness of breath increased. The temperature varied between 98° and 99° F.

On the 9th of September excessive vomiting came on, which continued more or less until the 13th, on the morning of which day she suddenly became comatose, and so continued until 5.30 p.m. on the same day, when she died.

The autopsy was made on the following afternoon. The limbs were wasted, but the body was not emaciated; there was a thick

Digitized by Google

layer of fat over the abdomen. There was general but not excessive pigmentation of the skin, which was most marked on the face. The pigmented spots were almost exclusively confined to the face and neck, but there were a few upon the thighs and legs. There were a few old adhesions in both pleuræ, and a small consolidated patch at the extreme apex of the right lung, about the size of a nut, beginning to break down in the centre. The rest of the lung substance was healthy.

The heart was small. The liver, spleen, and kidneys were natural. The uterus was retroverted and held in that position by old adhesions.

With the exception of the changes found in the adrenals and those just described, no other morbid appearances were found in any organ.

Histological appearances of the suprarenal capsules.—Externally was a layer of varying thickness, chiefly consisting of adipose tissue containing many small inflammatory cells. This layer was divided into alveoli by firm fibrous tissue. Beyond this layer, in the part corresponding with the position of the normal cortex, was a dense fibrous tissue containing fewer cells. Enclosed, as if in a capsule, by this fibrous tissue were larger and smaller masses of different shape and of a horny material, which stained with difficulty. These masses looked to the naked eye like caseous material, as they were of a yellowish colour, but microscopically they are clearly not caseating masses, and can only be compared with horn, though they cut with greater ease. The majority of the masses were arranged so as to correspond with the columns of cells in the normal gland. Bacilli corresponding morphologically with those of tubercle were found in sparing numbers in one or more of the sections of the diseased organs.

The specimens are preserved in the museum of St. Bartholomew's Hospital, series xxvii, No. 2322 (*a*). *May 9th*, 1889.

Digitized by Google

IX. DISEASES, ETC., OF THE SKIN.

1. *Pemphigus malignus.*

By G. Newton Pitt, M.D.

Charles P—, a tanner, aged 50, was admitted on January 3rd, 1888, under the care of Mr. Golding-Bird, to whom I am indebted for permission to publish the case. He is a married man, without any syphilitic history, who enjoyed good health until last October, when he poisoned his left little finger, and was laid up three weeks. He then returned to work, and five weeks later poisoned his left thumb, and this again laid him up for three weeks. He then noticed some small vesicles upon his arms, thighs, and neck, which soon disappeared, while he again returned to his work for three weeks.

On December 27th he noticed some fresh vesicles on the perinæum, about the penis, and between the thighs. The vesicles were large, increased rapidly in number, and broke into each other, so that shortly he had a raw surface over the gluteal region and over the back of his thighs.

On admission there was a large, raw, bleeding surface, extending from the crest of the ileum to the popliteal spaces, which had been formed by the breaking of innumerable bullæ, of which some with blood-stained contents still persisted, together with numerous small islets of skin. The penis and scrotum are covered with raw areas and dried serum.

He passes his water beneath him unconsciously; and is slightly delirious at night. Temperature 100°.

January 6th.—Bullæ have formed on the feet. The sores are being dressed with boracic ointment.

7th.—Ordered Liq. Arsenicalis ♏iv. Bullæ are forming on the arms. Temperature 100°.

9th.—He is rapidly getting worse. The affected areas are steadily increasing, and large loose bullæ quickly form (containing

Digitized by Google

sanious serum), especially on all points of pressure. He gradually became pulseless, more feeble, and died next morning.

Post-mortem—Fairly well-nourished man with iron-grey hair. There is an extensive area over the gluteal regions, extending down over the thighs and up over the loins, which is ulcerated, but not deeply. This large area, measuring sixteen inches across, twenty-two inches from above downwards on the left side, and sixteen inches on the right, is almost entirely denuded of epithelium, and is covered by red, fine, healthy granulations, and the margins look as if they would heal readily, but during life no repair had taken place. The area, however, is thickly dotted over with small areas of skin one thirtieth to one eighth of an inch across, but mostly smaller than one fifteenth of an inch, looking as if extensive skin grafting had been performed, but really they are areas of skin which have persisted between the vesicles and bullæ.

The ulceration also extends on to the perinæum, penis, and inner side of the thighs.

The skin has been very readily rubbed off over large areas at all points of pressure, large flaccid bullæ have formed, and the epithelium has become readily detached. On the shoulders, angles of the scapulæ, elbows, and calves of the legs, there are raw surfaces, which present an appearance similar to extensive scalds, where blisters have formed and the epithelium rubbed off. Over the arms, forearms, hands, and thighs there are numerous loose blebs, the epithelium over which is sodden and friable. Over the ankles, legs, forearms, and hands are numerous small vesicles containing blood-stained serum, but there are not effusions of blood, such as are found in purpura. The lungs were œdematous and emphysematous. Heart 9½ oz., healthy. Liver congested. Spleen 2½ oz., not soft. Kidneys 13½ oz., large, but look healthy on section. The mucous membrane of mouth, œsophagus, and stomach are healthy.

Microscopically.—A section through the ulcerated surface of the skin on the back showed intense cell-infiltration of the superficial part of the corium, especially along the blood-vessels and in dense lines which probably mark out lymphatics. The vessels are engorged with blood, and there are minute hæmorrhages. The cells of the sweat-glands show signs of proliferation. In the ulcerated portions the loss of tissue varies, in places only the horny layer has gone, in others only the deeper epithelial processes are present,

Digitized by Google

and in some the papillæ are destroyed, hence scarring would have resulted. The structure in the gluteal sore consists of granulation tissue, with the formation of embryonic new vessels. In places where the Malpighian layer is still present there are spaces between the cells.

Acute pemphigus is so rare that its existence was denied by Hebra, yet well-marked cases have been recorded by Dr. Southey ('Clin. Soc. Trans.,' vol. viii), Dr. Payne ('St. Thomas's Hospital Reports,' vol. xii), and by Sir Dyce Duckworth ('St. Bartholomew's Hospital Reports,' vol. xx). Of these the last patient, a man aged fifty-four, with chronic Bright's disease, died on the ninth day. The case which I am bringing before the Society this evening was almost as acute. The patient noticed the first crop of vesicles exactly a fortnight before his death, which was directly due to the large area of the skin which was affected. This attack had been preceded by a slight one three weeks previously which had only lasted for a few days.

The etiology of the disease is practically unknown, but in this case it is impossible not to associate it with the poisonings of his fingers which resulted from his occupation as a tanner. At no period were there any lesions to suggest malignant pustule with which we are quite familiar at Guy's Hospital, nor was there any reason to believe there was anything exceptional about the poisonings of the fingers.

The condition may fairly be described as pemphigus malignus. There was no attempt at healing. The bullæ were very large, formed rapidly, and were flaccid, the contents being mostly blood stained.

The unexpected and rapidly fatal ending to the case were due probably to the entire absence of reparative power and to the large extent of skin affected, and was not, as is often the case, due to the asthenia which ensues with the prolonged suppuration and sleeplessness.

A search through the *post-mortem* records at Guy's Hospital shows that there have only been during the last twelve years three other fatal cases.

Geo. W—, aged 49, admitted under Mr. Durham March 18th, 1878. Four years previously he was under Mr. Hutchinson's care for six months in the London Hospital with an eruption which broke out on the face and afterwards appeared on other parts of

Digitized by Google

the body. He was then twelve months without treatment. Again he became worse, and was laid up in bed for seven months. He then attended as an out-patient at St. Bartholomew's Hospital for six months, but not for the last sixteen months. Numerous large bullæ all over. Temp. 102°—103°. He developed erysipelas, and died a month later.

Post-mortem.—The entire trunk was covered with excoriations which produced a raw surface; in places the detached cuticle still adhered. The appearance was not unlike that due to an extensive burn. In the few parts not affected, the hands, feet, tibiæ, &c., the skin was rough, and resembled ichthyosis. Eyebrows, eyelids, and eyes normal. Ichthyosis of tongue. Œsophagus normal. Numerous small ulcers in stomach.

Geo. I—, aged 4, admitted August 16th, 1878. Four weeks before admission he broke the skin over his knee, which formed a sore which he constantly picked, and made worse in consequence. Two weeks ago another appeared on the right knee, and now vesicles in the mouth. Four days before admission a general eruption, which now consists of papules, vesicles, pustules, and scabs, came out on the abdomen chest, legs, and a few on the face.

August 23rd.—Sores due to confluent broken vesicles behind ears. The case is considered to be varicella.

29th.—The diagnosis is now altered to pemphigus gangrenosus.

September 17th.—Sores are now present over his head and round the corners of the mouth.

October 2nd.—Profuse suppuration from sores all over body. He gradually failed in strength, and died on October 16th with pneumonia, all the other viscera being healthy.

The case was considered by Dr. Pye-Smith to be one of pemphigus following varicella.

Mary G—, aged 72, under Dr. Pye-Smith in 1882. Carbuncle three years ago. Two months previous to admission she had red patches on the calves of her legs, which have continued more or less since; soon vesicles and bullæ formed and increased in number, so that the trunk and limbs were covered with them.

Post-mortem.—Body covered with large superficial scabs. The arms and legs had suffered most, but the trunk about the shoulder-blades was extensively affected. Lymph on both pleuræ. Granular kidneys. *February 5th*, 1889.

Digitized by Google

2. *A case of leprosy.* (*Card specimen.*)

By J. W. Washbourn, M.D.

R. S—, aged 22, billposter, was admitted into Guy's Hospital on July 30th, 1888, under the care of Dr. Wooldridge for leprosy.

Family history.—Father a soldier, died in India when patient was six months old. Mother living and well. No history of skin disease on either side. Brothers and sisters well.

Personal history.—Patient unmarried. Born in Galway. Spent first six years of his life in the East Indies, afterwards living in Ireland, London, and Folkestone.

History of present complaint.—The disease began eight years ago. Purple blotches appeared on the buttocks, the forehead became affected, and blisters rapidly appeared, leaving ulcers. The face became swollen, eyebrows and eyelashes disappeared, and tongue became affected. Voice first affected four or five years ago. Patient has been in Guy's Hospital four times under Dr. Moxon and Dr. Taylor. The last occasion was in February, 1887, under Dr. Taylor. There were then ulcers, tubercles, and patches of anæsthesia, the larynx was affected, and bacilli were found in scrapings from the ulcers.

Condition on admission.—Face swollen and covered with dry scaly tubercles, lips swollen and thick, nose flattened out. Front and back of trunk are covered with mottled patches of brownish tint. Hands are swollen, red, and œdematous. Terminal phalanges have disappeared. Ulcers on upper limbs. Legs swollen, tense, œdematous, and covered with ulcers. Voice hoarse. Larynx ulcerated and deformed. Heart, lungs, and urine normal.

Progress of case.—On the day after admission patient suffered from dyspnœa, and on following day this was so severe that tracheotomy was performed.

On August 2nd temp. 103°; the redness and swelling of hands, arms, feet, and legs had increased.

On the 7th the redness and swelling increased, and crops of vesicles appeared. Large sloughy sore appeared on left side of glans penis. Patient gradually became worse; there were at times

Digitized by Google

difficulties with the tracheotomy tube; the temperature varied from 101°—103°, but on August 13th became subnormal. Slight trace of albumen on August 14th.

Death took place on August 17th. No bacilli were found in scrapings from tubercles during patient's last stay in hospital.

Post-mortem.—Subcutaneous tissue of arms suppurating. Femoral-inguinal, iliac, and axillary glands suppurating. Right parotid full of pus. Ulnar nerve slightly enlarged. Tonsils and pillars of fauces covered with ulcers. Larynx (shown): Epiglottis swollen and ulcerated. Aryteno-epiglottidean folds, true and false cords swollen and ulcerated, and glottis contracted. Below tracheotomy wound the trachea is rough, covered with lymph, and partially filled with blood-clots. Under perichondrium of front of thyroid is an abscess communicating with tracheal wound. A few adhesions of right pleura; 10 oz. of clear fluid in left pleura, and 13 oz. in right. Lungs healthy. Pericardium slightly adherent over auricles. Heart normal. Pancreas large and hard. Liver 95 oz. Testicles show commencing abscesses; they are slightly fibroid. Other organs healthy.

Microscopical appearances.—Testes: Two collections of round-cells probably commencing abscesses. Otherwise organs healthy. Large number of bacilli in all parts. In the tubes they are especially numerous, and masses often completely block up the lumen. In the connective tissue around tubes, in the tunica albuginea, and in the collections of round-cells the bacilli are less numerous. In the arteries the bacilli are to be found in the intima as well as in the other coats. The bacilli are generally grouped in masses with frequently the so-called "vacuoles" suggestive of their being contained in cells, but I could in no case satisfy myself on this point. In some parts, on the other hand, the grouping was in rows, and there appeared good grounds for believing them to be in lymphatic spaces.

Ulnar nerve: Excess of round-cells in connective tissue around the funiculi. Within funiculi are dilated capillaries with excess of round-cells around them. Large numbers of bacilli found chiefly in funiculi, but also in connective tissue around. The nerve-fibres appear healthy. In transverse sections of nerve the bacilli appear grouped in rounded masses, but in longitudinal section many long rows of bacilli are found, and they appear to be contained within lymphatic spaces.

Digitized by Google

Skin: Only small piece was kept as most of it was suppurating. The bacilli few, and chiefly grouped round vessels. There was also an excess of round-cells.

Liver: Excess of round-cells in portal canals. Bacilli chiefly found in portal canals. Spleen healthy. Bacilli scattered in lymphoid tissue. Kidney healthy. Few bacilli found in glomeruli.

Larynx: Mucous membrane of aryteno-epiglottidean fold infiltrated with round-cells. Many bacilli amongst these.

Intestines: Few bacilli found in submucous tissue.

Pancreas, suprarenal, and thyroid, contain no bacilli.

May 21*st*, 1889.

Digitized by Google

X. SPECIAL COMMUNICATIONS.

Discussion on the Morbid Anatomy and Pathology of Chronic Alcoholism.—Introductory Address.

By Joseph Frank Payne, M.D.

Mr. President and Gentlemen,—When the Council of this Society did me the honour to ask me to open the discussion on this occasion, I accepted the task perhaps with a somewhat inadequate appreciation of the vast extent of the field which now lies opened out before me. It is only since I have been endeavouring, to the best of my ability, to prepare for the duty devolving upon me that I have thoroughly realised the multiplicity and variety of the facts which have to be dealt with, and the extreme difficulty of compressing them into a moderate compass.

I must therefore ask your indulgence while I appear before you, not in the character of an explorer bringing home the results of travel in new and untrodden ways, but rather in that of a geographer trying to sketch a rough outline map of a country hardly as yet completely explored or surveyed.

The extent of our country, however, though wide, is not unlimited. We are not going to discuss the action of drink on the human body generally, nor all the diseases to which habits of excess can give rise, nor, still less, the moral or economical consequences of such habits, but solely the material changes which the use of alcohol in excess has been actually shown to produce in various tissues and parts of the body.

Historical Introduction.

First period: Ancient medicine.—Before entering on the main topic, I will, however, ask your attention for a few minutes to some rough notes on the history of the subject. This begins in comparatively modern times, for ancient medicine knew almost

Digitized by Google

nothing of morbid anatomy. Doubtless, so long as wine has been known, so long has there also been known excess in wine; and among the Greeks even, more especially among the Romans, such excesses were neither rare nor harmless. Hence we find scattered notices in the ancient medical writers showing that the symptoms of inebriety were observed, and some graphic descriptions and some good clinical rules, founded on these observations, might be quoted; but, so far as I know, there is nothing in any ancient writer bearing on the morbid anatomy of the disease. This statement would be equally true of mediæval medicine, on which, therefore, we need not linger.

Second period: Rise of morbid anatomy.—It was not till the sixteenth century that morbid anatomy began a separate existence as a science, first under the protection of her elder sister, normal anatomy; gradually, in the seventeenth century, assuming a more independent position. But among the many excellent scattered observations on the structure of diseased organs, with which the medical literature of this century abounds, there are very few bearing on the action of wine or strong drinks.

As an instance of the most advanced knowledge of the age on such subjects, we might well quote our own Harvey, not only as a man of genius, but as a skilled physician well versed in all the learning of his time. In Harvey's MS. lectures, lately published in *facsimile*,[1] I have found nothing directly referring to inebriety, but there are certain observations which would naturally have led to this being spoken of had its importance been recognised. For instance, in speaking of the anatomy of the liver, he describes twelve different cases or examples of diseased liver which he had himself seen; one was "russet, hard, contracted, absque sanguine," which seems like a small cirrhotic liver. Another, according to the rough notes, was "russetish, ingentem et durum, plane scirrus tumour, absque fere sanguine, asperâ superficie;" a large, hard liver, evidently like a scirrhous tumour, almost bloodless, and with a rough surface, which could hardly have been anything else than cirrhosis. He also says that such livers are found in cases of dropsy (fol. 39). In another place he discusses dropsy generally, as being said by Fernelius to depend upon the liver, but himself inclined to the opinion that the dropsy is the cause

[1] 'Prælectiones Anatomiæ Universalis,' edited by a Committee of the Royal College of Physicians of London; London, Churchill, 1886.

Digitized by Google

of the morbid change in the liver rather than the converse. Dropsy may arise, Harvey says, by drinking more than the kidneys can get rid of, so at length even the fleshy parts are turned into water; but so long as any of the liver remains, the patient will live and not die.

This seems to bear upon our subject, but, really, I think it is founded upon the belief, common at that time, that dropsy could be caused by drinking too much water; a fault which consequently the bold spirits of the time were much on their guard against. Altogether these notes make one regret the loss of the observations on morbid anatomy which Harvey is said to have collected.

Harvey's MS was written in 1616. Not long after this some notices of alcoholic diseases begin to appear, but the only lesion referred to this cause by writers of the seventeenth century was cirrhosis of the liver, and its consequent ascites. The earliest case of this kind which I can find is of the date 1626, though published many years later in the great storehouse of such observations, Bonet's 'Sepulcretum' (Geneva, 1679), where it is quoted from Gregorius Horstius. A German nobleman, of intemperate habits, suffered for three years from jaundice, and was found to have the liver hardened, as was evident to the touch. He improved under treatment, but having "indulged his genius" for several weeks, he was attacked with epistaxis, followed by dropsy of the belly and scrotum. The latter was punctured, and two measures (? quarts) of fluid escaped, but the abdominal swelling did not diminish, and after some months he died suddenly. On opening the body ten measures of fluid were found in the abdomen. The liver is described as "scirrhosum et induratum, necnon exsuccum instar ligni putredine corrupti," that is, scirrhous, hardened, and juiceless, like rotten wood. The mesenteric veins were filled with gelatinous material surrounded by clotted blood, which could be pulled out to the length of an ell and a half.[1]

Surely this, as a clinical and pathological picture, could hardly be improved. A hard liver, jaundice, ascites, epistaxis, and sudden death with thrombosis of the portal system—scarcely any important feature is wanting.[2]

[1] 'Sepulcretum,' p. 1052.

[2] In the same case there is a very good description of xanthelasma in the form of tubercles on the knees and elbows, &c.

Digitized by Google

Several cases might be quoted from the same work, but I will only give one more.

A French soldier, returning from the wars in a thirsty mood, came upon a pool of stagnant water, where he first bathed, and of which he then drank a mighty draught (*haustus Germanicus*). This he took the first opportunity of correcting with abundant libations of strong wine, and the remedy was so often repeated that he fell into a severe fever, followed by dropsy of the abdomen and legs. The belly was tapped repeatedly, and in all 168 ounces of fluid were drawn off, of which the curious observation was made that, first and last, it always smelt like the stagnant pond-water of which the patient had so incautiously drunk. After death there was still some water in the peritoneum, and the liver was found as hard as wood.

In these cases and others strong wine was clearly recognised as the source of evil, but other causes were not excluded, as Bonet records the case of a boy who contracted fatal scirrhus of the liver and ascites by eating too many figs. Then there is another curious history of a certain glutton who ate as well as drank to excess, and whose liver was found after death of an enormous size—clearly an instance of the other type of alcoholic liver, the fatty, such as we might find now in a robust and plethoric brewer's drayman.

English medical literature of this period yields few valuable observations. One by Walter Harris, the correspondent and friend of Sydenham, author of a book on the diseases of children, and of 'Pharmacologia Antiempirica' (London, 1683), may be worth mentioning. In the work just mentioned he relates the case of a gentleman, aged thirty-six, who had brought himself to an insensible necessity of drinking sack several times a day until he fell into an irrecoverable consumption. On opening the body after death the liver was found "so thoroughly boiled with constant heat that a sound liver could not well be more boiled over the fire than his was by the use of sack. It was in colour and brittleness the very same as a long-boiled liver can be." Although dropsy is not named, probably it is meant that there was ascites also. Harris observes that sack does much more harm than French wines; and, though the reason he gives for this is a strange one, it shows that the causation of cirrhosis was beginning to be known.[1]

[1] James Hart, in his 'Diet of the Diseased' (1633), speaks of the use of strong waters producing "an irrecoverable scirrhus in the liver."

Digitized by Google

There is still one observation of dropsy connected with liver disease which I will venture to quote, although its dependence upon alcoholic drinks quite escaped the surgeon who has recorded it, one John Browne, surgeon to St. Thomas's Hospital. The account, which appears in the 'Philosophical Transactions,' vol. xv, 1685, is entitled: "A remarkable Account of a Liver, appearing Glandulous to the Eye," and is accompanied by a figure, "accurately taken down by Mr. Faithorn," an eminent artist and engraver of the day, which I have thought worth copying to show to the Society.

Woodcut 5.

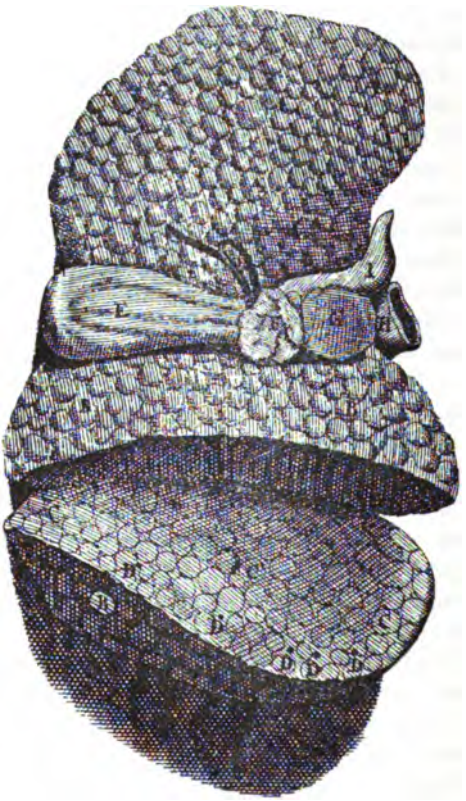

"The person was about twenty-five years of age, a soldier in one of His Majesty's regiments here in town, who contracted his

Digitized by Google

distemper by drinking much water, when he could not stirr from his duty, and catching cold at nights in being upon the guard. He was under the care of our physicians for some time, by whose directions his swellings did by times abate; but afterwards it was observed, that the method which had been beneficiall to others, had not here the like success, his swellings returned upon him as before, so that there was nothing more now to be thought of but a paracenthesis, which operation, however, is judged very hazardous, by reason of the time of the year, and for that the patient was very much emaciated; yet he being so much swelled, that it was uneasy to him to lie in his bed, he importuned us very often, and with great earnestness, that the operation might be performed. Whereupon, a paracenthesis by the physicians consent and directions was made by me, whereby we drew from the patient about three pints of brinish liquor, and within four days after as much more; the next day, morning, he dyes, and his death, as was found upon dissection, was partly occasioned by a mortification upon his scrotum and penis.

"This operation was performed to the satisfaction of the physicians and chirurgeons that saw it, and by it the patient had some ease for the present. Upon opening the body I believe I took out about twenty-four quarts of water; he had a large inflammation upon the peritonæum, all his other inward parts not much disaffected, except the liver. Its magnitude was not extraordinary, but seemed rather less than usual, but that which was very remarkable (and I think the like was scarce ever observed by any author) and seems much to confirm the opinion of the learned Malpighius, is this: It consisted in its concave, convex, and inward parts of glands which (with the vessels) made up one whole substance thereof; these glands contained a yellowish ichor, like so many pustulæ, and was I suppose part of the bilious humor lodged in the same, though otherwise the liver between the glands was of its usual reddish colour. In the bladder of gall we found a soft friable stone, but otherwise nothing considerable further in that part."

A private in the Guards is hardly likely to have acquired dropsy by drinking water, and there can, I think, be little doubt that the so-called "glandular structures" were the ordinary soft bile-stained masses, separated by fibrous tissue, which we find in cirrhosis of the liver. And the figure, allowing that it is drawn in a formal

Digitized by Google

and conventional manner, appears to me to represent the same. This, however, is left to the judgment of the Society; but as being, if I am right, the first published figure of cirrhosis of the liver, it has some historical interest.

Third period: Use of distilled spirits.—We have seen what the seventeenth century contributed to the morbid anatomy of alcoholism. A new period was now about to begin, that in which distilled spirits came into use as a beverage. With this, new and more severe kinds of alcoholic disease began to appear,

> macies et nova febrium
> Terris incubuit cohors,

and, but for this disastrous invention, I am convinced that our programme for discussion to-night would be very much shorter than it is.

It was at the beginning of the eighteenth century that distilled spirits began to be generally drunk. The art of distillation, of course, was very much older, and was practised in London at least in the sixteenth century, if not earlier; but, up to the time now spoken of, distilled spirits were chiefly used in medicine, and were for a long time very costly. Towards the end of the seventeenth century they became much cheaper, so that in 1678 a pint of Nantes brandy cost about sixpence. When the use of such drinks became common I do not know, but in 1724 we find the College of Physicians making a public representation as to the evils of spirit drinking. At this time gin was so cheap in London that a person could intoxicate himself for one penny. A duty was imposed in 1736, and other laws made to check the practice of spirit drinking. The name of the Rev. Stephen Hales, the physiologist, ought to be mentioned in a medical discussion for his efforts in this cause. It is also clear that alcoholic diseases increased, and were more observed by the medical profession, but the morbid anatomy of the subject was little advanced, at least in England, till the end of the eighteenth century. Erasmus Darwin made some good observations on the symptoms of drunkenness, but has only contributed to morbid anatomy the statement that pigs fed on grains from distillers get diseased livers.

Baillie described cirrhosis under the name of tubercles of the liver, and declared it to be a disease *sui generis*, different from scirrhus.

Digitized by Google

J. C. Lettsom, in 1786,[1] first described the symptoms of alcoholic paralysis, and James Jackson, of Boston, America, gave, in 1822, a very good account of a disease resulting from the use of ardent spirits, which he calls arthrodynia, which is evidently the same.

All the knowledge of this period is summed up in the classical work of Magnus Huss on 'Alcoholismus Chronicus,' translated from Swedish into German in 1852. Huss describes very carefully the morbid changes of all parts of the body met with in drunkards; but, with regard to the nervous system, it is noteworthy that he regarded the disturbances of these parts as being unaccompanied by any change in structure, and hence as being symptoms of a certain kind of poisoning. It is to these that he applied the name, then used for the first time, of chronic alcoholism, and some of his descriptions have left little to be added to.

Fourth period: Era of pathological histology.—The most conspicuous advance on the subject since the work of Huss has been the demonstration of minute changes in various parts of the nervous system affected by alcoholic disease. At the same time the histology of other organs has been studied, the identity of the minute changes found in different parts has been demonstrated, and gradually the uniformity of the action of alcohol throughout the whole body has become clearly manifest. We are now able to look upon alcoholism as a form of poisoning, and to compare it with the action of other poisons, especially with metallic and other so-called irritants. The general history of alcoholism must come to an end here, for it would be difficult to separate it from the exposition of different branches of the subject.

Alcohol as a Poison.

I have now to consider the question, In what sense is alcoholism a poisoning; or, in other words, in what sense is alcohol a poison?

Since we must here evidently look upon poisons in a somewhat wider sense than a purely medico-legal one, perhaps I may be permitted to quote a pathological definition of poisons which I have given elsewhere:[2]—"A poison is a substance capable of

[1] J. C. Lettsom, "Some Remarks on the Effects of Lignum Quassiæ Amaræ," read April 3rd, 1786 ('Memoirs of Medical Society of London,' vol. i, p. 128); also reprinted in a tract, 'History of Some of the Effects of Hard Drinking,' London, 1791, 4to.

[2] 'A Manual of General Pathology,' p. 378.

Digitized by Google

injuring the body, either by causing damage to the tissues or by producing functional disturbance." On this basis I divide them into two classes, namely, tissue-poisons and functional poisons. I will take the latter first. A functional poison disturbs the mode of action of the tissue elements without permanently altering their composition. Hence its action is transitory, and ceases when it is eliminated from the body. Most functional poisons are called narcotic or neurotic, because their most conspicuous action is on the nervous system. But some such poisons—for instance, opium—affect animals without a nervous system, and possibly even plants, so that their action is general. Substances like quinine, which affect protoplasm, though without showing any special predilection for the nervous system, and hence sometimes called protoplasmic poisons, are also included.

Tissue-poisons, on the other hand, are such as damage or destroy the structure of tissue elements. This class includes all the so-called corrosive and irritant poisons, but is wider since it includes also substances of which the destructive action is not generally recognised. Tissue poisons will, for obvious reasons, also produce functional disturbance, even when acting feebly, or in a small dose; that is to say, they are also functional poisons. It is important to remember that they produce secondary effects on distant parts beside the primary effect on the part of the body to which they are first applied. These secondary effects are the same by whatever channel the poison may have been absorbed, and are produced by direct contact of the poison contained in the blood with the affected organs. Hence their intensity is proportional to the degree of concentration in which the poison exists in the blood.

At this point it may be worth while to say that I do not use the term poison as a term of unqualified condemnation. It only means something capable of producing injury, not necessarily doing so. All metallic salts, nearly all drugs, and many substances used as food are in this sense poisons; though we do not on that account deny their usefulness when properly employed. It would be as absurd to condemn alcohol as to condemn common table salt because a large dose of either of them may be fatal. But to pursue this subject further might lead one on to dangerous ground; I return, therefore, to the old track.

It is quite clear that alcohol is a functional poison of the nar-

Digitized by Google

cotic class. Its action on the brain shows the gradations of stimulation, overaction, inhibited action, and actual narcosis. These effects, unless positively fatal, are transitory. But it is also clear that this is not the whole of its injurious effect; since, if the functional disturbance be often repeated, the brain itself will come in the end to be damaged. It may be supposed this damage is caused by the excess or repetition of the functional disturbance. Such an explanation will not, however, apply universally, since some organs, such as peripheral nerves, are damaged, in which no functional disturbance from the immediate action of alcohol can be traced. Hence we conclude that alcohol is also a tissue poison which damages the structure of the tissue elements. This effect is not seen after a single dose, even a fatal dose, at least so far as is known, but only after repeated action of the poison. When its action is perceptible it is quite comparable to that of the so-called irritant poisons, especially the metallic, such as lead, arsenic, antimony, &c., with phosphorus, and even mineral acids. It is now recognised that these substances, if absorbed, act on all or most tissues of the body which they reach in proportion to the degree of concentration in which they may be present, and to the susceptibility of the different parts. This is also true of alcohol. It is carried by the blood to all parts (having been detected in the brain and various organs), and acts in the first instance most powerfully on the parts which it reaches with the least amount of dilution, that is, the stomach and liver. In the second place, it specially attacks the nervous tissues as being more vulnerable than the rest. Moreover, the influence of concentration in relation to the tissue damage is further seen in the fact that alcohol in a dilute form injures the tissues much less than the same amount in a concentrated form, though the narcotic effect may be the same.

Another law of tissue poisons is that they all have, within certain limits, the same action, or at least there are certain modes of action common to all. These common modes of action belonging to all tissue poisons I will endeavour to state, and then see whether alcohol acts in the same way.

The first effect of such poisons is seen on the more vulnerable or parenchymatous elements, namely, nerve, epithelium, muscle-fibre. On these parts their action is essentially necrotic, producing, if in a low degree, parenchymatous degeneration; in a higher degree, actual necrosis, though if the injury be not too severe, repair is

Digitized by Google

possible. This is true of arsenic, antimony, sulphuric acid, and with some modification, of phosphorus. I would submit that this is also true of alcohol, which produces degeneration, or ultimately necrosis, of mucous membrane of stomach, liver-cells, nerve-fibres, nerve-cells, and muscular fibres.

Another effect of all tissue poisons, if sufficiently concentrated, is to injure the blood-vessels, causing exudation and cell migration —that is, inflammation as generally understood. It is obvious that this is true of all irritant poisons. If chronic, this inflammation sometimes results in hyperplasia of connective tissue. I submit that concentrated alcohol acts on the stomach, for instance, to which it is directly applied, in the same way: setting up acute inflammation. The action of alcohol, however, is not so intense as that of some metallic poisons, since it never produces suppuration, nor has it an actually corrosive action. Its continuous or chronic action is to produce connective-tissue hyperplasia, fibroid changes, or cirrhosis.

Besides these two modes of action, alcohol has one almost peculiar to itself: that of causing accumulation or infiltration of fat in various parts of the body, especially where such accumulation naturally takes place, as in liver, omentum, subcutaneous tissue. Phosphorus is like alcohol in this respect, and so is, to some extent, arsenic. This change may be called "steatosis." It is explained, apparently with reason, as due to deficient oxidation or impeded cell-respiration, the alcohol or phosphorus being oxidised in place of the fat which should be burnt up in the cell. I would ask, are there any objections to this explanation?

I would suggest the relations of fatty infiltration to true fatty degeneration as an interesting though difficult subject of inquiry and discussion. The difference in well-marked conditions is obvious. A liver-cell or connective-tissue cell loaded with fat may be healthy, while a fattily degenerated cell is one of which the protoplasm is already altered in structure. But is it not possible that accumulation of fat may destroy the cell in the end, and thus pass into degeneration? If the respiration of a cell is sufficiently impeded, will the cell die as an individual does under the same circumstances? The question is particularly interesting here, because alcohol appears to cause true fatty degeneration of some parts, as well as mere adipose accumulation in others. But the latter action, since it may aid in nutrition, can hardly be called poisonous. To sum up.

Digitized by Google

The action of alcohol on tissues or tissue elements is threefold: (1) as a functional poison; (2) as a tissue-poison or destructive; (3) as a checker of oxidation; and in these respects it may be paralleled by other substances called poisons, as well as by others which are generally considered innocuous. These views of the action of alcohol are put forward with the object of inviting criticism or correction. It is very probable that they may be in some respects one-sided or faulty.

I had intended to give some account of the morbid changes produced by administering alcohol to animals, but find that time will not permit.

Morbid Changes Produced by Alcohol in Various Organs.

Since it is obviously impossible to speak of all the organs which may be altered, I shall confine my remarks to a few, especially the liver and the nervous system, taking the morbid changes in these parts as types of the effects produced in the organs generally.

Effects of alcoholism as seen in the liver.—It is generally recognised that one effect of alcohol is to produce accumulation of fat or steatosis in the liver. This change is produced especially by dilute forms of alcohol, and in those who are well fed. The explanation has already been suggested. Only one question occurs to me respecting this condition: Does it ever pass into cirrhosis? Are there not large livers, with a large amount of fat, which show commencing cirrhosis? Or does the fatty change in some way shield the liver tissues from the more serious and irritative action of the spirit? The accumulation of fat is, so far as it goes, evidence of the destruction of some alcohol, if the explanation given above be correct.

Cirrhosis of the liver.—It would seem as if no pathological process were better known or explained in a more satisfactory way than this. It is generally accepted that concentrated forms of alcoholic drinks, brought into the stomach, are absorbed into the portal vein, and carried to the liver, where inflammation of the interstitial stroma is set up, by which new fibrous tissue is produced. In consequence of the pressure of this tissue, and its subsequent contraction, the liver-cells are compressed and destroyed, and are found in various degrees of degeneration loaded with fat, yellow granules, and so on.

To this explanation I am inclined to demur. I would ask, Is a

Digitized by Google

liver ever found with healthy hepatic cells and an inflamed stroma? In the very earliest stages of cirrhosis are not the cells decidedly degenerated? Is it not more reasonable to suppose that the injurious action of alcohol is exerted simultaneously on both parts of the organ; and that, if so, the parenchymatous elements, being more vulnerable than connective tissue, would suffer first? Dr. Lionel Beale, indeed, urged some years ago that the change is essentially atrophic, not inflammatory.

I am also led to raise this question by consideration of a certain very rare form of degeneration of the liver, which is really, I think, produced by alcohol; though the connection has not been recognised. I mean that called in England acute red atrophy. (In Germany the name "red atrophy" is often given to what we call the nutmeg liver.) It is generally admitted to be nearly allied to the acute yellow atrophy, but differs from it in other respects besides colour. The organ is much reduced in size; the liver-cells, as in yellow atrophy, show advanced degeneration and necrosis. Other parts of the organ are of a deep red colour, with little or no liver tissue, and consist chiefly of connective tissue and capillaries deeply engorged, inflamed with infiltration of leucocytes, and showing new formation of fibrous tissue. This short description, founded on a paper by Dr. Moxon in our 'Transactions,' and on the only case which I have seen, proves, I think, that the same changes which cirrhosis shows in a chronic form are here displayed in an acute form. The connection with alcohol is perfectly clear, though it was not brought out by Dr. Moxon, nor has it been insisted on in the other cases brought before the Society. We have three cases in all; Dr. Moxon's (vol. xxiii), where two brandy bottles were found under the patient's pillow; Dr. Cayley's (vol. xxxiv), in a drinker of spirits; and Dr. Carrington's (vol. xxxvi), which occurred after hard drinking for six weeks. The last I had the opportunity of examining as a member of the Morbid Growths Committee, which gave it the same name as I have done. Dr. Cayley, indeed, suggested that the atrophic process supervened on a chronic cirrhosis; but, taking the three cases together, it would seem that the parenchymatous and interstitial parts of the organ were concurrently affected; the former undergoing, as the usual law is, atrophy and necrosis; the latter showing ordinary inflammation. But if there was any difference in order of time, the parenchyma would be likely to suffer first. I suggest the same

Digitized by Google

explanation for common cirrhosis, and shall return to the same point in speaking of the nervous system.

Another question of interest bearing on cirrhosis is why is it so comparatively rarely found in the bodies of drunkards? Peters found it in four or five cases only out of seventy persons who died from the excessive use of ardent spirits. What other factor is concurrent with alcohol in producing it? Is it ever set up by the action of any liquors other than distilled spirits or strong wine, such as sherry?

Acute yellow atrophy.—This remarkable disease, somewhat less rare than what I have called red atrophy, is sometimes connected with alcoholic excess, but since it is also found to occur independently of this condition, alcohol can hardly be regarded as more than a favouring cause.

Effects of Alcohol on the Nervous System.

Although the functional disturbances produced by alcohol on the brain are the most familiar evidence of its action, and, when excessive, have long been recognised as the most deleterious of its results, the actual textural changes produced by it have only been demonstrated in comparatively recent times.

The demonstration of organic changes in the nervous system began, as was natural, with the brain, and with observation of alterations visible to the naked eye. I will first speak of changes in the meninges.

The dura mater has been very frequently observed to be thickened, and the Pacchionian bodies largely developed. Vascular congestion has been frequently described, but the conditions immediately preceding death and the manner in which the necropsy is made influence so decidedly the amount of blood contained in this part that the observation has not any very great value. More rarely a special change of the dura mater has been described —namely, chronic pachymeningitis, sometimes in the form of the so-called pachymeningitis hæmorrhagica, or hæmatoma of the dura mater. This curious condition has been explained by Virchow as produced by a combination of exudative inflammation with hæmorrhage. It is certainly sometimes connected with atrophy of the brain. This is among the rarer results of alcoholic poisoning, though it is described by Lancereaux, Greenfield,[1] Magnan, and others as occur-

[1] 'Path. Trans.,' vol. xxix, pl. i. The specimen is in the museum of St. Thomas's Hospital.

Digitized by Google

ring in cases of chronic alcoholism and delirium tremens, and is also found in chronic dementia and other cases in asylums. Without discussing fully the origin of this condition, I will only say that hæmorrhage into the arachnoid cavity is certainly the most important factor, and capable alone of producing the appearances in question, as is shown by such cases as that recorded by Dr. J. W. Ogle, where the immediate cause was injury in an alcoholic person.[1] Hæmorrhagic pachymeningitis has also been produced artificially in dogs by poisoning them with alcohol in even as short a time as four weeks.[2]

The visceral arachnoid and pia mater must necessarily, for purposes of pathology, be considered together. Thickening and opacity are the most constant changes observed, but in certain cases there is much vascular congestion, with small patches of ecchymosis. But the most frequent appearance in the subarachnoid spaces, as well as in the arachnoid cavity, and to a certain extent in the internal cavities of the brain, is excess of serum. This is so marked that those accustomed to *post-mortem* examinations would generally say that a drunkard's brain is a wet brain.

Now, it is hardly necessary to point out that a similar condition is very generally met with in the brains of old persons; it is a senile condition. And both in chronic alcoholism and in old age the cause of this accumulation of fluid is the same; namely, it comes from atrophy of the brain-substance. The convolutions look small, the sulci deep, and in most cases the pia mater is easily removed.

If it be granted that atrophy of the brain is at least a common result of alcoholism, though not a distinctive one, it yet remains for consideration what the nature of the wasting process is, whether one of simple atrophy, or some special form of degeneration leading to diminution of size.

The answer to this appears to be that there is no special kind of degeneration. The nerve-cells are sometimes said to be granular, but in general no change is described as at all characteristic of alcoholism. Some observers go so far as to say that the cortical grey matter is very little affected; and one (Wille) refers the de-

[1] Ogle, 'Path. Trans.,' vol. vi, p. 5; also Prescott Hewett, same vol., p. 10.

[2] Kremiansky and others, quoted in Magnan's 'Alcoholism,' p. 15.

Digitized by Google

generative changes almost entirely to the medullary substance. On these points we hope for information from those who have made cerebral pathology a special study.

In a few instances, however, more pronounced changes are met with in the cerebral cortex. The pia mater is adherent to the convolutions, portions of the grey matter being torn off with it. On microscopical examination, patches of degeneration and sclerosis are seen. The inner surface of the ventricles again presents a rough and granular appearance; sometimes with fibrous outgrowths. These are in fact the lesions found in the brain in cases of general paralysis or paralytic dementia.

The relation of chronic alcoholism to general paralysis is a difficult and abstruse question, on which different opinions have been expressed by different observers among those who have had large experience in such diseases. It is only in special practice or special institutions that such experience can be obtained. What I venture to say on this subject is therefore said rather in the way of suggestion.

That so-called general paralysis or paralytic dementia, not now a very uncommon disease, often has for one of its factors excessive indulgence in alcohol can hardly be disputed. But if I take, on the one hand, the statistics of general paralysis, I do not find any very large proportion of cases regarded as solely or mainly due to this cause, nor, on the other hand, among the sequelæ or final stages of chronic alcoholism, does general paralysis occupy a conspicuous place. The conclusion seems to be that general paralysis is distinct from chronic alcoholism, and that for the production of the former out of the latter some additional cause is necessary.

Such a cause I believe to be excessive functional strain. The three chief factors of general paralysis are alcohol, functional strain, and in many cases, congenital incapacity to bear strain; in short, a disproportion between functional activity and power of resistance, especially in the higher cortical centres and the tracts connected with them. I emphasise this suggestion because it appears to confirm the conclusion arrived at on other grounds, that the effects of alcohol on the nervous system, and even on the brain, are independent of its functional effect on the nerve-cells, but are those of a tissue poison, acting directly on the protoplasm of various parts. At the same time it remains rather difficult to

Digitized by Google

understand why alcohol so seldom produces inflammation or sclerosis in the brain, the organ which is most susceptible to its physiological effects.

The general subject of the relation of general paralysis to alcoholism is one on which I hope we may receive more information from those whose field of observation in asylums has included many cases of each disease.

Changes in the spinal cord.—I now pass to the changes produced by, or ascribed to, alcohol in the spinal cord. These are not numerous or frequently observed. Before the period of microscopical examination, the spinal cord was universally said to be healthy in necropsies of alcoholic persons. Of late years a few cases have been recorded in which there was sclerosis, or degeneration of certain tracts, especially the posterior columns, or posterior part of the lateral columns (Magnan).

When attention was drawn to the occurrence of paralysis, especially in the form of paraplegia, in chronic alcoholism, it was thought naturally that this would be due to disease of the spinal cord, but subsequent research has not quite confirmed this expectation. More constant morbid changes have been found in nerves. Nevertheless, in a certain number of cases, alterations have been detected in both. When the alcoholism has passed into paralytic dementia, changes in the cord have been found accompanying the changes before described in the brain. At the same time we have cases (I speak from my own experience) of what is thought to be acute myelitis due to excessive drinking. Are there any records of *post-mortem* appearances in such cases?

Changes in the peripheral nerves.—Although the actual changes produced by alcohol in the nerves have only lately been observed, the symptoms now referred to them have been longer known, though referred originally to a lesion of the spinal cord. Dr. Wilks was, I think, the first in this country, or elsewhere, to give a full and clear description of these symptoms under the name of "alcoholic paraplegia."[1]

Here I must venture to depart a little from the plan laid down, and say a word or two about the clinical aspect of the nervous disease, especially as it is as yet not universally recognised by the profession.

[1] "Lectures on Diseases of the Nervous System," in 'Medical Times and Gazette,' 1868, vol. ii, p. 470; 'Lancet,' March 9th, 1872.

Digitized by Google

The earliest symptoms are disturbances of sensation, and, in the first place, hyperæsthesia. There may be peculiar sensation (paræsthesia), such as numbness, tingling, or feeling of pins and needles, or burning, and sensations of boring and stretching. There may be actual pain, but it is not usually continuous. Later on, all these disturbances give place to anæsthesia, which is often observed to be present in particular areas. Difficulty in locating sensation and retardation in the transmission of sensation have also been described. All these symptoms are evidently referable to cutaneous nerves, but the deeper nerve-trunks and muscles are often tender on pressure. The special senses are very rarely affected. If we consider the phenomena relating to muscles, we find that a very prominent symptom, and usually an early one, though sometimes absent, is inco-ordination and loss of muscular sense. The knee-jerk is lost at an early stage, and Dr. Gowers refers this phenomenon, apparently with justice, to loss of the muscular sense.

All these phenomena constitute the condition of alcoholic ataxia, which may come on before there is actual paralysis of motion, and may remain, as I can state from personal observation, when actual paralysis, once present, has passed away, though it is probably always accompanied by muscular weakness. It is distinguished from tabes dorsalis, or what is called locomotor ataxia, by several characters, especially by absence of all symptoms connected with the pupil of the eye or with the sphincters. Next, if the affection continue and become more severe, we have the stage of actual motor paralysis. In this there will be entire loss of motor power in the muscles, sometimes quite local, sometimes in all four limbs. The paralysed muscles soon lose faradic irritability, and become impaired in galvanic irritability.

Now, I think it is quite clear that the symptoms, of which the above is a bare outline, might be referred to injury of peripheral nerves.

Take first the case of the cutaneous nerves, the function of which is mainly efferent or sensory. The first result of slight injury to a nervous structure, if it do not pass a certain degree of intensity, is to cause its substance to be more easily decomposed —that is, to produce an apparent, or at least temporary, exaltation of function, which, in a sensory organ, is expressed as hyperæsthesia. A continuance or higher degree of the same injury will

Digitized by Google

produce total loss of conducting power or anæsthesia. Whether this injury affects nerve-endings or nerve-trunks, or both, is a question not yet entirely decided. It is evident that paræsthesia or irregular sensations may also result from injury to sensory nerves.

Now let us consider the case of the muscular nerves (a term which I prefer to that of motor nerves, at least for the present purpose). These nerves have a twofold conducting power: one efferent, transmitting motor impulses; another afferent, transmitting the muscular sense. The sensory or afferent function is assigned to special fibres, which are said to have a special origin. This statement my knowledge is quite inadequate to enable me either to confirm or reject; but for the present purpose it is enough to assume that there are fibres having this function. It would seem as if these fibres were affected by a slighter form of injury than that which is necessary to cause actual motor paralysis. At all events, an injury of these fibres would produce all the symptoms of ataxia, and an injury of the efferent motor fibres would cause paralysis.

Certain other symptoms, which sometimes complicate alcoholic paralysis, are explainable by similar injury of other nerves. One is acceleration of the pulse. This is very notable in many cases. In one of my own, which ended in recovery, the pulse was for a long time not less than 140, independently of occasional fever, and still more rapid pulses have been observed. In a case of a confirmed drinker, whose pulse was usually about 180, and who died of thrombosis of the portal and mesenteric veins, with hardened liver, I found after death nothing to account for the rapid action of the heart. It is clear that a slight degree of injury to the vagus nerve would, in the absence of other causes, be sufficient to account for this acceleration of the heart; but when this observation was made the connection was not thought of.[1] Paralysis of the diaphragm, from affection of the phrenic nerve, may also occur.

It would not be enough to show that nerve changes would account for these symptoms. It must be shown that no other cause accounts for them, and that the supposed nerve changes actually exist. The only other conceivable cause of all the symptoms described would

[1] 'Path. Trans.,' vol. xxi, p. 228.

Digitized by Google

be an extensive lesion of the spinal cord, affecting both motor and sensory tracts. Such a lesion is not known to occur in these cases, and has in many cases been proved not to be present. Moreover, the supposed nerve lesions have been, in many instances, found in the mixed nerves, including both cutaneous and muscle-nerves. In one instance, at least, similar changes have been detected by Finlay in the trunk of the vagus when the pulse was 160.

It is to Lancereaux that the credit belongs both of suggesting peripheral neuritis as the explanation of alcoholic paralysis and of establishing its truth.

I will not take up the time of the Society or anticipate the remarks of those who are to follow, and are more competent than I am to speak on this matter, by quoting observations of peripheral neuritis in cases of alcoholic paralysis; but I will refer to those published by Lancereaux, Reginald Thompson, Buzzard, Dreschfeld, Duckworth, Finlay, and others in various publications. More especially in the 'Transactions' of our own Society Dr. Hadden (vols. xxxvi and xxxviii), Dr. Hale White (vol. xxxvii) and Dr. Sharkey (this year) have described specimens having the same significance. I will only venture to speak of one point in the pathology of what is called neuritis, and this has reference also to other forms of the same lesion, such as the diphtheritic and the various toxic forms.

The changes described in the nerves thus affected come under the heads parenchymatous and interstitial. The first include cloudy or granular appearance of the nerve-fibres, segmentation of the myeline and collection of it in round and oval masses, sometimes absence of the axis-cylinder, and other similar changes; in fact all the evidence of degeneration, ending in necrosis.

The interstitial changes are seen in the perineurium or endoneurium, either diffused, or mainly external. These tissues may show an increase in the number of nuclei, or infiltration with leucocytes, and are generally thickened. In some cases actual increase of connective tissue has been described. These changes are what are usually described as inflammation leading to hyperplasia.

Very generally, both these changes are found together, but sometimes one group of changes predominates, sometimes the other; and thus the lesion is sometimes described as degeneration, sometimes as inflammation, and there has been a sort of controversy

Digitized by Google

as to by which name it should be called, and which should be regarded as the original or primary change. I would submit that the parenchymatous and interstitial lesions are both produced by the direct action of alcohol, and illustrate the general law that when a toxic or injurious agent affects a mixed organ of the body, it is likely to produce degeneration or necrosis of the parenchymatous elements (nerve, muscle-fibre, epithelium), and what is generally called inflammation (either of the constructive or suppurative form) in the connective tissue, just as in the liver. This does not exclude the possibility of there being a parenchymatous neuritis, such as has been observed in experiments on animals by Ranvier and others; in which there would be formation of new nerve-fibres. But as the nerves have never been removed during life from cases recovering, but only after death from fatal cases, in which there was presumably no repair, the nerve-fibres show pure degeneration or necrosis.

It is also to be remembered that the change found in certain parts of the nerves may be a secondary degeneration, caused by interruption of the nervous currents by lesion of the nerve at another point. But when interstitial change and nerve degeneration are present, it is not necessary to suppose that the nerve-fibres suffer secondarily, being compressed by the hyperplastic connective-tissue. On the contrary, there are instances in which the nerve degeneration must be the primary change, and the connective tissue change a consequence of it. For instance, this must be the case in the so-called secondary degeneration of conducting tracts in the spinal cord or nerves, in consequence of injury to the ganglionic tissue with which they are connected. It is clear that the break of communication will at first affect only the nerve-fibres, and not the connective tissue surrounding them. Changes in this tissue, that is to say, sclerosis, perineuritis, or interstitial neuritis, must therefore be a consequence of the nerve atrophy. How this leads to connective-tissue proliferation is a difficult question. But I have elsewhere attempted to show that it may be partly a consequence of the diminished resistance which favours overgrowth of the tissue which remains; and secondly, that when the nerve-fibres are dead, the connective tissue deals with them as with a foreign body. It tends to form a barrier of fibrous tissue around them as if to encapsulate them.

In ordinary neuritis we could only prove which was the initial

Digitized by Google

stage of the disease by examining specimens at different stages, which has not been done, so far as I know. Hence, since we do not know the necessary order of the changes, it is more reasonable, on the whole, to regard them as simultaneous results of the action of alcohol, and to speak of the whole process as alcoholic neuritis.

I can only just allude to the remarkable fact that similar nerve changes have been demonstrated in chronic arsenic-poisoning, in lead-poisoning, in paralysis from bisulphide of carbon, and in the disease called kakké, while there is great reason to think that the nerve changes of diphtheria and other specific diseases are due to the same morbid process. All these will be forms of multiple peripheral neuritis.

Changes in other organs.—I have chosen the liver and the nervous system as typical instances of the injurious effects of alcohol on tissues; and there would be no time to speak of other organs in the same way. I can only, therefore, briefly mention what appear to be the most important points.

With regard to diseases of the kidney, one cannot but feel that the connection of different forms of Bright's disease with drinking requires further elucidation. The general belief in the profession certainly is, or was, that drinking to excess is a rather frequent cause of this disease. But Dr. Dickinson's observations and statistics tell so strongly against this view that further observations are needed if it is to be maintained.

The relation of alcoholism to diseases of the generative organs is a very interesting though little studied subject. One of the oldest beliefs respecting the effects of excessive drinking is that such habits diminish fertility in both sexes, but especially in the male. The Rev. Stephen Hales, in the eighteenth century, even sought to show that the natural increase of the population of London was seriously lessened by the use of distilled spirits. The number of christenings (taken as corresponding to births) in London fell off from 19,370 in 1724 to an average of 14,320 in the three years preceding 1750. Whether these statistics rest on a sound basis I cannot say, but statements to the same effect have often been made. It is also stated that procreation, when one or both parents are inebriated, results in the birth of idiotic or deformed children, and Dr. Langdon Down has brought some such cases before the Society. It has never been shown whether this depends on any organic change in the testicles or the semen, or on the temporary in-

Digitized by Google

ebriation. A few observations have been made on the condition of the male generative organs by Lancereaux and others. Corresponding conditions in the female sex would, there is every reason to believe, be equally injurious to the offspring. Little positive information has, however, been collected as to the state of the generative organs in female drinkers. Dr. Matthews Duncan's able paper on this subject in the 'Edinburgh Medical Journal,' April, 1888, probably contains all that there is at present to say.

The organs of respiration appear, from clinical observation, to be affected by alcoholism. Certainly we often meet with laryngeal and bronchial catarrhs which are chronic and obstinate, and with great probability referred to the direct action of alcohol. In connection with this it may be worth while to recall the fact that alcohol is actually excreted by the lungs, probably partly in an oxidised state, and may therefore have a directly toxic action. Further, arsenic, if given in long courses, seems to have a tendency to produce bronchial catarrh; and cantharidine injected experimentally under the skin of rabbits has produced acute laryngitis. *Post-mortem* observations have shown nothing definite on this point.

With regard to the influence of alcohol on the production of tubercle, the utmost divergence, and indeed contradictory opposition, of opinion prevails. Huss found tubercular phthisis to be rare in drunkards, and that has been the general conclusion drawn from *post-mortem* observations. It has even been thought that drinking freely checks the progress of phthisis, but of this I can find little evidence. On the other hand, the more general impression is that alcoholism is a frequent cause of consumption. On this disputed point we must appeal to the methodised experience of those who have special opportunities of observation. The only new fact in the discussion is, I think, the undoubted frequency of tubercular disease in the subjects of alcoholic paralysis.

Passing over many important and interesting subjects, I will only say a word or two on the relation of chronic alcoholism to the skin. Most of us are familiar with the kind of skin generally associated with advanced alcoholism—soft, smooth, satiny, generally pale, and sometimes waxy looking. It appears to depend partly upon accumulation of adipose tissue under the skin, partly, perhaps, upon wasting of the skin itself, or of the epidermis. It is very

Digitized by Google

much like the senile condition of skin. It is stated by Lancereaux to accompany fatty degeneration of the liver, or rather steatosis. I am sorry, however, I have no specimens of skin from alcoholic subjects. The association of chronic hyperæmia of the nose or other parts of the face, and of acne rosacea, with drinking habits, is too well known to need mention, except the expression of a hint that the frequency of such association has been exaggerated. There is only one other skin affection, so far as I know, which has been definitely attributed to the effects of drinking. It is a peculiar brown pigmentation, mottled and variegated, which has been described as occurring in alcoholic persons. It is singular that we had one case at St. Thomas's Hospital of a patient dying of cirrhosis of the liver combined with tuberculosis, in whom a piebald mottled appearance is described as having been present on the genitals. It appeared from the description to have been like the so-called leucoderma, consisting of white patches in the midst of skin showing excess of pigment; but it would be premature, I think, to conclude from a few coincidences that it was produced by alcoholism, since a similar condition certainly often arises without any such cause.

Eczema, psoriasis, and various other diseases have been ascribed, with little ground, to the effects of drinking. The only fact I believe to be established is that drinking habits make such diseases inveterate, and sometimes quite incurable. I have seen eczema in an alcoholic subject pass into general exfoliative dermatitis, on which treatment made absolutely no impression.

But time warns me, and I conclude, to make way for those members who are, I doubt not, going to bring before us facts and materials which will, we may hope, materially advance our knowledge of this difficult and important subject.

The *President*.—I need not ask you, gentlemen, if you will return your thanks to Dr. Payne for the paper he has communicated. You have already expressed your pleasure with it, and have, I am sure, all appreciated very keenly the information that he has given us, and I hope that a discussion will follow quite worthy of the paper.

Dr. George Harley, F.R.S.—Mr. President, in addition to your congratulatory words upon Dr. Payne's paper, I am sure I may say that everyone here feels, after listening to the paper, that you

Digitized by Google

ndividually and the Council collectively have done well to bring the subject of chronic alcoholism before us this evening. I for one have received from it not only a great deal of pleasure, but also an immense amount of instruction, and I think those gentlemen who have paid attention to alcoholism will agree with me that Dr. Payne has collated his materials in an admirable manner. Besides this, I am delighted to find some instructive microscopic specimens in the other room, which, if it had not been for this discussion, I do not think we should have had the opportunity of seeing. Now, as we are here this evening in order to get information from each other, and the more fresh ideas we can give to each other the better. I will not take up the time of the Society by following the same course Dr. Payne has done, instructive though it be. For, as human brains are like human faces, although possessing a general similarity, each one has its own peculiarity, no two men can think exactly alike on the same subject, I think I shall do better if I strike out into an entirely different line of thought.

No doubt, as Dr. Payne has said, though the morbid anatomy of alcoholic poisoning has been known to us for a very long time, and the histological part of it has been ably treated of during the last thirty years, we have still not yet discovered the cause of the alcohol's action upon the body. The Pathological Society not being a mere morbid anatomy society, we have not merely to exhibit specimens, but to try and trace the causes of disease in order to assist our medical brethren in their treatment, I think I may say that when we talk of morbid changes in tissue—cirrhotic livers, hypertrophies, fatty degenerations, &c., we ought never to forget that none of these conditions are in themselves diseases,—but only the mechanical manifestations of disease. The disease being what produces the mechanical manifestation. Just in the same way as neither the flame nor the smoke that issue from a volcano, nor even the scoriæ or the lava that are ejected from it, are the cause of the disorder. The cause of the disorder being the chemical changes taking place within the earth, and giving rise to the emitted matters. In the same way it is not what we see by eye or microscope that is really the disorder, but only the products of the disorder.

When medicine first began to be studied and pathology was unknown, symptoms were thought to be diseases; in fact all our old names for diseases are simply the names of symptoms,—hæmoptysis, hæmaturia, and jaundice being merely names of sym-

Digitized by Google

ptoms. No sooner, however, did morbid anatomists begin to study the physical changes in the body, than they transferred the titles of the diseases to the morbid structures. Next, when the microscope was carried into the dead-house, a cellular pathology originated, and immediately we founded our theories of disease upon the histological changes. Now that science has gone beyond this, it has been found inadequate to satisfy the human mind, and we crave after the cause and try to see something beyond the effect—and the test-tube and the balance have now come to our aid. Fortunately, I think, for us, there is no form of disease you could have chosen so easily traced in its chemical effects as alcoholism. Although alcohol, no doubt, acts as a poison on the tissues when given in large quantities, it, at the same time, like prussic acid, which is a more powerful poison still, may be used, not only as a medicine, but also as a food. We all know the effects of intoxication, but few of us know the effects upon the tissues of the body the continued use of small quantities of alcohol taken at a time produce. It is only men that make the liver and kidney their special study that get even a half knowledge of the effects of small quantities of alcohol. Unfortunately, no hospital statistics that we have enlighten us upon the subject. No tables of alcoholic mortality are in existence, except those in insurance offices; but their tables of the death-rates arising from the effects of alcohol are most striking. Firstly, they separate the intemperate from the temperate, and then they separate the temperate from the teetotalers; and the death-rates in these three classes are most remarkably different. Two years ago, when I was writing a paper on alcohol, I turned to the Registrar-General's reports, and tried to separate different classes of drinkers by selecting the men who followed different industries, separating those that were exposed to the temptation of drinking from those that were not so exposed, and the results were startling in the extreme. I will only briefly point out one or two of them; for to-night, I believe, although Dr. Payne's paper has gone over the whole scope of the thing, we are only to discuss the effects of alcohol on digestion, circulation, and the urinary organs.

The *President.*—We are not limited to that part of the subject.

Dr. George Harley then said: I find from the Registrar's statistics that if you compare printers and brewers you discover that only 28 printers die from liver disease in proportion to 96 brewers

Digitized by Google

that 30 printers die from urinary diseases as compared with 75 brewers; and that from diseases of the circulatory system 93 printers die and 165 brewers. Then, again, comparing drapers and warehousemen with commercial travellers, while only 35 of the former, 61 of the latter die of liver disease; of urinary disease 37 of the former and 44 of the latter; and of heart disease 75 of the former and 100 of the latter. Then take men that are still more exposed to drink, innkeepers, publicans, and spirit dealers, and compare them with those least of all exposed to drink, namely, gardeners and nurserymen, and we find the disproportion is simply fabulous: for while 240 of the former die of liver disease, only 18 of the latter die from that cause; 83 of the former die of urinary diseases to 39 of the latter; and the proportion for circulatory diseases is 140 of the former to 82 of the latter. There can be no mistake in these statistics for the reason that they are not of drunkards, for waiters and barmen no sooner become drunkards than they are turned away. The Registrar-General himself remarks in his report that the effect of drink is simply appalling. And if, as we see, the effect of what one calls moderate drinking—the system of continual nipping—is so prejudicial, there is no doubt whatever that the statistics of the insurance offices are most probably correct in saying that teetotalers have the best lives of all. I am not here, however, as a teetotaler. The next point is, How does alcohol cause disease? My belief is through its chemical action. Dr. Moxon used the word de-oxidising, functional derangement. Alas! "functional derangement," though a capital word to use when speaking to patients, is not a word that we, as scientific men, ought to employ at all, for there is no effect produced without a cause, and there is no cause in nature that does not produce an effect. I do not believe in mere "functional derangement;" as without some physical cause there can be no derangement of function. The misfortune is we are not always able to detect it. Like the words hysteria or neuralgia, though good to use to the patient, it is misleading in theory. We already know that alcohol incorporates itself with the tissues in some way or other, from the simple fact that when small quantities of alcohol are taken, although you may find some in the breath, some in the urine, and even some in the cutaneous sweat, yet it is a mere fractional part of what went into the body. Then arises the question, What becomes of the alcohol? We have already received

Digitized by Google

one or two answers to that. We know that it prevents the transformation of uric acid into urea; we know likewise that it greatly increases the acidity of the urine; and, as Dr. Payne has said, it arrests tissue change. The mere fact of its arresting the tissue changes is one of the reasons why alcohol may be said to act chemically. In my own experiments (published in the 'Transactions of the Royal Society' in 1864), when working at the chemical action of poisons on the blood, alcohol was one of the agents investigated, and I found the following most extraordinary results. When only 10 per cent. of alcohol was added to perfectly fresh blood and shaken with it the blood entirely lost its power of becoming oxidised; it changed its colour to a pale brick, and then no amount of oxygen passed through that blood could re-oxidise it. When 5 per cent. was added it acted exactly like opium, but in a less degree. For example, when ordinary air containing 20 per cent. of oxygen was mixed with pure blood and shaken with it 10 per cent. of the oxygen disappeared; but with 5 per cent of alcohol added only 4 per cent. of the oxygen disappeared. In pure blood there was 3·3 per cent. of carbonic acid formed, but with blood plus 5 per cent. of alcohol there was only 2·3 per cent. Now this is exactly the same action as opium has. I may mention the effect of opium, and to show it more powerfully I quote an experiment made upon calf's blood, because the arterialisation of the blood of the calf is more rapid than of the old animal. With 20 per cent. of oxygen 14 disappeared from the pure blood; while with morphia only 3 per cent. out of the 20 disappeared. The carbonic acid, again, in the calf's blood was 3·4 per cent., but with the morphia only 1 per cent. This clearly points to the chemical action of alcohol on the system, and my belief is that if the younger members of the Society, instead of directing their whole attention to histology, would turn a portion of it to chemistry, we should soon make progress in discovering the causation of disease; whereas without the aid of chemistry we never will.

Dr. Lionel Beale.—I desire to bring before the Society one or two points in connection with changes that have taken place in cirrhosis of the liver. There are one or two specimens in the other room of the liver of a person who died of cirrhosis after an illness of two years. The liver in that case was at one time perhaps twice as large as it should be, and it gradually contracted to about the

Digitized by Google

normal size when death took place from violent hæmatemesis. The point to which I wish to direct attention is that in the intervals between what appear to be the lobules there is a quantity of what is well known to all of us as fibrous or connective tissue or cicatricial tissue. The point is that this tissue as Dr. Payne was kind enough to mention from observations of mine some years ago was shown to contain a great number of elements that were not ordinarily visible. If prepared in a certain way, various structures could be found in it, and the general conclusion one arrived at was that, so far from its being adventitious material, the result of inflammation, it consisted rather of the débris, the wasting of the normal tissues of the gland; and when one came to examine this fibrous-like texture carefully in specimens that had not been dried in any way or mounted in Canada balsam, the fibrous-like material was seen to contain vast numbers of tubes containing altered liver-cells. In fact there can be no doubt whatever that the appearance is due to changes taking place in the normal texture of the liver—changes which, however, approach more nearly to the nature of atrophy than anything else, the tubes shrinking and the liver-cells getting small and hard. The small round mass in the centre represents all that remains of the normal liver-cells, so that I suppose the appearances represented are really due to nothing more than gradual degeneration taking place from the circumferential part of the lobules towards the centre. The cell containing network at the circumference of the lobule is the part which is most active; under ordinary circumstances this degenerates first, and the process of degeneration goes on towards the centre, and at last the tissue which was once lobule becomes converted into this fibrous-like material, which, nevertheless, contains distinct remains of the elementary structures of the liver. In this drawing it must be borne in mind that not one half of what really exists is represented. In the intervals between all these little tubes are vessels, and these vessels can be shown quite distinctly by the process of injection; but if sections be made in the ordinary way, and the preparation dried and mounted in balsam, nothing is seen but a fibrous-like material. It seems to me therefore interesting that this point should be brought before the Society, and I hope that others will examine sections of the liver in the same way as well as other morbid specimens impregnated with syrup or glycerine, or some highly refractive material which will mix with water. The

Digitized by Google

sections can be examined with magnifying powers of from 200 to 700 diameters.

Dr. Stephen Mackenzie.—I did not intend to take part in the discussion, but I asked the Secretary if he cared to have a case of cirrhosis of non-alcoholic origin. It is well known that cases of that kind are not very rare, though somewhat exceptional. That case was one of a little girl twelve years of age who was under my care in the London Hospital, where she came with an enlargement in the upper part of the abdomen. It was very uncertain for a long time what the swelling was due to, and various views were held by those who saw it, the general impression being that it was, perhaps, most likely hydatids. There was no urgency in the symptoms; the nutrition was good, the colour was good, and there were no symptoms demanding active treatment. She was sent out of the hospital and told to report herself later. She did so, and I saw her on my return from my holidays. She again improved, and there were no symptoms of very great urgency. But one day, when apparently in her usual condition, she was seized with hæmatemesis, and this went on day after day in spite of all means employed and the child died in the course of four or five days or a week. The *post-mortem* examination showed that the liver was extremely contracted with dense bands of fibrous tissue pervading it in all directions. The microscope shows the appearances of cirrhosis with dense bands of fibrous tissue surrounding the liver-cells in certain stages of degeneration. It seems to me that cases of this kind, which it would be hardly profitable for me to occupy the time of the Society with just now, ought perhaps to be considered in relation to cases which undoubtedly are of alcoholic origin. Various hypotheses are being put forward as to their explanation. In this case I made careful inquiry, but there was no history of the child having taken alcohol in any form, except with extreme rarity, though it is well known that some cases of cirrhosis in children younger than this one have been traced really to the ingestion of alcohol. Dr. Barlow, in particular, and several other gentlemen, have been able to trace instances of drinking in quite young children, but in this case, as far as could be ascertained, and in one or two other cases that I have seen, no such history was obtainable. But the changes are certainly of the kind which are usually met with in alcoholic cirrhosis. Though I had no intention of taking part in the dis-

Digitized by Google

cussion, at present at any rate, I must say my own feeling, having examined a fair number of cases of cirrhosis microscopically, is that the primary process is an overgrowth of connective tissue. If one examines the parts of the liver least affected one sees the nuclear proliferation, a number of round-cells more especially round the bile-duct and in the periphery of the lobules. It is true that in patients who die you find changes of cells; we find them in whatever disease we like to examine under the microscope. When patients have been brought to that state of nutrition which brings about death we always find in the liver-cells a certain amount of change and fatty degeneration, so that I do not consider the question settled as to whether the change is primarily in the glandular cells, or primarily in the connective tissue by the mere fact of finding a certain amount of change in the cells. It may be true that the changes go hand in hand, and that we are not to talk of cirrhosis as parenchymatous or as an interstitial affection, but that the two go together. If we watch what has taken place in the liver in a large number of diseases we find as the early change a certain amount of cellular infiltration or germination round the lobules and bile-ducts, and my own belief is from the fact that this goes on to such a dense organisation as to contract the liver into various distorted forms, that we cannot look upon that process as compensatory to the shrinking of the cells, but must regard it as the primary process, while the changes in the liver-cells are possibly the result of the contraction which takes place in the liver.

Dr. Mott.—The specimen I have shown in the other room is taken from the heart of a man aged 34. He was admitted into Charing Cross Hospital with symptoms of cardiac syncope and drunkenness. He died two hours after admission. An inquest was held, and a *post-mortem* ordered to be made. I was present at the *post-mortem*. The liver was enlarged, fibroid, and flaccid. The cause of death had to be accounted for. There was no stenosis of the coronary arteries, but there were one or two early atheromatous changes in the descending aorta. The heart was enlarged and weighed 15 oz., and both ventricles, particularly the left, were dilated. The substance of the heart was soft, with some endocardial mottling. I was interested in the subject, and took a piece of the heart to examine for fatty degeneration, giving it as my opinion that the man died of cardiac syncope. There was no cause

Digitized by Google

of cardiac syncope from the history of the man except alcoholism. He had been drinking for some time past, and was admitted in a state of drunkenness, having been drinking with a friend outside. The microscopic specimens showed very extensive fatty degeneration of the ventricular walls, especially in the columnæ carneæ and musculi papillares, particularly in the left ventricle. I had not much experience as to whether alcohol should produce such a condition, but I looked it up in Stevenson, and I found that Professor Shroetter, in his article in 'Ziemssen's Encyclopædia' on fatty degeneration of the heart, mentions alcohol as one cause, in conjunction with mineral poisons, phosphorus, and other things. The coroner's inquest, I think, will eliminate any possibility of poisoning, and therefore I considered possibly this was a case of fatty degeneration of the heart induced by alcoholism.

Dr. Dickinson.—I will say a word first about cirrhosis of the liver, undoubtedly a frequent result of the abuse of alcoholic drinks. Dr. Payne attaches great importance to the degeneration of the epithelial cells in this condition, and Dr. Beale believes this to be the essential and primary change in cirrhosis. Dr. Payne does not go so far as Dr. Beale does, but he attaches at least as much importance to the wasting of the epithelium as to the fibroid increase. The fibroid increase in Dr. Beale's view is only apparent, being due to the falling together of the old fibrous tissue on the removal of the cells. Now, to this theory I must demur. I would appeal especially to the rapid cirrhosis of childhood, where the organ is enormously increased in weight and bulk, which can only be by a hypertrophic, not a degenerative, process. In such cases the fibroid tissue is enormously increased, as is evident to the naked eye, and with the microscope is seen to be highly nuclear, like a new growth, which it obviously is.

A similar statement may be made with regard to the granular kidney. In childhood, and whenever the disease is rapid, the profuse nucleation and characters of recency are striking; and I may add that new blood-vessels are manifestly developed in it. These are clearly not old vessels which have stood against the growth, but delicate wide channels, which it is impossible to doubt have been developed within it. In both the liver and kidney I believe the new growth of fibrous tissue to be the most important part of the process; the cells may change, too, simultaneously, or in consequence, but this is certainly not the only, or the most important,

Digitized by Google

part of the disease. What is more likely than that the fibrous tissue which is in immediate contact with the portal vessels should be the first part of the organ to feel the irritant effect of the poison which these vessels convey?

The effect of alcohol upon the liver, however brought about, admits of no doubt. That upon the kidney is less evident. I long ago endeavoured to show that the effect of alcohol upon this organ had been greatly exaggerated. In the course of the circulation the kidneys are much more remote from anything introduced by the veins of the stomach than is the liver, which receives it first hand, while what the kidneys receive is modified by distance and dilution. Thus the fibrosis of alcohol is less evinced in the kidney than the liver.[1] I made a comparison between the morbid anatomy of persons whose trades lay among liquor, and for the most part got it for nothing, and often *ad libitum*—potmen, publicans, brewer's men, cellarmen, and the like—and persons who were not so circumstanced, and were not known to be drunkards; 149 *post-mortems* of each class were taken as the basis of observation. Of the traders in drink 22 had cirrhosis of the liver, of the others 8. This, of course, does not present the difference between alcohol and no alcohol, but between more and less. But the result is conclusive as regards the liver. It proves, what everybody knows, that drink causes cirrhosis. The liver was sometimes small, sometimes greatly enlarged with fatty change; the former, I think, chiefly in spirit-drinkers, the latter in drinkers of beer. This preponderance of liver disease is so consistent with other evidence that it is in some sort a warrant for the soundness of the method employed,—it shows that those who got liquor for nothing had made use of their opportunities. Now with regard to the kidney we have no such difference; the total of renal disease was nearly the same in the two classes; the granular or fibrotic kidney was slightly more frequent under the alcoholic occupation, but only in a proportion of 31 to 27. I should mention as slightly qualifying this statement that the drink traders died at the average age of 36; those otherwise employed at the average age of 40. The drink traders dying somewhat earlier, had less time to get granular kidneys. As this condition is most frequent with advancing years a little allowance must be made in the direction I have indicated.

[1] Paper on "The Morbid Effects of Alcohol," 'Medico-Chirurgical Transactions,' 1873.

Digitized by Google

A conclusion similar to that I have stated was reached by an examination of persons dead of delirium tremens, in whom renal disease was not more frequent than in men who had been cut off by accident, without any such evidence of alcoholic excess. I think that the influence of alcohol in causing renal disease is not to be entirely ignored, though it is less than used to be supposed. Now and then one sees a rather rapid case of renal disease in a young person which presumably has this origin; but it is a far more frequent experience to find the effects of drink in other organs and structures, while the kidneys escape.

The liver and the kidney appear to be acted on by different morbid causes. With regard to the liver the chief is drink; as to the kidney, there are many, of which alcohol may be one, the others being heredity, climate, gout, lead, &c., upon which it would be foreign to the present purpose to dwell.

A point of interest as between the liver and kidney is the fact that while both are exceedingly liable to fibrosis, yet they seldom become fibrotic together. I found that cirrhosis of the liver was present only in one seventh of the cases of granular disease of the kidney, and subsequent observers have brought out almost exactly the same proportion. Were the state of the kidney often due to drink it might be thought that the liver would more often suffer, for no drop goes to the kidney but what has first passed through the liver. One might suppose the kidney to escape, though the liver may have been affected, but scarcely the liver to remain untouched by drink which has disorganised the kidney. All the evidence suggests that for the most part the liver and kidney are affected by different morbid agencies.

Next as to tubercle in connection with alcoholism. I can myself entertain no doubt on this question, though my opinion is not that of Dr. Walshe and of some others. My observations on traders in drink appear to be conclusive. I found that with these tubercle was more frequent in every organ of the body liable to it than with others. In the lung tubercle was found in a proportion of three of the drink traders to two of persons following other callings. In the brain the proportion was two to one; in the liver three to one; in the bowels, mesenteric glands, and peritoneum more than two to one. Thus

Digitized by Google

I regard it as certain that drink as a rule promoted tubercular disease.

In conclusion I will propose another point of view to the consideration of the Society. We all know that alcohol is a cause of disease, and we know many of the diseases it causes; but is there nothing to be said on the other side? Is there no disease or condition of impaired health which it prevents? With regard to the whole body and each organ in particular good health is a medium state, neither too much nor too little; not too fat, but yet fat enough; the brain not active to mania, nor sluggish to melancholy; the heart duly stimulated and duly inhibited; the bowels in motion, but not excitement; the urine sufficient, but not profuse; and so on. Thus if alcohol causes a departure from health in certain directions, may it not prevent departure in opposite directions? If alcohol prevents oxidation it must be good where oxidation is in relative excess—if such states there be, as there cannot fail to be. I do not now refer to the treatment of disease; that would be foreign to the purpose of the Society, but only to the production and prevention of it. In short, is it not likely that as alcohol produces some diseases it may prevent their contraries? In my examination of the morbid anatomy of drink traders I got some evidence of this preventive action, slight though it was, as compared with the productive. Drink appeared to retard adhesive and plastic processes, and to replace them by suppurative, a change mostly for the worse, but perhaps not always so. In a serous cavity adhesive inflammation may be better than suppurative, but on a mucous surface it may be the reverse. Under drink I noted a paucity of valvular disease of the heart, or, in other words, of endocarditis, for atheroma is increased under the same agency. But the salutary effects of alcohol are far less apparent than the mischievous. It is probable that the preventive action, if such there be, rapidly develops into the morbid one. But I do not pretend to speak otherwise than doubtfully on these points, or to do more than indicate what seems to me to need further elucidation.

Dr. Buzzard.—I shall not occupy the time of the Society by dwelling upon the *clinical* aspects of alcoholic paralysis, the subject on which I wish to make a few remarks to-night. It would be probably out of place in a discussion of this kind, and we are all, I think, now more or less familiar with the condition. I would,

Digitized by Google

however, refer to a symptom occurring in females to which I have not seen attention directed. In females affected with alcoholic neuritis I have observed now, during many years, that the catamenia are almost always suppressed during the many months of the illness which are involved. I do not attempt an explanation of this. It seems to me a curious and interesting fact when taken in conjunction with the well-known complete, or almost complete, immunity of the functions of the bladder and rectum. I should agree with Dr. Payne that the acceleration of the heart's action is very likely due to lesion of the vagus nerve, and I venture to suggest that the pneumonia which occasionally terminates the scene in cases of this kind is very likely due to a similar cause. Dr. Payne in his most valuable and able address referred to the two kinds of microscopical change observed in cases of alcoholic neuritis, and whilst pointing out that these two kinds were very generally associated, he remarked that sometimes the signs of parenchymatous degeneration, and sometimes the signs of interstitial inflammation predominated; and he went on to say that he was of opinion that both those changes must be referred to the direct action of alcohol. Now, I am sorry to say I am opposed to this view. It must be remembered that we have usually here to do not with universal or even very widely spread changes. Examination after death in these cases has shown, as a rule, that the spinal cord, the roots of nerves, the brachial, lumbar, and sacral plexuses, and proximal portions of the nerve-trunk are entirely free from pathological changes, and that this change is practically confined to the trunk and branches of the nerve. Now to me it is inconceivable that a toxic agent like alcohol floating in the current of the blood and permeating all the tissues should pass over the structures I have mentioned to concentrate itself upon the peripheral parts of the nerves. Moreover, although, as Dr. Payne has justly remarked, these two kinds of change, the parenchymatous degenerative change, and the interstitial, are very generally associated, yet that is certainly not always so. Exceptional cases have been described by Strümpell and others, in which the degenerative change in the essential part of the nerve-fibre was the only change observable, in which all signs of interstitial inflammation were wanting. Cases like this have been so striking that Erb has even seriously suggested that we have here to do not with one disorder at all but with two distinct diseases, parenchymatous with degenerative atrophy

Digitized by Google

on the one hand, and interstitial neuritis on the other. Moreover, it seems to me that this very fact, the exclusive affection of one structure, is extremely strong evidence against the view Dr. Payne takes that alterations are due to the direct action of alcohol, because it must be remembered that in these cases, since they were fatal cases, the disease was not slight in character but of the most serious kind. I myself have long felt that, although there were no observable lesions in the spinal cord, yet from the peculiar position of the parts in which change takes place—the concentration of pathological alterations in the periphery of the nerve system, involving so many nerves—that we must after all look to some change in the cord as having produced this limited and coincident alteration of so many nerves, and I suggested three years ago, in the Harveian lectures, that we must in all probability look to the action of alcohol upon the vaso-motor centres in the bulb and cord for an explanation of the phenomena observed in the peripheral nerves. It is common observation that the earliest symptom of alcohol inebriation is flushing of the face, indicating a commencing paralysis of the cervical sympathetic. In such cases it is a passing and temporary affection, but let us suppose the repeated and continued influence of alcohol upon these vaso-motor centres, and I ask what, as a result of that, should we expect to have? We should expect to find change in the tone of the vascular area supplied by minute arteries, those arteries in which the muscular coat is relatively most developed. Now, these arteries are in the more remote parts of the arterial system, and they correspond, therefore, generally with the distal portions of the nerves, and in this way it seems to me most likely that an irritative influence of alcohol on the vaso-motor centres in the bulb and cord can bring about a change in the supply of blood to these parts of the nerves. That change will vary according as either the vaso-motor or the vaso-dilator fibres are affected; the change will take place accordingly either in the direction of constriction or dilatation. Now, notable diminution of blood supply to the nerve would result, I submit, in starvation and degeneration of the essential elements of the nerve-fibre, whilst, on the other hand, arterial dilatation would cause blood stasis and inflammation. I would point out to you that the œdema, which is so frequently a symptom of alcoholic neuritis, bears concurrent testimony in the same direction. To pass on to another subject, I notice that Dr.

Digitized by Google

Payne referred to the account of a controversy which had taken place as to whether the word "neuritis," which implies inflammation, was a proper term to be used to a disease in which the dominant morbid appearance was that of simple degenerative atrophy. About two years ago the difficulty, which I myself have felt, seemed to be resolved in rather a curious way. I was anxious to find out what was the significance of this termination "itis," which we so freely use, and I tried to get references to it. I looked in vain in the Greek classics, and could not find it in the Greek Lexicon at all. It is evidently of comparatively modern origin. I spoke to a Greek friend of mine and he could not help me, but what is more important he put me into communication with Professor Kontos, of Athens, who I understand is considered, both in Germany and in Greece, to be the highest living authority on Greek philology. Professor Kontos was kind enough to interest himself in the question and to make a communication to me, which I shall with the permission of the Society refer to. I have the communication in the original Greek, and I shall be happy to read that to the Society if they so please; but as possibly there may be one or two members who would find English easier to understand—I am one of those myself—perhaps I should, in the first instance, read the translation. This is a very literal translation, but it is to this effect:—"Arthritis and nephritis, and pleuritis and splenitis, and all such things are literally epithets or adjectives, and the word 'nosos'—'disease'—is understood. The disease about the ribs is pleuritis, just as the disease about the joints is arthritis, and nephritis is the disease about the kidneys." It appears from this that the word "neuritis," for example, is an adjective with the word "disease" understood, and that all that is meant by neuritis is disease affecting the nerve, as myelitis would be disease affecting the marrow or spinal cord, and that the term inflammation which it has got to be associated with is simply an invention of much later date, for which there is really no authority whatever, and that we should be perfectly right in the future, etymologically correct, in using the term neuritis for a condition which may present no signs of what is ordinarily called inflammation.

Dr. Pitt.—The records of the *post-mortem* examinations at Guy's Hospital are a storehouse of facts, upon which I have drawn for the purposes of this discussion, as it appears to me that from such

Digitized by Google

accurate sources we are most likely to gain the surest knowledge, as the accumulated experience of such an institution is readily collated, and must exceed that of an individual. The late Dr. Hilton Fagge, in the 'Guy's Hosp. Rep.,' vol. xx, series 3, discussed the *post-mortem* records of all cases of cirrhosis of the liver previous to 1875, and Dr. J. A. P. Price the cases between 1875 and 1883 in vol. xxvii; and I find that the conclusions to be drawn from cases of cirrhosis between 1875 and 1886, which I have collected, taking only those with a marked alcoholic history, in the main agree with theirs, and, as they are important, I may summarise them as follows:

Weight of livers.	Number of cases.	Granular kidneys.	Tubal nephritis.	Kidneys over 10 oz.	Kidneys over 15 oz.	Tubercle in the lungs, &c	Average age at death.
Under 50 oz. . . .	28	5	3	11	4	3	48·5
Between 50 and 60 oz. .	18	6	...	9	...	5	46
Over 60 oz. . . .	43	7	2	18	8	12	45·7
Total .	89	18	5	38	16	20	...
Percentage .	100	20·5	5·5	43	18	22·5	...

Cirrhotic livers are essentially large livers; in only one third are they below the average weight, and a main factor in explanation of this is their fatty condition. The average age at which patients with large livers died was 45·7 years, while those with small livers averaged nearly three years longer, thus showing that the large livers represent a more acute form of the disease; but I found that granular kidneys were rather more often (one sixth of the cases) associated with small livers than with large, the reverse result to that obtained by Dr. Price; but the number is too small to draw any definite conclusion from it.

During 1885–86 there were *post-mortems* on twelve patients who had been hard drinkers, and whose kidneys were found to exceed 12 oz. in weight, and in seven cases 15 oz., excluding those patients who had lardaceous disease, cardiac failure, or other cause for kidney enlargement. These kidneys are described, in some as large, but otherwise normal; in others as coarse in structure to the eye; and in two cases as large white kidneys; microscopically some showed slight interstitial cell infiltration, others showed

Digitized by Google

scarcely any change from the normal, and it would therefore appear that the change is mainly an hypertrophy. These large kidneys are usually associated with large fatty or cirrhotic livers, which for these twelve cases averaged 77 oz., and except in the two cases of large white kidney there was very little appeared abnormal to the eye, and not much to the microscope. This condition of large kidneys as a result of drink is one which is noticed in Wilks and Moxon's 'Pathology,' and I have frequently seen the association verified, but I do not think that it is one which is generally recognised by the profession. Bearing this out, we must recollect the average size of kidneys in diabetes is nearer 15 oz. than 10 oz., and this is due to the extra work thrown upon them. The same explanation applies to these large kidneys of alcoholics.

Therefore this remarkable fact comes out, that among the cases of cirrhosis of the liver in patients who had drunk freely we find that the kidneys weighed over 10 oz. in 43 per cent. (in only one third of which nephritis was noted), and over 15 oz. in 18 per cent.; and it is repeatedly stated that the changes in structure were very slight. In 26 per cent., however, or rather more than one fourth, there were granular kidneys or tubal nephritis. These facts, that in one half the cases the kidneys are enlarged, and in one fourth severely degenerated, show that alcohol does affect the kidneys, but I have not been able to determine whether they are affected as frequently as the liver.

I have frequently been struck by the way in which cases of cirrhosis have suddenly developed acute tuberculosis of the lungs, and occasionally of the peritoneum, and I was more particularly impressed with the association, as there were *post-mortems* on eight cases of cirrhosis in 1883, about the time when I was holding the appointment of house physician. These eight cases are as entered:

Digitized by Google

Cases of cirrhosis of the liver examined post mortem in 1883 *at Guy's Hospital.*

	Weight of liver.	
M., æt. 39	74 oz., with tubercle	Grey tubercles in lungs.
W., æt. 42	72 oz., fatty	Tubercular ovaries, uterus, Fallopian tubes, and peritonitis.
M., æt. 49	70 oz., fatty	Acute tuberculosis of lungs.
M., æt. 49	56 oz., fatty	Fibroid phthisis, caseous epididymis. Kidneys 14 oz.
W., æt. 40	98 oz., fatty	Acute tuberculosis of lungs.
W., æt. 58	45 oz.	Granular kidneys.
M., æt. 35	56 oz.	Cavities at apex of lungs, with general grey tubercle.
M., æt. 40	65 oz., fatty	Tubercular disease of larynx intestine. Grey tubercle in lungs.

That is, out of these eight cases acute tubercular disease was found in six, and fibroid phthisis in one of the other two.

An examination of the records shows that this is an exceptional experience; still, of thirty-three recent cases due to alcohol, thirteen had tubercle; and of the eighty-nine cases between 1875 and 1886 tubercle was found in 22·5 per cent. I but rarely found that there was any caseous broncho-pneumonic phthisis, but often there have been old cavities at the apices, with fibroid changes locally, and almost invariably a general dissemination of grey tubercle. Frequently also the pulmonary symptoms have not been prominent, and the acute tubercular condition may be overlooked until the *post-mortem*. Hence I suspect that those tables founded on the Registrar-General's reports which appear to show that innkeepers and others addicted to alcoholic drinks are less susceptible to phthisis than the average, are vitiated by the fact that they only take cognisance of those cases in which the lung symptoms were conspicuous. If experience confirm the view that the form which the disease may take is usually that of grey tubercle, and not of a caseous, less acute, but more readily recognised phthisis, we can understand that in the absence of *post-mortems* these lesions are often overlooked, and the question can only be settled by an examination of *post-mortem* records. It is also most striking if we take the cases of cirrhosis in patients under 40, for out of thirty-three

Digitized by Google

cases two thirds had tubercle in the lungs or elsewhere. I have always been struck by the large number of cases of alcoholic neuritis in which tubercle has also been found in the *post-mortem* room. I am therefore strongly of opinion, when alcoholic excess has led to fatal degenerative changes in organs, that at the *post-mortem* inspections in a large proportion of cases grey tubercles will be found in the lungs or elsewhere, and that the proportion will be highest in young patients.

Another question on which I thought the records might throw some light is the relation of alcohol to acute yellow atrophy. Acute yellow atrophy is so rare a disease that it is difficult to decide what relation it bears to alcoholism. Thierfelder, in 'Ziemssen,' refers to six cases in topers where an unusual alcoholic excess seems to have determined the acute atrophy, and thirteen out of the 143 cases he collected were drunkards. At Guy's we have had three cases of acute atrophy in drunkards:

1. Man, aged 25, a heavy drinker, under Dr. Pavy in 1878. He came in with vomiting, and developed double pleuro-pneumonia and jaundice, shortly became comatose, and died.

Post-mortem.—Liver 85 oz., in a state of acute red and yellow atrophy. Microscopically it showed fatty disintegration of the liver-cells without interstitial growth. Kidneys 21 oz., large, coarse in texture, and fatty. Spleen 38 oz.

2. Man, aged 22, a cattle drover, who drank, but he said not to excess. Admitted under Dr. Pye-Smith in 1876.

Post-mortem.—Liver 26 oz., cirrhotic, with numerous tracts of connective tissue. The liver was bright yellow, and showed acute yellow atrophy engrafted on cirrhosis.

3. Man, aged 23, admitted under Dr. Goodhart in 1887 with vomiting, delirium, and semi-coma, who died at the end of a week of epileptiform convulsions. He had drunk a gallon of beer and several glasses of whisky daily for weeks.

Post-mortem.—The liver weighed 33 oz., and showed an appearance of cirrhosis, combined with red atrophy, but this was considered by the Morbid Growths Committee, when the case was brought before this Society by the late Dr. Carrington in 1885, to be due to acute red atrophy without cirrhosis. A similar case was reported by Dr. Cayley in the 'Transactions' of this Society for 1883.

I have also twice seen sections of cirrhotic livers where portions

Digitized by Google

of the tissue showed the appearances of acute yellow atrophy. I am showing under the microscope this evening a section of a cirrhotic liver which weighed 103 oz., which closely resembles acute yellow atrophy in appearance. The liver-cells have undergone an acute fatty necrosis, have not stained, and are very disintegrated, while there is some small cell infiltration. I think therefore that there is evidence enough to justify us in concluding that alcohol may cause acute atrophy of the liver, but it is an extremely rare occurrence, and what actually determines the atrophy is still unknown.

Then the question of the association between cancer and cirrhosis is a very interesting one.

We have had five cases of cancer associated with cirrhosis:

1. Man, aged 46, admitted under Dr. Fagge in 1875. He died with ascites, large liver, and jaundice.

Post-mortem.—Liver 62 oz., cirrhotic, studded with cancer, but it was difficult to say where the cirrhosis ended and the cancer began. A mass of growth invaded the portal vein.

2. Man, aged 71, under Dr. Habershon in 1874, who died with jaundice and ascites. At the *post-mortem* the liver looked cirrhotic, but on examination the nodules were found to be cancerous.

3. Man, aged 52, under Dr. Pavy in 1876 with ascites.

Post-mortem.—Liver 36½ oz.; looked like hobnail cirrhosis, but microscopical examination showed that the nodules were cancerous. The growth invaded the portal vein. These three cases were reported by the late Dr. Hilton Fagge in the 'Transactions' of this Society for 1877.

4. Man, aged 52, a publican, under Dr. Fagge.

Post-mortem.—Liver 69 oz. The right lobe was very atrophied, and the condition looked like hobnail cirrhosis. Dr. Mahomed considered that the microscopical appearance was due to bile-ducts crowded together in the most atrophied parts, and that the case was one of cirrhosis. A further examination by Dr. Goodhart of other sections showed cirrhosis, yet cancer was also undoubtedly present, as many of the cells were of a markedly epithelial type, and differed from those found with cirrhosis.

5. Man, aged 52, under Dr. Moxon in 1882; a heavy drinker. The liver was of enormous size, studded with circumscribed carcinomatous growths, and the liver generally was moderately cirrhosed. There were no other malignant growths in the body. The

Digitized by Google

difficulty in deciding between carcinoma and cirrhosis was also well exemplified in a case brought before this Society by Dr. Goodhart in 1885, which was considered to be undoubtedly one of malignant growth, and yet, after careful microscopical examination, it was finally shown to be a case of cirrhosis with islets of liver-cells, which had given it the cancerous appearance. This difficulty seems to me also one of the strongest arguments in favour of the view that very exceptionally a cirrhotic liver may become cancerous; but the cases of primary carcinoma were too few to draw any conclusions from them as to whether the irritation of alcohol had started the carcinoma.

It is also desirable to place on record the only cases of suppurative meningitis which have occurred in drunkards at Guy's Hospital since 1874 which appeared to be due to alcohol. Although the possibility of their being sporadic cases of cerebro-spinal meningitis cannot be denied, still some authors hold that drunkards are more susceptible than others to that disease.

1. Man, aged 45, admitted in 1876 with acute right hemiplegia preceded by a headache. Urine 1026 sp. gr., albuminous. He was restless and constantly moved about. He became comatose and died in three days. Temperature 102°, pulse 172, respiration 60. He had been a hard drinker.

Post-mortem.—General vertical cerebral meningitis—more pus on left side; skull healthy.

2. Man, aged 25, who had been drinking hard for a week, was admitted in 1883 semi-comatose, very troublesome and unmanageable. Next day he became collapsed and unconscious and died.

Post-mortem.—General suppurative meningitis. Liver 85 oz.; other viscera healthy. Kidneys 13 oz.

There have been only three cases of hæmorrhagic pachymeningitis:

1. Man, aged 42. Heavy drinker, who in 1870 died with ulcerative endocarditis in alcoholics.

Post-mortem.—The dura mater was thickened, and showed yellow ochreous patches, due to old meningeal hæmorrhage.

2. Man, aged 73. Insane for three years. A hard drinker. Old meningeal hæmorrhagic cyst over occipital region.

3. Woman, aged 52, where *post-mortem* pachymeningitis was found over the frontal region. This case was published by Dr. Hale White in the 'Transactions' of this Society for 1886.

Digitized by Google

The extreme rarity of pachymeningitis and suppurative meningitis is evident when so very few cases have occurred among the 5000 *post-mortem* records. In conclusion, I may say that I have endeavoured to present to the Society the deductions to be drawn from the cases of alcoholic cirrhosis of the liver, and to collect some of the rare and exceptional lesions which, there is reason to believe, are due to alcohol in excess.

Dr. Finlay.—As the evening is getting on I shall only occupy a few minutes of the time of the Society by referring to one or two specimens which I have shown, and one or two points in cases of alcoholic paralysis. The appearances shown in my sections in the other room bear out in detail very much of what Dr. Payne said with reference to the pathological changes which are to be found in certain parts of the nervous system. I need not go over them all in detail, but will refer only to two cases, one that of a woman twenty-eight years of age, and one a man fifty-one years of age. Both died in the Middlesex Hospital and were typical instances of the disease, both as regards history and symptoms. There is no mistaking the appearance in the transverse section of the plantar nerve shown on one of those drawings, and alongside it I have placed a section of a normal nerve drawn under the same conditions and prepared in exactly the same way, so as to show the extreme gravity of the changes that take place in the nerve in such cases. I have also placed alongside of that a longitudinal section of the same nerve which shows the degeneration of the nerve-fibres and the fining away to a point of some of the nerve-sheaths, and the fibrous condition to which some are reduced, which is also seen in the sections I have shown. I have also shown a section of the lumbar cord from the same case, and I should like Dr. Buzzard to look at that section. It seems to me that it is absolutely normal. I do not mean to say the cord is always normal. One of the cases which Dr. Sharkey has published, in the last volume of the 'Transactions,' shows that there may be considerable changes in the cord, and I have seen similar appearances in one of my own, but the cases in which the cord appears to be perfectly normal are quite sufficient to prove that the cord need not be affected. In one of my own cases there was some appearance of degeneration of the cells of the anterior cornu, such as Dr. Sharkey has described, but the changes in the peripheral nerves were exactly of the same kind, and even greater

Digitized by Google

in degree in those cases which showed no degeneration of the cord than in those in which the cord did present some change which might be supposed to be pathological.

Then the fact of changes being found in the vagus is a very interesting one, and brings the pathological appearances into line with the clinical phenomena in a very instructive way. These have occurred in one of my cases (referred to by Dr. Payne), and in one of Dr. Sharkey's.

In my case the patient was under observation ten days, and the pulse rose from 72 to 160, which seems to me to bear out what Dr. Payne said. In another case I found no change in the pneumogastric. The same remark applies to the phrenic, although there was one phrenic which I investigated in which I could find no appearance of pathological change, notwithstanding that the diaphragm was paralysed. I came to think afterwards that was because I had not taken the section of the nerve close enough to the diaphragm. In another case the section was made about a quarter of an inch from the diaphragm, and shows, very well marked, the same changes that are to be found in the nerves of the extremities, although not in such great degree. Also there is a section of part of the nerve in the diaphragm itself, in which there is marked evidence of inflammatory change. As to the order of change in the different parts of the nerve, it seems to me the explanation which was, as I thought, rather hinted at by Dr. Payne was very probable, I think that this change may begin, first in the parenchyma of the nerve, the inflammatory condition of the perineurium being secondary. I was rather led to think this by comparing two cases under my care at the same time, both in women, and both fatal. The one that had the disease longest established showed the inflammatory changes. In this case, as shown in the plantar nerve, there is undeniable evidence of a perineuritis. The other case, which had been a comparatively rapid one, did not show those appearances at all, so that I think there might be something in the time the disease has lasted. Dr. Buzzard spoke about those changes being only in the more peripheral parts. In one case I have shown to-night the musculo-spiral nerve was taken out for its whole length. Sections were made from three different parts of it, the part nearest to the centre, the part in the middle, and in the periphery, and I could not see that the changes were more marked in one part than another. Then,

Digitized by Google

in connection with phthisis, I was very glad to hear what Dr. Dickinson said, because it confirmed an impression I had that the two things were necessarily connected with each other. I do not deny that a certain amount of alcohol properly administered may be a very good thing for people suffering from phthisis, or who are predisposed to the disease; but that is a very different thing from the bacchanalian bouts of drinking indulged in by the individuals whose organs we are discussing to-night. Then I think the latter kind of drinking may be the cause of other lapses from morality and hygienic conditions of life which may reduce vital power and determine the access of phthisis, especially in persons predisposed to the disease. In conclusion, I may say that I have been brought into contact with five cases of alcoholic paralysis of great severity. Four died; two of them of phthisis. They all had cirrhotic and fatty liver and degeneration in the peripheral nerves; all had sound nerve-roots. Of course it is impossible to generalise on small numbers of cases; still, it is only by several observers bringing their cases together and comparing notes in this way that we can hope to make any progress, because the disease is not so particularly common that any one of us may have the opportunity of having a large number of cases and being able to investigate them to the end. Unless we have the full pathological details of cases they cease to be valuable. I think one of the great benefits of a meeting like this, and the discussion of such a subject, showing specimens and referring to cases, will be that it brings to a focus what those who have been working in the matter observe about it, and may serve as a practically useful basis and help for future workers in the investigation of the pathological changes produced in the human body by alcohol.

Dr. Sharkey.—Dr. Payne, in his introduction to this debate, raised the difficult question, Is the poisonous action of alcohol first exerted upon the specialised parenchymatous tissues of the organs, or upon the connective tissue which forms their framework, or upon both concurrently? When a person dies in a delirious condition produced by alcohol or other poison, and the brain is examined, no changes may be found either with the naked eye or with the microscope. Nevertheless we argue, and probably correctly, that the nerve-cells of the brain were directly affected by the poison, but that the changes produced in them are not capable of de-

Digitized by Google

monstration by our present methods. But if Dr. Payne's question be taken as referring only to such anatomical alterations as we can appreciate by means of the microscope, I think it can be shown that, in the case of the liver at any rate, the poison brought by the portal veins acts upon the vessel and upon the connective tissue around it in the first instance, and that the liver-cells in its immediate neighbourhood may for a long time remain healthy. I have tried to demonstrate this by means of two sections: the first is taken from a liver in quite the early stage of cirrhosis, and in it one sees the great dilatation of the branches of the portal veins and capillaries, and the development of young connective tissue round them. The second section is taken from a case of very advanced cirrhosis, and there, lying along the enormous strands of connective tissue, are perfectly healthy liver-cells. Whether the vessels and connective tissue are always first diseased in alcoholic cirrhosis I cannot say, but I think that it is so generally. In other organs, however, this may not be the case, the parenchymatous elements may be first affected, or they may be attacked concurrently with the connective tissue. Thus in the case of a woman who died of alcoholic paralysis, while the disease was still comparatively recent, I found slight inflammatory changes around the vessels of the spinal cord, and slight disease of the nerve-cells as well. But probably this matter is even more complicated. Individual predisposition may play an important part, both that predisposition which is inherited, and that which is developed by peculiarities in the life of the individual before he becomes the subject of alcoholism. Thus one person's connective tissues and vessels may fall a more easy prey to the destructive action of alcohol than those of another, while in others the parenchymatous elements may be the more vulnerable. And this liability to disease of the connective tissue, on the one hand, and of the specialised cells on the other, may even vary in the different organs of the same individual. To take the case of another poison, viz. that of scarlet fever: if we examine the kidneys of persons who have died of this disease and who presented during life evidence of kidney mischief, we can see that in some cases inflammation has affected the glomeruli and intertubular tracts, whilst in others the most marked changes are observable in the secreting cells. With regard to the liver, which is the seat of alcoholic cirrhosis, it is an undoubted fact that death of the cells may occur even over

Digitized by Google

very wide areas. But I think it is very uncertain what the deadly agent is in such cases. For this necrotic change may certainly take place after patients have remained for long periods in hospital without drinking any alcohol. This destruction of liver-cells is often accompanied by very severe and curious symptoms, among them a dry, brown tongue and gradually increasing coma, such as are also seen in renal disease, and other cases of blood-poisoning. This condition results, I believe, from the destruction of liver-cells, but it is uncertain whether it is alcohol which destroys them. May there not be some other poison, organic or inorganic, which has gained access to and killed the cells? A specimen which I show to-night suggests that this may be so. The section exhibits advanced cirrhosis, and all the liver-cells are so altered that they will not take the logwood stain, although the thick strands of connective tissue are brilliantly stained. Innumerable micrococci are seen, not only in scattered colonies, and also more sparsely among the liver-cells, but also in colonies in the connective tissue surrounding the lobules. Mr. Watson Cheyne, to whom I showed this specimen, pointed out that the condition was clearly an *ante-mortem*, and not a *post-mortem* change, inasmuch as it could be seen that around the colonies in the connective-tissue strands were zones of coagulative necrosis. I draw attention to this condition in order that other such specimens which come to hand may be examined with reference to this point. But whether the micrococci produced the necrosis of the cells, or only established themselves there after they were killed in some other way, it is far from certain what part alcohol played in the process. Observers still differ as to the effect of alcohol on the kidney, some holding that it is not a frequent cause of disease. My experience in the *post-mortem* room for the last ten or twelve years has left me strongly imbued with the opinion that it is a potent factor in the production of chronic renal disease, though its injurious effects are far more frequently exemplified in cirrhosis of the liver. With regard to the action of alcohol on the nervous system, it seems probable, from the observations hitherto published, that it falls most intensely upon peripheral nerves and muscles, and much less upon the central nervous system. The palpable anatomical alterations, at any rate, are seen most strikingly in the nerves and not in the centres, though they are not entirely wanting in the latter. A great variety of nerves, both sensory and motor,

Digitized by Google

may be affected, if indeed any nerve be beyond the reach of this poison.

In the last volume of the 'Transactions' of this Society I published a case in which, in addition to the nerves and muscles of the limbs, the phrenic and pneumogastric were the seat of inflammation. It is not certain even that the nerves of special sense escape, for some authorities suppose that certain cases at least of so-called tobacco amblyopia are really cases of alcoholic amblyopia; but, so far as I know, no indubitable case of this axial change in the optic nerve has been demonstrated where the effects of tobacco, and of everything except alcohol, could be eliminated. I must here mention a case of disease of the retina which I believe was caused by alcoholic poisoning. The case was that of a woman aged twenty-four, a barmaid, who came into St. Thomas's Hospital under my care on September 13th, 1886, but who was under Dr. Ord for the greater part of the lengthened period (sixteen months) during which she was in St. Thomas's. Hers was the most severe case of alcoholic paralysis which I have seen recover. I will not narrate the case in full, as it is to be found, together with Dr. Ord's remarks upon it, in the 'Lancet' for February 11th, 1888. For a long time she lay with a dry brown tongue in a semi-unconscious condition, and subsequently had paralysis of arms, legs, and diaphragm. She recovered, however, after sixteen months' treatment in the hospital. She had at first a trace of albumen in her urine, though I did not believe she had any serious renal disease. Long before she went out it became clear that her kidneys were healthy, as there was neither albumen nor any other evidence of disease. About two months after her admission into the hospital Mr. Nettleship examined the eyes, and this was his note: "There is severe retinitis in both eyes, with white patches and bright white dots. Discs very little affected; changes most marked in sight. It is very remarkable that there is neither renal disease nor diabetes." A year later, before she went away, I got Mr. Nettleship to come and see her again, as I was much interested in the retinal changes. The following was his note: "Much better in health; says vision is quite good. Ophthalmoscopic examination of right eye (atropised) shows two kinds of changes.

"(*a*) Scattered, usually oval, dirty white spots in neighbourhood of optic disc, more above than below. All are beneath vessels; pigment around them is rather intensified, but there is

Digitized by Google

no definite collection. Surface of some of them is a little granular or glistening. Their exact nature cannot be decided by the ophthalmoscope, but they might be deposits between retina and choroid.

"(*b*) Ordinary bright white (frosted silver) confluent dots grouped chiefly along large vessels above and below yellow spot, but scattered in other parts. Optic disc of healthy colour and transparency; vessels normal. Retina round optic disc slightly filmy and thickened (parallactic movement). None of the pigment spots so commonly seen after renal retinitis, except one at the periphery. Though the silver-white spots (*b*) are usually near to large vessels they are never in front of them, nor are they arranged about yellow spot at all, as is usual in renal cases.

"*Left eye.*—Similar changes, but less abundant. If seen now for the first time the changes would hardly suggest albuminic retinitis, nor do they agree with any common type."

Dr. Ord says in his remarks on this case: "The question arises whether the retinal changes were due to renal mischief, or were possibly due to a peripheral neuritis of alcoholic origin." When we remember that there never were clear signs of renal disease, and that such even as there were passed away and left the patient unscathed, and, finally, that Mr. Nettleship said that the retinal changes "would hardly suggest albuminic retinitis," and that they did not agree with any common type, I think we must allow that the evidence is very strong in favour of an alcoholic retinitis.

Dr. Mott reported at the last meeting of the Society a case of fatty degeneration of the heart and death by syncope in a drunkard, It seems probable that the degeneration of the heart's muscle, so well known to occur in alcoholism, may be the result of inflammation of the pneumogastric nerve. For I have shown that inflammation of this nerve occurs, and is accompanied by inflammation of the heart's muscle and by severe cardiac symptoms; and this series of events seems to be a reproduction of those which occur in the muscles of the limbs in alcoholic neuritis, and which likewise occur, as I have shown, in the diaphragm when the phrenic nerve is inflamed. Dr. Payne allowed that phthisis was frequent in alcoholism, and that it was almost the rule in alcoholic paralysis. As two things at least are required for the production of phthisis,

Digitized by Google

viz. firstly, a depression of the nutrition and vitality of the lung, and, secondly, the introduction of the bacillus of tubercle, may not the first factor be the result of a peripheral neuritis either of the pneumogastric or other nerve? At any rate we are not without parallel instances of destructive alterations in tissues, the result of nerve disease; and it is not impossible that disease of the nerves going to the lung, and consequent lowered nutrition of it, may explain the frequency of phthisis in these cases. I might touch on other points in the pathology of alcoholic poisoning, such as its probable effects on the large arteries, but I have already appropriated far more than my share of the time allotted to this discussion.

Dr. Savage.—First of all I feel that I have some difficulty in addressing the Pathological Society on this subject, my experiences of the effects of alcohol upon the nervous system being so much more clinical than pathological. In looking through the whole series of cases that came under my care during the seventeen years that I was at Bethlem I found very few in which simple alcoholic excess produced insanity and ended fatally. I shall have to refer to these perhaps more in detail anon. To begin, I would say that out of some 4000 records of cases that I have looked through only 133 showed a definite relation between alcoholic excess and insanity. That, by the way, is probably much less than the ordinary asylum proportion. It must not be taken that only 3 or 3½ per cent. of persons becoming insane in England and Scotland owe that insanity to alcohol. Bethlem cases are specially selected, habitual drunkards and people of bad character are generally excluded. Therefore I will only say my experience is drawn from 133 cases out of 4000. But in these one had, I think, examples of nearly all the forms of disorder that may occur. One important subject in relation to this is, that in looking though the 133 cases I find that rather less than one fifth of those cases came of insane stock, so that of those who became insane as the result of alcohol the neurotic inheritance was much below the inheritance of neurosis of other insane patients. So that the majority of patients admitted into Bethlem suffering from insanity due to alcohol seem to have become insane chiefly through the alcohol, and not through the neurotic inheritance with alcohol merely as the exciting cause. I have no doubt alcohol may start neuroses in the individual, but, what to my mind is much more important, it is equally likely to

Digitized by Google

start neuroses in the family, so that a person who has become habitually intemperate may later develop some of the many neuroses, such as epilepsy or insanity; and it is very common for his offspring to develop neuroses. Another point which astonished me among my cases was one mooted by Dr. Payne in his paper, and that was the relation of alcoholism to general paralysis of the insane. In looking over these 133 cases of insanity produced by alcohol I found that a very small proportion was suffering from general paralysis of the insane. I shall have to refer to those cases and the relative proportion of them later.

I quite agree with Dr. Payne, and have been for years in the habit of teaching on the same lines that he has followed, that there are certain conditions which are associated first of all with simple disorder of function in which very little, if any, changes are to be found in the nervous centres; the changes, whatever they are, are very fleeting, and leave little or nothing to be found if by accident *post-mortems* are obtained. In this class one has to consider the cases which, having become delirious or who are suffering from simple mental confusion, are still without any of the grave results of drunkenness, and in these cases little or nothing has been found, though a good deal may be supposed to be changed in the relationship of the cells, so that for practical and dogmatic purposes I have been in the habit of saying that there were three stages in the pathology: first, that in which presumably the nerve-cells suffered temporarily; secondly, that in which the vascular nutrition suffered; and, thirdly, that in which the nutrition of tissues themselves suffered in a degenerating way. In the first group of cases, in which we rather presume than have evidence of changes occurring in the cells, we meet the thousand and one moral perversions, which are so extremely interesting, because this is exactly the type of disorder which is transmitted. The earliest stage of disorder produced by alcoholism in the individual seems to be very nearly akin to that which may be exhibited by the children of drunkards; so that what we look upon as the result of disorder in the nerve-cells in the individual reappears similarly in the offspring of drunken parents. In the second stage, when certainly the nutrition of the brain and nerves suffer, but in which pathologically there is very little change to be seen, one may meet all sorts of exaggerations of these moral disorders, but one is much more frequently struck by the sensory disorders. Here we come to the condition in which we

Digitized by Google

should suppose that neuritis, or the earlier stages of neuritis, occurs. In this class we have patients suffering from hallucinations of vision of various kinds. They may be fully organised, so that the person believes that he is haunted by phantasmagoria, and there are other cases in which there is probably some alteration in the auditory nerve, so that the patient hears either whisperings or whistlings, mutterings or hammerings, so that he believes that he hears the nails driven into the coffin which is being prepared for him, or he hears the tramp of the detective who is still after him; and so with these hallucinations of hearing he is led to believe that he is persecuted. But perhaps the most interesting of all these, because in them all the senses are affected—the most interesting, I say, are the conditions under which the peripheral nerves seem distinctly to be affected. I have seen several cases in which there has been distinct tenderness along the peripheral nerves, and in some of these the patients were sent with the idea that they were suffering from tabes, and, besides the presence of the nerve tenderness, in one case, at all events, there was ulceration about the feet; in these cases with probably early peripheral neuritis one meets insane interpretation of it, so that the patient believes himself to be electrified, galvanised, or pursued. These conditions of disordered function, determined by a disorder of nutrition, may go on still further to the third or stage of tissue change. And I quite agree with Dr. Payne, for in my experience of four *post-mortems* that I have had of cases in which the alcohol has been the starting-point, and in which insanity has ended in death, the one characteristic was wasting of the higher nervous centres, so that brain and cord were both wasted. The calvaria were often marked by Pacchionian bodies. The dura mater was frequently thick and adherent throughout or in part; the arachnoid was thickened and stained with milky spots; there was excess of the subarachnoid fluid and the fluid in the lateral ventricles, and undoubtedly associated with wasting of the convolutions there was pachymeningitis, or in one case there was something which I believe was allied to it—a thin, filmy, serous membrane lining the middle fossa at the base of the skull. Besides, the brain was generally firm with rather an excess of puncta. There is one thing that I should like to have definite information upon. In my experience, whatever may be the condition of the liver, I have never yet seen anything but wasted brain. I ask if there be a condition of enlargement of the brain before the

Digitized by Google

wasting takes place. I do not know, but I doubt it. Another point is that in these cases one has been rather struck, not altogether with the absence of atheroma, but that it was not nearly so pronounced as in some other conditions which were not allied to alcoholism. It is noteworthy, that in some other cases one has had senile wasting of the brain, with acute inflammatory changes ending the scene, just as one may have with wasted kidneys acute nephritis, so that in some of these cases, where there has been chronic alcoholism going on for some time, an acute attack of mania may be the first mental symptom, and may be the last bodily one. The curious question which Dr. Payne has very clearly placed before us is, Is general paralysis of the insane largely dependent upon chronic alcoholism as the cause? Some authorities, and the best English authority undoubtedly, Dr. Julius Mickle, says he thinks it is, but he with his usual candour says the class of cases from whom he draws his experience being old soldiers, therefore the value of his evidence is somewhat discounted.

Dr. Maudsley distinctly says that alcohol probably has some effect, but has only some effect. But in looking at the causation of general paralysis of the insane, one is struck certainly by the fact that it occurs more in races that make use of alcohol. In speaking to surgeons who have lived in the East, they tell me that general paralysis is almost unknown amongst the rice-eating races, but on the other hand it is almost unknown to some races nearer to England. In Ireland, for instance, where I believe there is no absence of alcohol, general paralysis is rare. At all events it seems that alcohol alone is not necessarily a cause of general paralysis of the insane, and I would say that I have looked through the last 103 cases of general paralysis that have been under my care in Bethlem, and of those there were only seven in which there was a distinct history of alcoholism before the onset of general paralysis. I may speak definitely of these cases, for in nearly all of them when the patient was undoubtedly generally paralytic, and there was nothing to hide, one got from the friends records as to the habits and earliest symptoms of the disease. As I say, only 7 per cent. of these cases, or rather seven out of 103, had an alcoholic cause; yet I have no doubt alcohol had some effect in sending more patients to the asylum. Very frequently patients who are losing self-control take to drink, and are then soon sent into an asylum. There are only, perhaps, two or three points further

Digitized by Google

of interest. First of all, a great many observers have been struck with the similarity between general paralysis and the symptoms of drunkenness. And yet it is interesting, as I say, that the number of cases in which we have been able to trace drunkenness as the cause of general paralysis has been small. It seems to me that alcohol is a very unstable sort of poison. It is readily got rid of, and in an organ so well supplied with blood as the brain, the changes are almost always sufficiently rapid to get rid of this poison. On the other hand, certain more stable poisons, such as lead, or certain more fixed conditions, such as local inflammatory changes due to syphilitic disease, are not so readily got rid of, and therefore are much more likely to give rise to general paralysis of the insane. There is another point that I think is of interest, that not only are the symptoms of alcoholism extremely like those of general paralysis, but the aspect of the two is also similar, and thus clinically I have long been in the habit of pointing out some general paralytics who look like beer-drinkers, while others look like spirit-drinkers; there are undoubtedly some general paralytics who through the whole of their course, or nearly the whole, are bloated, fat, greasy-faced people; while there are others who are emaciated, worn, thin, "lean and slippered pantaloons," who have also capillary congestion, particularly about the cheeks. On what do these differences depend? It is of great importance to trace the parallelism between the conditions. To sum up my experience at Bethlem Hospital I have not met with very many cases of insanity ending fatally which depended on alcohol directly.

Dr. Hadden.—What I have to state to-night will be very brief, and will be chiefly as to the effects of alcohol in causing paralysis. My attention was first called to this subject between five and six years ago, when within a very short time we had two cases in St. Thomas's Hospital of paralysis which proved fatal. At the *post-mortem* I anticipated, from the clinical symptoms that they would prove to be cases of myelitis, but on examining the spinal cords I found that they were absolutely normal. Fortunately in one of these cases I had kept the peripheral nerves, and there I found the changes that are now recognised as belonging to alcoholic neuritis or degeneration. Altogether I have had six fatal cases of alcoholic paralysis. Two of these are described in the thirty-sixth volume of our 'Transactions,' three in the thirty-eighth,

Digitized by Google

and one case I have had quite recently. In all the spinal cord was found normal. In five cases I examined the peripheral nerves, and found degeneration, in three parenchymatous changes, in two interstitial mainly. I also examined the medulla in two or three cases and the motor convolutions, and found them normal. The change in the peripheral nerves consisted mainly in the breaking up of the myelin into a finely granular material, the axis-cylinder being obscured. After a time the degenerative products become in part absorbed, so that the fibres have a markedly varicose appearance, and in the final stage the granular matter becomes almost entirely removed, so that the tube is really represented by a collapsed sheath. Such are the lesions that one finds in these cases of alcoholic paralysis; but in examining sections very often one sees, together with these changes, fibres that are normal or very little removed from the normal. At the last meeting I exhibited under the microscope a specimen showing these various changes, together with normal fibres. My impression is, from an examination of these six fatal cases, that the affection is more advanced in the small nerves than in the large ones. Taking an individual nerve, one finds the degeneration is very marked at the periphery, and becomes less and less obvious on passing towards the centre. I may say, however, that I have found the change is very often patchy, one portion of a nerve being almost normal, whereas an adjacent part is very much diseased indeed. I have not examined the nerves for tubercle bacilli; but others have, though unsuccessfully. As regards the muscles, I do not find such alterations as one would *a priori* expect from the change in the nerves. Sometimes the fibres are somewhat granular, the striations being ill-marked, but the most constant feature is an accumulation of round-cells between the muscular fibres, sometimes obscuring the fibres, and sometimes causing atrophy of them. These round-cells result from the proliferation of the nuclei of the sarcolemma, and of the interstitial connective tissue.

In all these six cases the lungs and liver were diseased. In four cases there was very marked phthisis; in one there were miliary tubercles in the lungs, and in one broncho-pneumonia, with softening of some of the patches. As regards the liver, in four cases there was advanced cirrhosis, in two marked fatty change, and in one of these two I found interstitial hepatitis microscopically. In my first two cases of alcoholic paralysis which

Digitized by Google

I observed five or six years ago, the presence of tubercle in the lungs arrested my attention; but when I had three more cases in which phthisis was present, I noticed the association in the second paper in our 'Transactions,' vol. xxxviii. I am inclined to think with Dr. Sharkey that the lung condition is really trophic and dependent upon neuritis or degeneration of the vagus. I may say in conclusion about the nerves, that in all the fatal cases they appeared to be normal to the naked eye; so I think it teaches us the lesson, that because nerves appear normal they ought not to be left unexamined. I confess to be somewhat disappointed at not hearing more about affections of the skin in alcoholic paralysis. I have seen many trophic affections of the skin and nails, both in fatal and in non-fatal cases. I will simply enumerate them: œdema of the ankles; acute bedsores; bullous and vesicular eruptions; erythema of the palms, factitious urticaria, which most certainly came on at the time of the alcoholic paralysis; perforating ulcer of the foot; arrest of growth of nails; and in one case falling out of the nails. In one instance there was profuse sweating, with swelling of joints, which I believe was not rheumatic.

With a view of throwing some light upon the effects of alcohol in the production of kidney disease, I analysed fifty-four fatal cases of cirrhosis of the liver which have occurred within the last few years at St. Thomas's Hospital. In one third of these cases the kidneys were normal; in one fifth they were large, such as Dr. Pitt has described. I think very little reference has been made to the fact, but undoubtedly the kidneys in cirrhosis of the liver are sometimes hypertrophied, the explanation probably being that the kidneys have more work to do in drunkards. In fifteen cases there was interstitial change in the kidneys, but in only seven was this advanced; in the other eight the change was little more than one would expect in persons of adult or advanced age dying from various causes. In eleven cases out of the fifty-four there was disease of lungs, emphysema in six, tubercle in five. Here again it is possible that the pulmonary condition was dependent upon trophic change in the vagus. In addition to these five cases of pulmonary tuberculosis there were also three of tubercular peritonitis. In a significant proportion of the fifty-four cases I found the presence of gall-stones—about one eighth of the cases. As regards the brain, it was examined in several cases, and the changes which Dr. Payne alluded to in his opening address

Digitized by Google

were found; that is to say, the brain was watery, the white matter being œdematous, or the arachnoid fluid in excess.

With reference to the effect of alcohol in causing kidney mischief, I analysed fifty cases of granular kidney, and was surprised to find only one case in which there was cirrhosis of the liver to the naked eye. In five cases there was fatty change. I am far from sure that alcohol has a direct influence in causing renal disease; and as regards gout I am not quite satisfied as to the share alcohol has in its origin. I have examined very carefully the great-toe joints in cases where I have been convinced during life there has been a good deal of alcoholic excess, and I do not think one finds urate of soda in a much greater proportion than in the general bulk of cases.

Dr. Ormerod.—My remarks shall be very brief. First of all, with respect to the specimens I showed on the last occasion, I should like to remark that these were taken from a very typical case of alcoholic paralysis under the care of Dr. Andrew. That patient died of phthisis, and Dr. Hadden has already remarked that that is frequently the case. With respect to that phthisis it appeared to me what one may call an ordinary phthisis. I did not examine the lung for bacilli, but no doubt they would have been found. I may also add that there was extensive ulceration of the trachea and the intestines. Guided by the remarks which I think Dr. Sharkey and Dr. Hadden had already at that period made, I removed the vagi and examined them, both in the neck and where they spread out by the root of the lung, but certainly could find no change in them, so that in that case I think the phthisis must have been independent of any neuritis in the vagi. As regards the other nerves which I examined I think the anterior tibial is the one now shown. This exhibits the usual changes, namely, of the myeline parenchymatous degeneration, breaking up with very well-marked interstitial change. The spinal cord was practically normal, or if the motor cells of the anterior cornua were not quite so marked as they ought to have been, I do not think there was really anything one could lay stress on; in any case I do not think one could lay much stress on changes in these cells as being the means of the production of peripheral neuritis, because I think some specimens, at any rate, show that there is a good deal of inflammatory mischief about the nerve, and I do not see how the changes in these cells could well produce inflammation limited to

Digitized by Google

the nerve; it could, of course, produce degeneration, but that is rather a different matter. Moreover, the clinical symptoms, that is the tenderness of muscles and nerves which occurs early in the course of the complaint, would seem to show that this inflammatory change takes place early, and is not really secondary.

Leaving the question of peripheral neuritis, I should like to direct the Society's attention to another form of nervous disease which is said to be due to alcohol, and I do so because I do not think it has yet received very much attention in England. This was described first, I believe, in von Wernicke's 'Handbook on Cerebral Diseases,' and two cases have lately been added to this by Thomsen, of Berlin, in the 'Archiv für Psychiatrie,' vol. xix, part i. The disease may be briefly characterised as acute ophthalmoplegia accompanied by delirium and other nervous symptoms. The pathological change appears to be a very acute inflammation, so acute as to appear almost hæmorrhagic, which affects the grey matter round the posterior part of the third ventricle and the iter a tertio ad quartum ventriculum. The oculo-motor nuclei appear to be the chief point of selection. The clinical symptoms set in suddenly, and consist of mental excitement not unlike delirium tremens, staggering gait, a sort of mixed ataxia and paraplegia, and delirium followed by somnolence and stupor, with progressive paralysis of the ocular movements, and, I think, optic neuritis has been noted in one instance. Six cases are given by these foreign authors. In four out of these there seems to be very little doubt that the disease was connected with alcohol; at any rate it occurred in patients who had drunk a great deal. Its course was rapid and fatal. I do not know that any case has been recorded in England, but Dr. Suckling, of Birmingham, gives a case of ophthalmoplegia associated with alcohol. In his case it was rather different, because it lasted longer. Most of the foreign cases have died in ten or twenty days, or something like that; but Dr. Suckling's case apparently improved under treatment, the treatment being enforced abstinence from alcohol. In his case there were symptoms of peripheral neuritis, and it is possible the ophthalmoplegia may have been neuritic, not nuclear in origin. I myself have seen one case at Queen Square of ophthalmoplegia which was not altogether unlike Dr. Suckling's. The patient came to the out-patient's room with weakness of limbs and unsteady gait and ophthalmoplegia. This ophthalmoplegia affected both eyes,

Digitized by Google

although not symmetrically—the left was the least affected—and there was ptosis on the left side. There was no history of syphilis. These symptoms had come on during an attack which seemed very much like delirium tremens, in that respect resembling the cases described by the foreign authors. The man did not get any worse, though he did not get well. I think he went out in very much the same condition as he entered. It seems to me that in a case of delirium tremens this complication might occur without recognition, because in such conditions the ophthalmoplegia or any minute symptoms of that kind would be very likely to pass unnoticed, and so possibly the condition may not be so rare, but may only require to be known in order to be detected.

Dr. Isambard Owen.—Dr. Coupland, at the conclusion of the last meeting, asked me if I would add to this discussion some remarks upon the statistics lately published by the Collective Investigation Committee. I hardly thought that this came quite within the scope of the debate, but I agreed to do so the more willingly because a curious sort of myth has grown about the Report of the Collective Investigation Committee, and has been repeated from newspaper to newspaper, not only in this country, but in America, and, for aught I know, in other countries as well. We have been quoted, over and over again, as having professed to establish the conclusion that total abstinence is an extremely unhealthy habit, and that total abstainers on the whole live very much shorter lives, not only than temperate drinkers, but even than absolute drunkards. I think it is hardly necessary for me to say here that no such preposterous conclusion is contained in the Report of the Collective Investigation Committee, and that, in fact, we have categorically declined to formulate any conclusion whatever on the subject of the effects of total abstinence. The Report of the Committee was based upon the records of 4234 cases furnished by 178 practitioners in England and Wales, Scotland and Ireland—chiefly England and Wales. These cases were not taken at random; they were drawn from the Death-Certificate Books of these 178 contributors, and no selection was permitted. The cases were those of the deaths of males aged twenty-five and upwards, taken in order as they came from the counterfoils of the Death-Certificate Books for the last three years, the age at death and the occupation being appended to each, and also the cause of death as stated. The contributor, if his information allowed

Digitized by Google

him to do so, then appended a letter signifying the individual's position upon a scale of alcoholic habits, and also a mark indicating, if his information allowed him to do so, whether the individual had ever suffered from gout or not. The alcoholic scale contained five degrees, lettered respectively from A to E. A signified the total abstainers and E the confirmedly intemperate people, drunkards and hard drinkers. If the individual's position on the scale was doubtful, the contributor was allowed to place him in an intermediate place between the letters, thus making nine divisions altogether upon the alcoholic scale, which were defined as accurately as the nature of the thing admitted of. The results we obtained were chiefly these. In the first place we ascertained the average age at death of the individuals falling in each of these alcoholic classes, from the strictly temperate drinkers of alcoholic liquors down to the drunkards. The average age at death steadily fell degree after degree. In the case of the habitually temperate people it showed sixty-two years and a fraction. In the case of the drunkards it showed ten years less—fifty-two years and a fraction, and the intermediate degrees were graduated pretty regularly in order. The average age at death of the teetotalers, at first sight, was certainly somewhat startling, for it showed only fifty-one years and a fraction, a year below that of the habitually intemperate; but a few minutes' consideration sufficed to explain this curious result, and to show that the average age of the total abstainers could not be properly compared with the average ages shown by the other classes. The teetotalers, as everyone knows, comprise an inordinate number of young people. The average age of living teetotalers is very much less than the average age of the community in general, and therefore one would expect, quite apart from any question of alcohol, that the total abstainers would show a much lower average age at death than any other class. This was made clear by some additional tables, in which we eliminated the cases of deaths under thirty, and again the cases of deaths under forty. In the first of these tables, that excluding the cases under thirty, the difference between the average ages of the temperate and the intemperate remained the same, about ten years, while the difference between the average ages of the total abstainers and the habitually temperate was reduced from eleven years to seven. In the second table this difference was reduced from eleven years to five, thus showing that the apparently

Digitized by Google

startling result obtained was probably due to the difference in the constitution of this class as compared with any of the other classes, and not to any unhealthiness inherent in the practice of total abstinence. Had we had a sufficient number of total abstainers to deal with we could have worked the subject out fully as regards them, and exactly estimated the error that we had to account for; but unfortunately we had so few total abstainers to deal with that we could not proceed any further, and were compelled to leave the question of total abstinence without formulating any conclusion upon it. Then;—taking the other classes from the temperate people to the intemperate, were the differences in the average duration of life due simply to a general depreciation of health by means of alcoholic liquors or to the inducement of any specially "alcoholic" diseases? The former we find to be mainly the case. We worked out the deaths falling into the various classes in a way to show the incidence of each disease in the different alcoholic classes in percentages. We divided the cases first into the young, the middle-aged, and the elderly. For each of these age-divisions we showed the general incidence of the cases in the division in the different alcoholic classes from A to E. We then showed, for comparison with that incidence, the percentage incidence of each disease of which we had a sufficient number of cases to afford any instructive information; and, furthermore, we drew a comparison for each disease between the cases falling in the lower half of the scale and the cases falling in the upper half, thus giving a ratio which could be compared with the same ratio for the whole age-division. The results we arrived at with respect to the different diseases were these: cirrhosis, as might be expected, showed a very marked incidence indeed in the higher alcoholic classes, and so did gout. In both of these affections, if the statistics were to be trusted, there could be no doubt that the production of them was very largely due to the consumption of alcoholic liquors. The only other disease that showed any marked tendency to the upper alcoholic classes was the class of chronic renal disease; but by another table we showed—and this is the point which Dr. Hadden has just alluded to—that the incidence of renal disease in the higher alcoholic classes was due, not to a direct effect of the alcoholic liquor upon the kidney, but to the intermediate effect of the gout which the alcoholic liquor was capable of producing. With regard to malignant disease, it

Digitized by Google

appeared that, if anything, alcoholic liquors possessed the power of checking its development. The cases of malignant disease, of which there were a considerable number, ran rather into the lower alcoholic classes than the upper ones. In the case of tubercle we came to results which perhaps will reconcile the conflicting views that have been put forward upon the subject. It appeared that among the younger people the incidence of tubercle was in the more temperate instead of in the less temperate classes; in the middle-aged it was about normal in each class; and in the old people the incidence was in the higher alcoholic classes, the alcoholic liquor having apparently a checking influence in early life, a predisposing influence in later life, and no special influence in middle life. I may say we had about 600 cases of deaths attributed to tubercular disease. In regard to apoplexy we came upon a somewhat singular result, for, as far as these statistics went, alcoholic liquors were not shown to have had any influence in inducing apoplexy. By "apoplexy" practically is meant cerebral hæmorrhage. The class was a miscellaneous one, but there is no doubt by far the greater number of cases in it were cases of cerebral hæmorrhage. This is a result which I should have thought either a chance one or an erroneous one, had we not had a very large number of cases—as many as 300—to deal with. As regards the other diseases that we were able to deal with, I will only say that alcoholic excess appeared to have no effect in inducing diabetes, no predisposing effect as regards bronchitis, and that it did not appear to have any effect in respect to the mortality in pneumonia or enteric fever.

These, sir, were the chief results which we obtained in our statistics. I will only add one observation more. In these remarks, as in the Report itself, I have been careful to use the words "alcoholic liquor," and not "alcohol," and I venture to suggest that the two terms should be kept very carefully apart in all pathological work relating to this subject. We know perfectly well that there is, at any rate, one disease which is powerfully influenced by certain forms of alcoholic liquor, and very little influenced by other forms. We known that gout is a very rare disease in countries in which whisky is the habitual drink of the people, while it is a very common disease in those parts of our own islands where beer forms the staple drink. The cases in the Collective Investigation statistics come almost entirely

Digitized by Google

from England and Wales, and show the effects of the mingled consumption of beer and spirits; but, considering that, as far as our definite knowledge goes, the effects of these two forms of alcoholic liquor are so different in the production of that very common disease, gout, it should not, I think, be too hastily assumed that the action of all forms of alcoholic liquor is the same in respect to those rarer lesions of the nervous system and of other organs, of which we have had so many examples brought forward in this discussion.

Dr. Bernard O'Connor.—At this stage of the debate I would hesitate to rise, but there is one point which I think has not been touched upon during the discussion. We have been reminded of the series of tissue changes which we all know takes place in the body as the result of alcohol, and reference is frequently made to irritation of organs as the result of the action of alcohol. But it seems to me, sir, that the question as to what is the nature of that so-called irritation, and what the cause of that irritation is, has not been adverted to. I do not purpose to go into the production of certain diseases supposed to have been caused by alcohol, and it is not necessary to refer to what Dr. Owen has just mentioned—the peculiarity with respect to alcoholic drinks as opposed to alcohol itself. It is pretty well known by those who are in a position to speak with authority that among the hop-pickers in Kent delirium tremens is very common, and it is supposed to have been more common in those who drink beer as opposed to spirits. With respect to the production of gout in beer drinkers, I think we have to do with substances other than alcohol. The alcohol in the beer has only a partial effect in producing any gout manifestation. But that is not the point I want to draw attention to now. I think if we look for any explanation at all of the original production of tissue change it must be in the direction of chemistry and I think we may gather some light from the supposition that alcohol is split up, that there is a splitting up of the chemical elements of alcohol, and there is a recombination. Now, most chemists are aware of the fact that any substances which readily take up oxygen have a difficulty in getting rid of it, but there is an exception to that statement, and it is found in the case of the hæmoglobin of the blood. Hæmoglobin readily takes up oxygen, and with equal facility parts with it. It is also known that in carbonic oxide poisoning the hæmoglobin combines with carbonic oxide to

Digitized by Google

form a stable compound. When the hæmoglobin has been thoroughly saturated with carbonic oxide the peculiar property of the corpuscles is destroyed—that of conveying from the lungs oxygen to the tissues. Now, what chemists know to take place in the case of carbonic oxide I think we may—I won't say assume, but at all events attention may be directed to that part in our attempts to elucidate the *modus operandi* of alcoholic poisoning. I think we have to look in the direction of carbonic poisoning and the withholding of oxygen from the tissues of the body.

Dr. D. R. Pearson.—I happen to have had a rather remarkable series of cases of alcoholism chiefly affecting the lungs, and as such cases have not been so much spoken of in this debate I thought it well to bring them before the Society. The first two cases were cases of gangrene of the lungs, and they were so distinctive in their symptoms, that they made a considerable impression upon me. The first occurred about six years ago, and I shall never forget it. She was a most confirmed drinker, so much so that on the day on which she had taken the pledge I was summoned to her, and found her in a helpless state from having drunk four bottles of claret, which she understood did not count. But the second case was more remarkable in its result, and I was fortunate in obtaining in that case a *post-mortem* examination. The commencement of it was very remarkable indeed. The man was brought home in a cab from a public-house suffering from aphasia, and with a white-of-egg-looking discharge, evidently from the lungs, covering his beard, and of a character which was afterwards recognised by those observing the case to be similar to that which frequently came from the lungs. That case terminated with the same peculiar unmistakable odour of gangrene of the lung; but I was very much puzzled at the difficulty of getting expectoration, and also, at the later stages of the case, with the intense sickness and difficulty in swallowing food, even a teaspoonful coming up through the nose. The difficulties of the case rather put me into a position of doubt as to whether I had not a case of abscess of the liver finding its way through the lung, and from this doubt I insisted upon having a *post-mortem*, and was rewarded by finding something which was really worthy of note—that was a gangrene of the lung something like two inches in size, which had attached itself to the gullet; instead of finding a natural opening through the trachea and larynx, actually forcing itself through the gullet, pressure on which gave rise to

Digitized by Google

the difficulty in swallowing. The poor man died exhausted in a few days; but in that case again and again we had those large discharges of white-of-egg-looking fluid from the lung. The case which followed was one of very marked alcoholism in a wife who had attended upon her husband, who had also taken to drink and she herself had fallen into that habit. She came under my charge after she had comparatively given up the habit; but when she came under my charge she suffered from a condition of lung which was at first supposed to be bronchiectasis. She remained under my charge a considerable time, under the view that she was suffering from large discharges from enlarged bronchial tubes. Dr. Powell kindly assisted me in the case, and had very little doubt that there were then enlarged tubes, so much so that towards the end of the case he asked Mr. Godlee to assist us in making exploratory needle punctures, to ascertain if we could not get into enlarged bronchi. We made three explorations without getting into any enlarged bronchi. The patient ultimately died, and I was unable to get an examination. There can be no doubt, if we had had these large bronchi, that in one or other of these explorations, which were all very carefully done under Dr. Powell's eye, some evidence would have been found. In the former cases, in which I had a *post-mortem* examination, although we had these large discharges of white-of-egg-like fluid, we had no enlarged bronchi. Therefore I could not but come to the conclusion that the lung was capable of holding in itself a very large quantity of fluid without having any enlarged bronchi. I think we may find these large quantities of fluid without bronchiectasis. I have a specimen in the other room, showing something of the nature of these cases. This was a case in which a young man twenty-two years of age had a condition of the lung which is also shown under the microscope, and in that case the interstitial tissue is found to be thickened or degenerated, and in one of the bronchial tubes we see the denudation of the tube in its lower end; in that fact I think we have some explanation of the former cases. These cases are cases in which we have a very well known form of morning expectoration and sickness. The lower ends of the tubes degenerate. They hold a large amount of mucus. That mucus does not get expelled till after it fills a certain portion of the tube up to a healthy band of tissue, and in the early morning after rest, when the innervation is greater, or after exposure to cold, we have a flow and an

Digitized by Google

expulsion of mucus, giving quite a different character to the disease from ordinary bronchitis. We have periods of rest followed by expulsion, but nothing like the ordinary bronchitis in these cases of alcoholism which affect the lung.

Dr. Payne, in reply, said: I think, Sir, the Society may be congratulated upon the issue of the discussion on having elicited a considerable number of valuable observations on the morbid changes produced by alcoholism, and as having brought out in a definite form the views held by different members as to their causation. With regard to certain points we have not received so much information as I had hoped. I refer especially to the condition of the tongue, of the gastric and intestinal membrane, and of the skin in chronic alcoholism. Nor with regard to the effect of alcohol on the kidneys has the discussion brought to light any distinctly new facts. The interest of the subject remains concentrated, as it was before, chiefly on two points—the effect of alcoholism on the liver and its effect on the nervous system. Personally, I have to thank those members of the Society who have discussed the subject for the manner in which they have referred to my opening remarks, and for the criticisms which my views have met with.

With regard to the liver, the views which I ventured to suggest as to the causation of cirrhosis have not met with much acceptance. Dr. Lionel Beale, indeed, developed a conception of the process very different to that commonly adopted, regarding it as essentially an atrophy, and denying, or least questioning, any new formation of fibrous tissue. The preponderance of fibrous tissue in certain parts is then explained merely by the absence of liver-cells. With this I confess I cannot altogether agree, since the evidence of new formation of fibrous tissue seems to me in many cases indisputable. The point at issue seems to be rather this: Is the undoubted degeneration and destruction of hepatic tissue to be explained as always a consequence of the fibrous hyperplasia? Are the two changes not often concurrent, or may not the degeneration of liver-cells precede in some cases the increase of connective tissue?

The chief argument against the two latter explanations is that supplied by specimens such as those shown by Dr. Sharkey, in which apparently healthy liver-tissue is seen side by side with masses of newly-formed connective tissue, even in advanced cases of cirrhosis. In answer to this undoubtedly strong argument I would urge, first,

Digitized by Google

that sections mounted in Canada balsam do not always show the actual condition of the liver-cells so well as when the cells are examined in the fresh state, since fat more especially, and also other materials, are removed by the process employed in mounting. I cannot myself recall any instance of ordinary alcoholic cirrhosis in which the residual masses of liver-tissue have not been yellow and opaque from the presence of fat and granular matter in the cells, instead of presenting the normal liver colour. This change, indeed, is so universal that it has given the process the name of cirrhosis or yellow disease. Secondly, it must be admitted that there are groups of liver-cells, and also bile-ducts, which show what are considered to be the signs of health and active life in possessing distinct nuclei, deeply stained by the colouring reagents. But these characters are, I think, seen in a minority of instances, and, arguing from the naked-eye appearances, one would doubt whether they prevail over a large part of the liver.

Moreover, I cannot help suspecting that many of these distinctly nucleated liver-cells may be of new formation, showing a process of repair in the liver-tissue. When a destructive process continues for a long time in a large organ, such as the liver, there is every opportunity for restoration of tissue and the clinical facts of recovery, at least temporary or partial, from cirrhosis, make such a restoration extremely probable. Further, the new formation of bile ducts is a pretty well established occurrence in hypertrophic or biliary cirrhosis, and, as was shown by Dr. Saundby in our 'Transactions,' vol. xxx, p. 301, and by others, may also occur in alcoholic cirrhosis. One of the specimens which I exhibited at a previous meeting shows the same phenomenon, and I believe it to have been alcoholic cirrhosis, though I have not the complete history of the case. If there may be a new formation of bile-ducts, it seems but a short step to new formation of liver-cells, though these appearing as normal elements of the organ would not be generally described as new products. This topic would require more elaborate working out than is possible to-night. I would, however, suggest that the question of repair and restoration of epithelial glandular structures, such as liver-cells, is one which will well repay further inquiry.

Another ground on which I hesitate to accept the view that atrophy and destruction of hepatic tissue are consecutive to and caused by fibrous hyperplasia, is that the cirrhotic liver is not

Digitized by Google

necessarily, as is sometimes assumed, an anæmic organ. It is, of course, obvious that there is a deficient supply of portal blood; but, on the other hand, the supply of blood through the hepatic artery is very copious. This is shown very clearly when the organ is injected after death through the latter vessel. The injection enters easily, and fills the interlobular capillaries very completely. So far as we can see, it is not the anæmia due solely to vascular compression by contracting fibrous tissue which starves and destroys the hepatic cells. In fact, as stated by Rindfleisch, there is a continual extension of the territory of the ramifications of the hepatic artery. I do not, of course, deny that ultimately the newly-formed fibrous tissue undergoes contraction, as is usual with such tissue, like a scar, and compresses the organ generally; only I submit that this is not the only or the primary cause of the morbid changes which occur in the secreting tissue. It may seem, after all, as if there were something wanting to explain the remarkable development of fibrous tissue—this disease appearing as it does out of proportion to the intensity of the local irritation. I would suggest, anticipating a later part of the subject, that something here is due to the simultaneous action of alcohol on the nerve centres, which appears to cause an active hyperæmia of the liver by affecting the vasomotor nerves of the hepatic artery. It is thus that the inflammation is sustained and the hyperplasia is, so to speak, fed.

I need not dwell upon the morbid changes in the brain, which have been so ably discussed by Dr. Savage, and of which some valuable statistics were contributed by Dr. Pitt. I am glad to find that my tentative suggestions as to the causation of general paralysis have been confirmed by Dr. Savage's authority. Dr. Pitt's observations on the production of meningitis, cerebral and spinal, are very interesting. Some years ago I showed to the Society a specimen of acute cerebro-spinal meningitis, corresponding precisely to the description given us of the epidemic form of that disease, in which the occasioning cause seemed to be excessive drinking, accelerated possibly by other circumstances.[1]

With respect to alcoholic paralysis, which has lately received so much attention, there seems to be a general consensus among all observers that the main morbid change is peripheral neuritis; and that changes in the spinal cord, if present, as they were in one of Dr. Sharkey's cases, are comparatively rare and exceptional. I

[1] 'Pathological Transactions,' vol. xxi, p. 7.

Digitized by Google

might, however, have drawn attention to the valuable paper by Dr. Handfield Jones, published in the 'Practitioner' for December, 1871. In one of his cases undoubted softening of certain parts of the spinal cord was detected by Dr. Lockhart Clarke.

Under the head of Neuritis we have had examples of both the changes to which I directed attention, namely, a parenchymatous degeneration of the nerve-fibres, and interstitial inflammation of the fibrous structures of nerves, sometimes combined, sometimes met with singly. Although it is impossible to say which of these changes is the primary one, it would seem on the whole probable that, as remarked by Dr. Finlay, the degeneration is the earlier, and the interstitial inflammation the secondary change.

My view of the actual causation of these changes in the nerves has been criticised by Dr. Buzzard, whose authority in matters of nervous disease requires that his remarks should be seriously weighed and considered. And I may first repair an omission in my opening remarks by referring to Dr. Buzzard's own important observations on alcoholic neuritis in his lectures on peripheral neuritis. Dr. Buzzard does not think that these changes in nerves can be due to the direct action of alcohol upon them. He contends that the morbid changes are confined almost entirely to the peripheral terminations of nerves, while the spinal cord, nerve roots, plexuses, and proximal portions of nerve-trunks have been found, as a rule, perfectly free from such changes. As regards the spinal cord and nerve roots this is, as I have said, universally admitted; but as regards nerve-trunks and plexuses, I cannot agree. In speaking of peripheral nerves I meant to speak of nerves as a whole, not of their peripheral extremities, and, as a matter of fact, numerous specimens were shown at our last meeting of changes in large nerve-trunks, such as the popliteal; and in internal nerves, as the pneumogastric and phrenic. Moreover, I am able this evening to show a specimen which is still more conclusive, namely, one of alcoholic neuritis of the sacral plexus. It is a section made in the pathological laboratory at St. Thomas's of a specimen sent me by Dr. Crooke, of Birmingham, who has unfortunately not been able to be present at our meetings. Nor do the recorded observations refer chiefly to terminal portions of nerves. On the contrary, I have been able to find hardly any records of changes in cutaneous nerve endings; which might be an interesting subject for inquiry.

Why alcohol should affect the brain and the nerves more than

Digitized by Google

the spinal cord we do not know, but surely such an irregular incidence on different parts of the body is the rule in the action of toxic substances generally, both as regards their functional and their structural effects. Morphine, strychnine, and curare circulating in the blood will each select a different portion of the nervous system for its specific functional action; and the same is the case with tissue poisons, such as lead and the diphtheritic virus, each of which has, as its special seat of election, a certain part of the nervous system. The same law might, I believe, be established in going through the whole series of toxic nerve inflammations. Doubtless the ultimate explanation of these variations must be some difference in the chemical composition of the several nerve tissues, if we did but know what their chemical composition is.

Dr. Buzzard's own view is, that the changes in the nerves are secondary to alterations produced by alcohol in the vaso-motor centres of the bulb and cord, which, by causing either contraction or dilatation of the arteries, lead to anæmia or hyperæmia respectively in different parts of the body; the consequence of the diminution or excess of blood-supply being in the one case degeneration of nerve-fibres, in the other case inflammation.

In discussing this hypothesis we must consider the two cases of vascular constriction and vascular dilatation separately. As to the first, I confess I find it difficult to attach much importance to this cause. All our knowledge of the action of alcohol on the nerve-centres goes to show that it never acts as a vessel-constrictor, as is shown by, among other facts, the lowering of arterial blood-pressure which it produces. It can hardly be admitted, therefore, that it can set up so extreme a degree of anæmia as to result in degeneration of tissues. It is true that the action of alcohol on capillaries and small vessels, when directly applied to them, is constrictive, as we see in its styptic effects; but such a mode of action would be local, not remote, and, if it occurred, would show that the alcohol was actually on the spot and capable of acting directly on the tissues; so that this cannot be what Dr. Buzzard means. Vascular dilatation, on the other hand, is a well-ascertained result of the functional action of the nerve-centres, having for its consequence active hyperæmia of external and possibly of internal parts of the body. Such hyperæmia, if persistent or frequent, will be undoubtedly, as Dr. Buzzard contends, a predisposing cause of in-

Digitized by Google

flammation, putting the tissues into such a state that they are easily affected by any injury. Hence the proclivity of alcoholic subjects to some forms of inflammation, bronchitis, pneumonia, certain skin affections, and so forth. But it is noticeable that, according to Dr. Lauder Brunton, alcoholic intoxication destroys the sensibility of the vaso-motor centre to reflex impressions, so that certain injuries produce less effect than in health, and reflex hyperæmia, which is probably a frequent source of disease, will not come into play.

I have suggested also that this kind of hyperæmia has some share in the causation of cirrhosis of the liver. But the question is whether it will have any special tendency to produce inflammation of nerves. One serious objection to this hypothesis is, that the long nerves, such as the pneumogastric, the phrenic, or the chief nerve-trunks of the limbs, pass through several vascular territories, the supply of which is not controlled by any one set of vaso-motor nerves; take, for instance, the sacral plexus and the plantar nerve of the foot, supplied by very different sets of blood-vessels. Another objection is that in the part of the surface where alcoholic hyperæmia is most marked, namely, the face and head, alcoholic neuritis is rare. Finally, the analogy of the other forms of neuritis produced by various toxic substances, such as lead, arsenic, copper, or by specific diseases, in which the histological characters are the same as those of alcoholic neuritis, though the vascular disturbances are wanting, supplies a strong argument in favour of the toxic action of alcohol. These agents also exert the twofold action which I have attributed to alcohol, namely, of producing parenchymatous degeneration and interstitial inflammation. I would refer as another instance to the action of lead salts on the kidney, the first result of which is epithelial degeneration, the secondary and ultimate change, interstitial nephritis. On the whole, I submit that the general result of the facts adduced is in favour of what I may call *the toxic theory of the action of alcohol on tissues.*

Regarding the symptoms of alcoholic paralysis as due to injury of nerves, I would just draw attention to a certain sequence of the morbid phenomena, in which alcoholic changes and those produced by other poisons are alike. In the case of muscle-nerves, the afferent or sensory fibres seem more easily affected than the motor fibres. Hence loss of muscular sense, producing ataxia, characterises the slighter cases of alcoholic nerve disease. Now, a similar ataxic

Digitized by Google

condition has been observed in the neuritis of brass workers (Suckling) and in diabetic neuritis. The symptoms of slight diphtheritic nerve poisoning (in which the knee-jerk is lost) are of the same kind. In all of these diseases, if the action be more intense, the motor fibres are affected and paralysis results. The cutaneous nerves may be considered as analogous to muscle-nerves, but as having a large afferent or sensory element, and a comparatively small efferent element which is partly motor in its function, partly trophic. The sensory fibres are affected first, and in slighter degrees of the neuritis; their lesion giving rise to the sensory symptoms already referred to. When the injury is more severe, the efferent fibres are affected, the result being trophic changes in the skin such as have been referred to by Dr. Hadden and others.

Dr. Buzzard's remarks on the meaning of the word "neuritis" and similar names of diseases are interesting, and it is satisfactory to find that Professor Kontos confirms what I believe has been the generally received explanation of their etymology. It is at all events that given in Liddell and Scott's lexicon for the etymology of pleuritis and some similar words. But there can be no doubt that these words are now technical terms used in the special sense of inflammation, and most of them, like neuritis itself, have been coined in modern times for this purpose, so that it seems doubtful whether we could press their strict etymological sense as a guide to their use. But to discuss the point at greater length would, perhaps, lead us too far from our main subject.

With regard to the very important question as to the connection of tubercle with alcoholism, I think it will be generally agreed that all recent contributions to the subject tend to show that this connection is a real one, at least as regards pulmonary tuberculosis. This disease was present in most fatal cases of alcoholic paralysis, and, in a proportion of cases, of cirrhosis of the liver, too large to be accidental. Dr. Sharkey's ingenious suggestion that a lesion of the vagus nerve may, by lowering the nutrition of the lung, predispose it to be the nidus of the *Bacillus tuberculosis*, deserves to be remembered. I would add that impairment of the function of the vagus will also lead to inadequate removal of mucus from the bronchioles and air-cells. At all events the inaccurate impression that habits of alcoholic excess are in any way antagonistic to tubercular disease must be regarded as swept away.

It would occupy the time of the Society needlessly were I to refer

Digitized by Google

to all the topics which have been brought forward in these meetings. But when the facts and arguments adduced by various members come to be printed in a permanent form, they will be acknowledged, I think, to form an important contribution to our knowledge of the subject. The general outcome of the discussion seems to be: (1) that structural, as distinguished from functional, disturbances due to alcohol used in excess have more importance than has generally been assigned to them; (2) that the action of alcohol has, at all events, more resemblance to the action of mineral poisons than we have been accustomed to think. The corollary which I would venture to draw on my own responsibility is that these injurious effects are produced in a preponderating degree, or almost entirely, by concentrated forms of alcoholic drinks. The practical conclusion, if I am right, would be that the injuriousness of an injurious quantity of alcohol is almost in direct proportion to the degree of concentration in which it is ingested. But for these conclusions I must not make the Patholological Society responsible.

The *President.*—I almost wish, gentlemen, that time had not advanced so far that I might have more strongly than is possible to me expressed the satisfaction which I think all of us feel at the debate which has been raised on the subject of alcoholism. The mere fact that it has been a very temperate debate on the ordinary results of intemperance, shows an example which should be followed everywhere. And if I might mention another thing which has been shown to a most remarkable degree, it is the amount of uncertainty which is left upon every subject of this kind when it is discussed by men who have considered it seriously, and are competent to form an opinion upon it. The contrast between this discussion and the positive statements on all these subjects by those who know comparatively little of the matter, is a thing upon which we may most entirely congratulate ourselves, and I do not think the Society can express too strongly its thanks to Dr. Payne for having introduced this subject which has led to a discussion so admirable.

Digitized by Google

XI. MISCELLANEOUS SPECIMENS.

1. *Fœtal cretinism.* (*Card specimen.*)

By J. H. Targett, M.S.

This fœtus was born between the seventh and eighth months of intra-uterine life. The father was a drunken sailor; the mother a small, cachectic person, suffering from chronic laryngitis, which was considered to be syphilitic. Her first child was healthy and lived, the second was still-born and deformed about the hands and body, the third was a healthy male; then followed two miscarriages; a fourth full-time healthy child, and fourteen months later the fœtus which forms the subject of this communication. For three or four years before this last confinement, ever since the birth of her third child, the mother's health had always been bad.

Examination of the specimen.—The limbs are very short and stunted in their growth, and much out of proportion to the well-developed trunk and head. There is an abundance of subcutaneous fat. On the nape of the neck is a multilocular cyst, which does not communicate with the interior of the skull. The palate is partially cleft. The long bones of the limbs are much deformed, particularly those of the lower extremity. The shaft of the femur is slightly curved and markedly flattened, the sides so formed looking forwards and outwards, and backwards and inwards. Its epiphyses are greatly enlarged and composed of soft cartilage, but there is no centre of ossification in the lower end. The bones of the leg are similarly altered. In the upper extremity the lower end of the radius and the upper end of the humerus are most affected, and their shafts are short, like the femur. The scapula is small, with very round margins; the pelvis flattened, and its cavity very triangular. The clavicle is quite normal, and nearly as long as the humerus and femur. The spine and ribs appear normal. A section of the base of the skull shows centres of ossification in the basi-sphenoid and basi-occipital, but they are not

Digitized by Google

larger than normal. At the junction of the exoccipital and supra-occipital there is an enlargement of the cartilage resembling that found in the lower end of the femur, but the foramen magnum is normal. Bones of the face normal. The thyroid and thymus were quite healthy on microscopic examination.

Sections of the epiphyses of the femur and humerus showed a very irregular line of ossification, and a complete absence of the characteristic row-formation. In some parts the cartilage-cells were large, swollen, and undergoing mucoid degeneration; in other places the cells appeared unduly small and angular. The ingrowth of fibrous tissue at the line of ossification, which has been described by some observers, was wanting, but there were many strands of connective tissue running through the entire epiphysis, which appeared to accompany vessels from the periphery. A certain degree of cupping of the extremity of the diaphysis was noticeable, which was due to extension of the process of ossification over the margin of the epiphysis. The bony tissue of the diaphysis, away from its extremities, was normal. Thus the appearances are identical with those of fœtal cretinism as described in preceding volumes of these 'Transactions,' but they fail to throw light on the etiology of this curious lesion. The specimen is preserved in the museum of Guy's Hospital. *May 21st*, 1889.

---

2. *Dermoid cyst of lumbo-sacral region.*

By Leonard Wilde, M.B.

[With Plate XXVI.]

Charles B—, aged 23, was admitted into the London Temperance Hospital, under the care of Mr. Holthouse, complaining of a tumour in the lower part of his back which had ruptured.

He gave the following history:—At the time of birth a small tumour was noticed at the bottom of his back, which was the same colour as the surrounding skin. As the patient grew, so the tumour increased in size, but was always soft and never caused him any inconvenience. As long as he can remember, this swelling has

Digitized by Google

Digitized by Google

Fig 1

Fig 2

S. S. Copeman, del.

Danielsson & Co, chromo lith

Digitized by Google

EXPLANATION OF PLATE XXVI.

To illustrate Mr. Leonard Wilde's specimen of Dermoid Cyst of the Lumbo-sacral Region (Page 386.)

FIG. 1 shows the general character of the cyst before incision.

FIG. 2 the interior of the cyst.

Digitized by Google

Digitized by Google

never been smaller than a hen's egg. After he has lain upon it for some time he has experienced a sensation of pins and needles.

Five days before his admission into the hospital he found his bed and shirt saturated with a colourless fluid, which had escaped from the tumour through a small perforation in its upper part. This oozing continued during the day, and occurred at intervals until his admission. In the meantime the tumour had been incised by a doctor under the impression that it was a sebaceous cyst, and a large quantity of sanguineous fluid escaped.

On admission the patient presented the following condition:— Over the lumbo-sacral region of the spine was a pendulous tumour about the size of a turkey's egg, measuring 4 inches in diameter and 13 inches in circumference. The bulk of the tumour was situated to the left of the median line. The upper limit corresponded to the spine of the fifth lumbar vertebra, its lower border extended to near the tip of the coccyx. The skin covering it was wrinkled, red in colour, and coarse in appearance, and a few crisp hairs were scattered over the surface, and in the sulcus, indicating the junction of the cyst with the surrounding skin, there was a crop of coarse hairs.

The general appearance is well shown in the accompanying drawings (figs. 1 and 2). There was a small opening in the cyst wall from which some offensive sebaceous matter exuded, and at the lower part of the cyst there was a slit made by the doctor shortly before his admission. Next day this incision was prolonged so as to expose the interior of the cyst, and its contents, consisting of putrid foul-smelling sebaceous matter intimately mixed with hairs, were evacuated.

The cyst walls were lined with skin furnished with hairs and sweat-glands, for on watching the walls drops of perspiration were easily detected exuding from the pores.

Next day observations were made on the tactile sensibility of the cutaneous lining of the cyst, and it was found that he could correctly localise pricks made with a pin upon the internal walls; indeed the sensation seemed to be as acute as on the surrounding integument of the back. Four days later the whole of the cyst was dissected out, and it was found to rest upon the fascia lumborum, and had no connection with the spinal canal. The walls of the cyst were very vascular, and, in those parts exposed to pressure, were

Digitized by Google

half an inch in thickness and were of the toughness of hide. In all other respects the patient appears well formed.

I have ventured to bring this case under the notice of the Society on account of the extreme rarity of dermoid cysts in this region, and of the difficulty of diagnosing them from spina bifida tumours.

February 19*th*, 1889.

---

3. *Dermoid cyst near knee.* (*Card specimen.*)

By J. H. Targett, M.B., M.S.

History.—Louisa F—, aged 38. The tumour was first noticed at the age of twenty-four, and it has grown slowly ever since, without causing any inconvenience.

On admission there was a large lobulated swelling on the outer side of the right thigh, just above the knee-joint, measuring eight inches from above downwards and nine inches across.

On removal the tumour was found superficial to the deep fascia, but firmly adherent to it; it was not attached to the skin. It consisted of three large cysts (the largest being about the size of a turkey's egg), and several smaller ones, all of which freely communicated one with the other. They were filled with a yellow pultaceous material and flakes of epidermis.

Microscopic examination of the cyst wall showed that it was composed of true skin, with a well-marked papillary layer and a very thick coating of epidermis, but no hairs or glands were found.

November 20*th*, 1888.

---

4. *Cysticercus cellulosæ from human muscle.*

By H. Betham Robinson, M.B.

E. H—, aged 4, came to me at the East London Hospital for Children in June, 1888, with a small swelling on the back. This had been present for two years, when first noticed being the

Digitized by Google

Digitized by Google

EXPLANATION OF PLATE XXX.

FIG. 1.—To illustrate Mr. Targett's paper on a Dermoid Cyst of the Thigh. (Page 388.)

A drawing of a microscopic section of the wall of a dermoid cyst of the thigh, exhibited at the Pathological Society early in the present session. Under $\frac{1}{6}''$. It represents true skin, with well-developed papillæ and much heaped-up epidermis, but there is an absence of hair and glandular structures.

FIG. 2.—To illustrate Mr. Roger Williams's case of Neoplastic Process in Trees. (Page 446.)

Digitized by Google

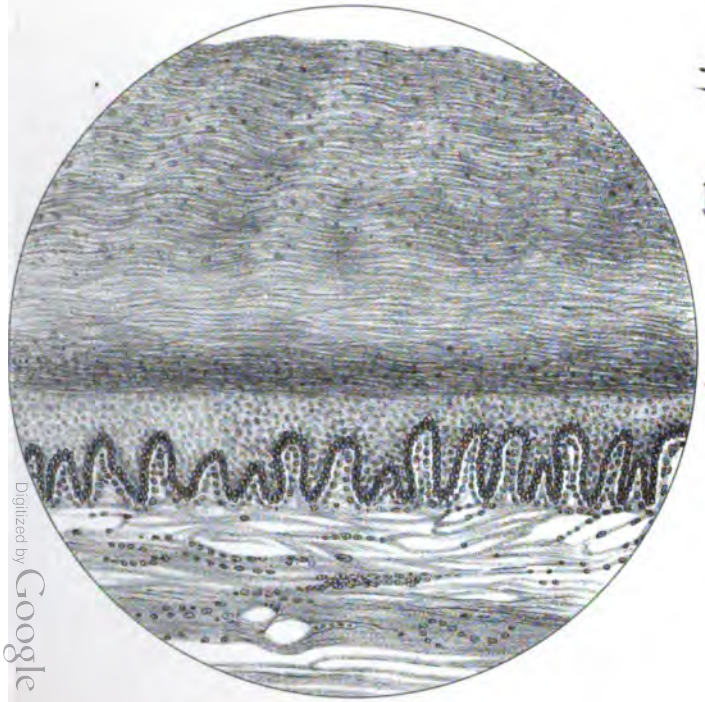

Mintern Bros. lith.

Digitized by Google

Digitized by Google

ize of a pea. During the two months before it had increased rapidly.

The lump was about the size of a large gooseberry, tense, elastic, and fluctuating. The skin and subcutaneous tissue were quite free over the swelling, which seemed to have a deep attachment. It was situated two inches external to the spinal column, and about one and a half inches below the angle of the right scapula. There was no redness or pain.

On dissecting down on the swelling it was found to be in the substance of the trapezius muscle. On incising this a small transparent cyst escaped with some thin purulent fluid. The cyst wall, with the surrounding muscle, was then removed. This on examination was seen to be made up of well-developed fibrous tissue, with a granulating layer lining its interior. The cyst itself, which had been free in the interior of the cavity, was globular, transparent, and about the size of a Barcelona nut. Passing down into its interior from one spot was a thickened cord, which was the retracted head and neck of the cysticercus. The fluid was lost, and so not examined.

There was no history at all to be obtained of the presence of tænia. There were no other lumps about the body.

The cyst is identical with the "measle" of pork, only a little larger in size. I think there is no doubt it is the *Cysticercus cellulosæ*, as the only other cysticercus known to infest the human body is *Cysticercus tenuicollis*, which is very rare indeed.

Although cysticerci are common in the human subject in Germany they are comparatively rare in this country. They are said there to be often present in muscle, as well as in the brain and subcutaneous tissue, their usual situations.

There has been no previous case shown at this Society of a cysticercus from muscle; in fact the cases recorded are very scanty indeed, being only four in number.[1]

There is another point of interest, viz, the length of time that the scolex remained alive. It is said, when the scolex is dead, its head and neck project from the cyst, and it then undergoes calcareous degeneration. As these features are absent we may reasonably infer that the scolex was alive at the time of removal, two years after it was first noticed. Cobbold[2] says that the cysticerci

[1] *Vide* 'Trans. Path. Soc.,' vols. viii, xiv, xxxvii.

[2] *Vide* "Art. Cysticercus," 'Quain's Dict. of Medicine.'

Digitized by Google

are short lived, eight months being amply sufficient for the setting in of calcareous changes. Stich, as quoted by Fagge,[1] states that the life of the scolex within the tissues lasts from three to five years, but after the latter date the cysts are found to shrivel up. This case, then, undoubtedly negatives Cobbold's statement, and favours the observation of Stich. *April 16th*, 1889.

---

5. *Perforating ulcer of foot.*

By A. Marmaduke Sheild.

The specimen showed the anterior half of a right foot, with a perforating ulcer in the sole, and extensive sinuses leading from it in various directions. The bones were not carious, nor were the plantar nerves microscopically diseased. The epidermis was hard, corneous, and leathery in both feet. The specimen was removed by the "sub-astragaloid" amputation from a gentleman aged fifty. He had been a free drinker, and had suffered from syphilis. The integuments of the palm of the hands were also thickened and diseased. Chronic albuminuria and pulmonary emphysema were present. His pupils acted to light, the reflexes were feeble, but not lost. Sensation in both feet was dull. Incipient ataxy was suspected in that the patient had a marked sense of insecurity in the dark, was the subject of burning pains in the limbs, and had led a life conducive to the production of chronic nerve disorders. The operation resulted in an admirable stump, and the general health greatly improved. *March 9th*, 1889.

[1] *Vide* Fagge, 'Principles of Medicine,' vol. ii, p. 218.

Digitized by Google

6. *Tubercular abscess of the breast.*

By Samuel G. Shattock.

History.—R. F—, aged 21, admitted into Elizabeth Ward, St. Thomas's Hospital, May 19, 1888, under Mr. Mackellar, to whom I am indebted for leave to record the case.

Parents alive and in good health. The patient has three brothers and three sisters. Her father and one of her sisters have suffered from "fits," and she herself has been subject to the same. There is no history of tubercle in the family.

Six years ago she first observed a lump in the left breast the size of a hazel nut. It has been now and again painful for the past few months, especially after any exertion and at night. About twelve months ago glandular enlargement was noticed in the axilla. Catamenia fairly regular.

State on admission.—A rather delicate-looking, anæmic girl, fairly well nourished. There is a tumour somewhat larger than a hazel nut at the upper and outer angle of the left mamma, close to the inferior border of the pectoralis. It is movable on the subjacent parts; the skin over it is not reddened, and dimples on being raised.

The swelling appears to be connected through the medium of a hard cord with the enlarged gland in the axilla. No fluctuation is obtainable. The disease was surmised at the time, by Mr. Battle, to be tubercular. Mr. Mackellar made an incision about three inches in length, from over the tumour up into the axilla, and then incised the tumour *in situ*, opening an abscess which contained a small quantity of thick pus. The tumour was then removed together with the adjoining portion of the breast, and several axillary glands.

The largest of the glands presented on section several caseous nodules just commencing to soften. The wound, which was dressed antiseptically, healed rapidly. The part removed (other than the lymphatic glands) consists of a sector of the breast, in the periphery of which is the cavity of an abscess, 2 cm. in diameter, and of which the wall is of fungating granulation tissue, more prominent in the recent state than after preservation in alcohol.

Digitized by Google

Histology.—The wall of the abscess is in section 2 mm. in thickness, and constituted by granulation tissue, in which lie giant-cells, conspicuous by number and size, but scarcely any tubercle systems; the giant-cells, that is to say, occur in the midst of tissue already in the early fibroblastic or epithelioid stage, but there is no group of elements around the giant-cells different in form from the general tissue, and no difference in the peripheral disposition of the elements to mark any proper tubercle systems.

The granulation tissue is irregularly and freely infiltrated with small and more deeply stained round-cells, but these bear no relation to the giant-cells. On the deep aspect the granulation tissue is further developed; its cells are spindle shaped and arranged parallel with the surface of the abscess; and this tissue merges still more deeply into the glandular substance of the breast and pertaining fat, both of which exhibit a certain amount of leucocytic infiltration, most marked around the acini, a few of which are blocked with small cells, but without any multinucleated elements.

In the limitary spindle-celled tissue are a few well-differentiated tubercle systems, some of the simplest kind, others more complex, larger, and including more than a single giant-cell. A section carried through the whole of one of the divided surfaces of the sector removed shows signs of slight chronic inflammation, but no tubercles or giant-cells. The histological characters of the lymphatic glands are those of typical caseous tubercle.

Remarks.—Tubercular disease of the breast is usually regarded as a pathological condition of extreme rarity; but rarity here, as in many other cases, is apparent rather than real, and arises from the condition having been overlooked. Sir Astley Cooper, in his 'Illustrations of the Diseases of the Breast' (1829), has described, under the term "scrufulous swelling" (chap. viii), cases that most clearly come under the category of tubercle. It is a curious fact, however, though not without many parallels, that, notwithstanding the clear description of Sir Astley Cooper's, the subject of mammary tubercle has been altogether overlooked by British observers. There is, so far as I am able to ascertain, but a single case to be found in modern English literature, and that is one briefly recorded by Dr. Hebb; so briefly, indeed, that were it not that it is published in the Society's 'Transactions' (vol. xxxix) it might very excusably be overlooked.

Digitized by Google

The subject is altogether ignored by Mr. Birkett in his article in 'Holmes's System' and in his work. In the latest (9th) edition of Erichsen's 'Surgery,' edited by Mr. Marcus Beck, it is mentioned under a distinct heading, but no cases observed, either by the author or the editor, are given, and it is referred to as being a very rare lesion. Mr. Bryant ('Diseases of the Breast,' 1887) has a chapter transcribed from an article by Dr. G. Durrant, in Gaillard's 'Medical Journal,' of New York, June, 1884, and there is an article on the same subject in the American 'System of Gynecology and Obstetrics,' vol. ii, by Roswell Park. Gross ('System of Surgery,' vol. ii, 6th edition) gives no information other than that abscess of the breast may be of a strumous nature. I submit, however, that the rarity of the condition is not so great, and that closer histological and bacteriological examination are alone needed to materially add to the sum of recorded cases. If we accept as fairly near the truth the dictum that every chronic abscess, strictly so called, wheresoever occurring, is tubercular, it must be admitted, I think, that tubercular disease of the breast, in one of its forms at least, cannot be so remarkably rare. And not only is it certain that this will prove to be the case, but it is equally certain that some of the cases which pass as chronic mastitis, unaccompanied with suppuration, will have in future to be placed in the same category. From a pathological point of view there is nothing special in tubercular disease of the breast. As in other situations, its extent of distribution varies, as do its terminations. It may be localised to a small area, and produce a fairly circumscribed induration, which may persist clinically without much change, and pathologically may pass through the stages of caseation, calcification, or fibrous transformation. Or the localised lesion may soften, and, without any signs at any time of inflammation, produce an abscess, as in the instance reported, whilst in other cases the infection is less circumscribed, and comes to involve a considerable part of the breast, the resulting abscess and tortuous sinuses which tunnels the indurated tissue offering a picture almost characteristic of tubercular disease. And, as in other organs, a generally disseminated miliary form doubtless occurs, though it does not seem to have been yet observed. If we turn to foreign literature—French and German —mammary tubercle is not only well recognised and described, but it has a bibliography extensive enough to show that it can no longer be regarded as an extremely rare disease In this regard tuber-

Digitized by Google

culosis of the breast is much like actinomycosis, and, like actinomycosis, it is a much more common condition in cattle than in man.

Tubercle of the udder in the cow has been for some time known, and its hygienic importance appreciated by Continental observers. In 'Virchow's Archives' (Bd. 70, 1877), Kolessnikow, of St. Petersburg, has fully described and beautifully figured the histology of tuberculosis of the cow's udder, the demonstration of the bacilli being (in 1877) of course wanting. After the identity of bovine tuberculosis or Perlsucht with the human disease was definitely established by the crucial methods of Koch, the hygienic importance of the subject naturally engaged attention. That the milk from a tuberculous udder contains bacilli has been demonstrated by many observers; and the infective property of such milk has been shown in various ways upon animals by ingestion and by subcutaneous injection. Both Bang,[1] and recently Crookshank, have shown this by the latter method on rabbits. And there can be no reasonable doubt that human tuberculosis may be contracted from this source. Koch writes ('Ætiology of Tuberculosis,' 1884), "It is certain that the milk of tuberculous cows may give rise to infection." But he admits the difficulty of demonstrating this in particular cases in the following sentence: "Common as tuberculosis due to inhalation is, the mode of infection can be fixed with scientific accuracy in only relatively few cases. Much less will this be possible in the considerably rarer cases of intestinal tuberculosis resulting from the consumption of the flesh or milk of cows with Perlsucht, because here the uncertainty will be still more increased by the ease with which other and commoner modes of infection may be mistaken for the true one. It is therefore much to be doubted whether a single case of tuberculosis in the human subject will ever be referred unquestionably to the partaking of the flesh or milk of tubercular animals."

Woodhead has referred the mesenteric tubercle of children to the consumption of infected cow's milk.

The question of infection, through the medium of tuberculous milk, has such a distinct bearing on mammary tuberculosis in the human subject, that I may refer to one other of its aspects. The milk from a tuberculous udder is infective. But is the milk from

[1] International Medical Congress, Copenhagen, 1884, 'Deut. Zeitschrift für Thiermed.,' 1885.

Digitized by Google

a cow affected with Perlsucht infective if the udder is not diseased? This important question is still undecided.

Galtier, of Lyons[1], obtained in 1879 only negative results from the subcutaneous injection of such milk into rabbits. Koch's opinion is (loc. cit.) that unless the udder itself is diseased, the milk will contain no bacilli and is not infective.

Bang (loc. cit.) has combated this statement of the case, but as the evidence he adduces is limited to a single experiment it is of course not final. But it is unnecessary to proceed further on this ground, especially as Professor Crookshank[2] has quite recently studied the subject both histologically and experimentally, and has recorded his results in a form which will shortly be officially made public. In the cow mammary tuberculosis may be primary or secondary; and the same is true in the human subject. The disease may result from a direct inoculation of the glandular substance through the medium of the ducts, or of the interstitial tissue by means of a fissure of the nipple; or it may arise secondarily in the course of tuberculosis affecting some other organ, as the lung, in which case it goes without saying that the prognosis is less favorable.

In Dr. Hebb's case, the patient, a woman aged 39, had had eight children, five of whom are stated to have died of tuberculosis, and she herself had been under treatment for phthisis for many years and had frequently suffered from hæmoptysis. The disease of the breast took the form of a hard nodule, about the size of a Spanish nut, in the upper and outer part, and in the substance of the left mamma; it was centrally close to the nipple, which was much retracted, and extended upwards and outwards for one and a half inches, and was about three quarters of an inch in width; there were a few indurated cords extending towards the anterior fold of the axilla, but no enlarged lymphatic glands. No recurrence had taken place four months after removal. In this case it is by no means plain that the disease of the breast was secondary in the strict acceptation of the term, *i. e.* metastatic. From its closeness to the nipple and the fact that in one or two places the tuberculosis

[1] 'Congrès pour l'étude de la Tuberculose chez l'homme et chez les animaux,' 1 ser., 1888, p. 81.

[2] "Tubercular Mammitis in Cows, with Experiments relating to the Injectivity of the Milk; and Remarks on the Tubercle Bacillus," Appendix to the 'Report of the Agricultural Department for 1888.'

Digitized by Google

seems to have primarily involved the ducts, it is equally possible that the patient, by some easily conceivable accident, directly infected her own breast through the nipple. In the case I myself report, nothing satisfactory can be said in regard to the source or mode of infection.

From what is known of the comparative pathology of mammary tubercle, it will be evident that in the case of the human subject the secretion from a tubercular breast may infect an otherwise healthy infant, that is an infant born of healthy parents. If one or other parent is tubercular, the problem becomes too involved for satisfactory solution. Perhaps the most telling case is one cited by Nièpce. A tubercular nurse, whose milk contained bacilli, took a child born of parents who were quite well; the infant died very rapidly of tubercular meningitis. The practical inference of this is obvious, and it applies of course equally to cases in which the nursing mother is affected with tubercular disease of the breast, though in the latter case, even if this source of infection is removed, others may still remain.[1] It is a noteworthy fact that very little evidence is adducible to show that tubercular lesions are ever congenital. This subject is well discussed by Lannelongue (Études exp., &c., sur la Tuberculose; prém. fasc., 1887). He cites many cases of early tuberculosis, but in none would it be easy to say that the interval between birth and death has been too short for the lesions to have arisen from post-natal infection. Demme has found at the antopsy of two infants, twenty-one and twenty-nine days of age, in one intestinal tuberculosis, in the other a tuberculous vomica in the lung; Baumgarten would explain all cases of infantile tuberculosis as due to post-natal infection. That pre-natal lesions *may* occur cannot be denied, for Johne has seen in a fœtal calf of the eighth month taken from a slaughtered cow, typical tubercle and bacilli in the liver and lungs, the cow itself being affected with pulmonary tubercle (cited by Landouzy and Martin in the first fasciculus of 'Études expérimentales, &c., sur la Tuberculose,' 1887). The rarity of congenital tubercular lesions is paralleled by that of the congenital syphilitic. In both cases the hypotheses which may be advanced by way of explanation are many, and it would be to digress too far from the subject in hand to discuss them.

[1] As to whether the milk from a tuberculous person in whom the breast is not diseased is infective, the same unsettled question arises as in the case of the bovine disease.

Digitized by Google

Lastly, in the history of tuberculosis, Laennec's definition was to some extent superseded by Virchow's; but it may be submitted that Virchow's no longer includes, as a definition should, the whole of what is to be defined.

Under the word tubercle a certain disease is identified with a particular anatomical lesion. But it must be allowed that the disease may exist without the lesion implied by the term. Howsoever the existing terms are modified, the same inaccuracy remains, but this is unimportant so long as the real state of the case is recognised. Tuberculosis may exist without tubercle.

Whether we understand by the term tubercle the larger masses of caseous tubercle, or miliary tubercle, as by consent defined, a tissue may be tubercular without the presence of tubercle. It was on this account that the tubercular nature of the synovitis in white swelling was so long overlooked.

If we examine with the naked eye even stained microscopic sections of the swollen synovial membrane from such cases, no tubercles can be discerned, or they can barely be discerned. There are tubercles present, but they are unrecognisable by the naked eye, and with such the thickened synovial membrane is strewn. The simplest tubercle system constituted by a central giant-cell with its enveloping group of epithelioid, and, it may be, beyond this of smaller cells, is practically a microscopic object.[1] But call *these* tubercles, and it is still true that tuberculosis may exist without tubercle.

The histology of tuberculosis, in short, may be confined to a diffuse inflammation accompanied with the presence of giant-cells, the bacilli being of course present in the inflamed area. In the case of mammary tuberculosis under consideration this is to some extent true. It is equally true sometimes of synovial tuberculosis. It may be true of lupus, as I have pointed out in a previous account of a case in the Society's 'Transactions,' vol. xxxviii, p. 410.

In Kolessnikow's figures (loc. cit.) of mammary tuberculosis in the cow it is equally true; there are giant-cells in abundance, but no proper tubercle systems. Crookshank's latest observations (loc. cit.) show the same thing. There may be, therefore, tuberculosis apart from the presence of tubercles; that which is alone essential

[1] It is the aggregations of such which appear to the naked eye as miliary tubercles.

Digitized by Google

to constitute a tubercular lesion is, as Koch observes, the presence of the tubercle bacillus.

I cannot refrain here from pointing out the parallelism between the histological lesions of tubercle and those of syphilis.

The caseous tubercle is the counterpart of the caseous gumma (by the naked eye it is sometimes impossible to distinguish between them). The diffuse tubercular inflammation is the counterpart of the diffuse syphilitic inflammations unattended with the formation of gummata; and in the one disease, as in the other, the two forms may be combined. What is more, there are miliary gummata as there are miliary tubercles, and they are found sometimes in the midst of diffuse inflammatory tissue,[1] or closely aggregated and confluent (to follow Cornil and Ranvier's account—Pathological histology), and so producing the larger macroscopic gummata, as miliary tubercles produce, by their confluence and their caseation with that of the intervening tissue, the larger caseous tubera of tuberculosis.

The diseases are much alike, and, though it counts for nothing, the bacillus of syphilis (so far as it is yet justifiable to accept it) is much like that of tuberculosis.

Bibliography.

Sir Astley Cooper (1829), 'Illustrations of the Diseases of the Breast.'
Nelaton (1839), 'Thèse d'aggregation.'
Berard (1842), 'Diagnostic differentiel des Tumeurs du Sein.'
Velpeau (1853), 'Traité des Maladies du Sein et de la Région Mammaire.'
Johannet (1853), "Diagnostic des Tumeurs Cancéreuses et Tuberculeuses du Sein," 'Thèse de Paris.'
Léger (1878), 'Bull. Soc. Med. d'Amiens.'
Klotz (1879), 'Archiv f. kl. Ch.,' Bd. xxv.
Richet (1880), 'Gazette des Hôpitaux.'
Dubar (1881), "Des Tubercules de la Mamelle," 'Thèse de Paris.'
Le Dentu (1881), "Tubercules de la Mamelle," 'Rev. de Chir.,' i, p. 27.
Ohnacker (1882), "Die Tuberculose des Weiblichen Brustdruse," 'Arch. f. kl. Ch.,' xxviii.
Duret (1882), 'Tuberculose Mammaire et Adénite axillaire.'
Poirier (1882), "Le Tubercule du Sein chez la femme et chez l'homme," 'Archives de Médecine,' Jan.
Verchère (1884), "Des Portes d'Entrée de la Tuberculose," 'Thèse de Paris.'
Orthmann (1885), "Ueber Tuberculose der weiblichen Brustdruse, mit besonderer Berücksichtigung der Reisenzellenbildung," 'Virch. Arch.,' Bd. c.

[1] See a case of syphilitic perihepatitis by Dr. Sharkey in the Society's 'Transactions,' vol. xxxiv.

Digitized by Google

Charrin et Karth (1885), "Virulence de la Tuberculose suivant les tumeurs et les tissus des tuberculeux," 'Rev. d. Méd.,' p. 659.

Billroth (1886), *Billroth u. Lücke*, 'Handbuch der Frauenkrankheiten,' Bd. iii.

Niepce (1886), 'De la contagion, de la transmissibilité de la Tuberculose.'

Piskacek (1887), "Ueber Tub. der Brustdruse," 'Med. Jahrb. N. F.,' ii, pp. 613 648.

Allot (1887), "Contrib. à l'étude de l'hypertrophie mammaire dans le phtisie pulmonaire," 'Th. de Dort, Paris,' No. 225.

Babes et Haberern (1888), quoted in 'Le phtisie pulmonaire,' par H. Hérard, V. Cornil, V. Hanot; sec. edit.

Hebb (1888), 'Pathological Soc. Trans.,' London.

May 21*st*, 1889.

---

7. *Microscopic specimens of tuberculosis.* (*Card specimen.*)

By F. J. Wethered, M.D.

1. '*Giant-cell system*' *in tubercle of tongue.*—The fibrillar network round the giant-cells is very clearly marked. Tubercle bacilli were found in other specimens lying in the giant-cells.

2. *Infiltrating tubercle of lung.*—This was obtained from a case of rapid phthisis. The bacilli are present in huge masses, and considerable destruction of lung-tissue is shown.

3. *Miliary tubercle of liver* (monkey).—This specimen was obtained from a monkey operated on by Professor Stricker, of Vienna, to show localizing lesions in the brain; he died of miliary tuberculosis. The bacilli are present in large numbers and are seen chiefly lying round a large vein.

4. *Miliary tubercle of kidney* (monkey).—Obtained from same animal. The bacilli are seen lying in S-shaped colonies; a form very rarely seen in sections. *February* 19*th*, 1889.

Digitized by Google

8. *The formation of mucous cysts in the mouth.*

By W. G. Spencer, F.R.C.S.

A simple mucous cyst was excised from the inner surface of the lower lip, and vertical sections were made. Three are shown with photographs taken directly from the microscopic sections by Mr. Pringle.

The specimen under the low power shows the dilatation of the main duct of a labial gland to form a primary retention cyst, immediately below the surface of the epidermis and above the junction of two secondary ducts. The cyst occupies partly the position of the epithelium and partly of the submucous tissue. It is covered on its surface by the superficial layers of the epithelium; its wall is formed by small round cells outside which the blood-vessels are dilated. The epithelium on each side of the primary cyst contains a number of small secondary cysts varying in size. The labial gland itself is normal.

Under a high power the formation of the secondary cysts is seen. At one point are natural epithelial cells with the prickles stretched across the intercellular spaces. At another point the intercellular spaces of the epithelium are dilated in a moniliform manner, the

Woodcut 6.

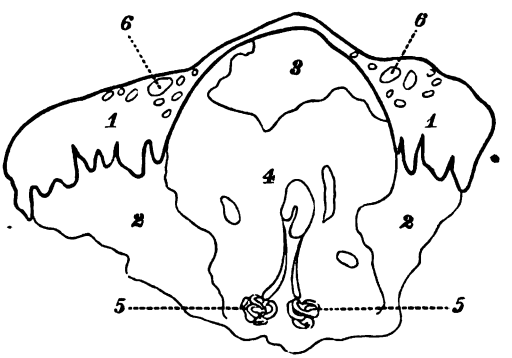

1. Epithelium. 2. Submucous tissue. 3. Cavity of primary cyst. 4. Two secondary ducts from a labial gland obstructed at their junction. 5. Labial gland. 6. Secondary cysts in epithelium.

prickles being still stretched across many of these dilatations.

Digitized by Google

Between the intercellular spaces so dilated the epithelial cells are in process of degeneration, a hyalin globule of mucin being seen in their substance. In other places the dilated spaces have united to form small cysts, the epithelial cells between them having broken down. The nuclei of the epithelial cells appear to resist this myromatous degeneration longer than the cell substance. For besides granular débris and mucin, remains of cell nuclei are to be seen among the contents of the small cysts. The larger secondary cysts are formed by the confluence of the smaller ones.

The interest of the specimens is twofold, first in illustrating the formation of primary and secondary cysts, and secondly, the fact that these cysts form again after incision, unless, as it is said, the cyst wall is destroyed. These sections show that in the present case the secondary cysts were not formed by the cyst wall, but in the epithelium around the primary cyst.

An explanation of the process suggests itself. The primary retention cyst sets up inflammation in the structures around its wall, and this obstructs the flow of lymph in the intercellular spaces of the epithelium, dilates them, and the cells, having their nutrition diminished, undergo mynomatous degeneration. A similar process takes place in an acute manner, producing a vesicle described in smallpox, but I do not know that the production of cysts by it in a chronic manner has before been noted.

February 19*th*, 1889.

---

9. *Nasal calculus.* (*Card specimen.*)

By Sydney Jones, M.B.

This specimen is one of two calculi removed from the nose of a gentleman, aged 45. On May 31st, 1888, the first calculus was removed from the left nostril, the symptoms remaining persistent. The left nostril was again explored on July 20th, 1888, and the calculus here shown was pushed by long probe from the front on to the upper surface of the soft palate, whence it was removed by the finger. The two calculi were of nearly equal size.

Digitized by Google

The first removed was subjected to analysis by Dr. Bernays with the following result:

Lime	39·77
Magnesia	9·09
Phosphorus pentoxide	37·44
Carbonic dioxide	distinct
Gelatinous matter, dried blood, and moisture	13·70
	100·00

January 15*th*, 1889.

---

10. *Phosphatic concretion from a recto-vaginal fistula.* (*Card specimen.*)

By A. H. Robinson, M.D.

This concretion was removed from a woman 56 years of age. At her last confinement, twelve years ago, she suffered great pain for three weeks, and was eventually delivered of what appears to have been a "mole." Previously she enjoyed good health, and had not suffered from pelvic trouble of any kind. Since that time she lost all control over micturition and was confined to bed 18 months. Two years ago she began to suffer from diarrhœa and tenesmus, occasionally she passed blood, and could not sit without pain. She was forthwith treated for "dysentery." When first seen a month ago, on examination of rectum, a rugged mass was found projecting from its anterior wall, and a similar, but smaller mass was found projecting into vagina from its posterior wall. The patient was anæsthetised and the concretion with some difficulty dislodged into the rectum and extracted *per anum*. Its dimensions were then those of a hen's egg. Its composition is of phosphate of lime and triple phosphate. A vesico vaginal fistula had been formed in the first instance, the concretion had formed during patient's long stay in bed and eventually ulcerated through into rectum.

November 20*th*, 1888.

Digitized by Google

11. *Cast of the right leg from a case of alcoholic neuritis.* (*Card specimen.*)

By D'Arcy Power, M.B.

A cast of the right leg of a woman who had alcoholic neuritis. There is great muscular atrophy, especially of the flexors of the ankle-joint.

From a married woman, aged 31, who had been a heavy drinker. She had loss of power in both legs, and there was no patellar reflex. All the muscles of the legs were wasted, but there was no rigidity. In the right leg faradaic contractility was slightly impaired, and galvanic irritability was somewhat deficient, but the contractions were normal in quantity. In the left leg the faradaic contractility was somewhat impaired, especially in the peronei and tibialis anticus. The galvanic irritability was also much impaired in both these muscles.

The patient had pains in the legs, which came on spontaneously as well as upon movement. There was slight palmar atrophy in the left hand. *December 18th*, 1888.

---

12. *Localised symmetrical œdema.* (*Card specimen.*)

By Stephen Mackenzie, M.D.

A male, aged 28, a barman, but always very temperate. In March of the present year noticed a swelling behind the left ear, and a few days later a similar swelling behind the right ear. In the course of about a fortnight the swelling extended to the shoulders and upper part of arms. The maximum swelling was reached in about a month. Since then the degree of swelling has fluctuated.

There has been at no time redness or pain. The patient is a fairly healthy looking man.

The lower part of the face is swollen, the swelling standing out behind and below the jaw on each side, giving him a "double

Digitized by Google

chin." The neck does not appear so much swollen, and he has throughout been able to wear his usual-sized collars.

The shoulders and upper arms to about three and a half inches above the elbows are greatly swollen, equally on the two sides. The swelling gradually tapers off, so as to give a "leg of mutton" appearance to the shoulders, or the appearance of herculean shoulders and pigmy arms. The axillary folds and skin of chest, front and back, are thick and swollen down to two inches below the nipples, but the exact lower limit is difficult to define.

The measurements of the shoulders, vertical,		right	.	18½ inches.
„	„	„	left	. 18 „
„	„	oblique,	right	. 18 „
„	„	„	left	. 17 „

There are numerous red lineæ atrophicæ in the swollen parts of upper arms. The affected parts feel firm rather than doughy, and scarcely pit on pressure. The shoulders have the feeling of coldness, objectional and subjectional, as compared with neighbouring parts.

There are no abnormal physical signs in the chest. The pulses are equal on the two sides, and 60 per minute. Pupils equal, 5 mm. No swelling of superficial veins or enlarged glands. The urine is 1020, acid, free from sugar and albumen. No changes in fundi. Knee-jerks normal.

The swelling of the lower part of face, at a time before I saw the patient, was so great as to limit the opening of the mouth and prevent mastication (for three days).

Gonorrhœa is admitted, but syphilis denied.

The explanation offered is that the swelling is an œdema of vaso-motor origin, but as to the condition that has brought this about there is no evidence to offer. *December 4th*, 1888.

---

13. *Actinomycosis of the lower jaw of a heifer.* (*Card specimen.*)

By Samuel G. Shattock.

Preparation in the Museum of St. Thomas's Hospital.

May 7th, 1889.

Digitized by Google

14. *Case of actinomycosis of the liver.* (*Card specimen.*)

By FREDERIC S. EVE.

THE following case was alluded to in an article on actinomycosis I contributed to the *Practictioner* of May, 1888, page 327. At that time the diagnosis was not confirmed, actinomycetes not having been found in the discharge from sinuses; but at the request of the editor a reprint of my paper appeared in the *Veterinarian* of September, 1888, in which I inserted a note stating that the diagnosis had been confirmed by naked-eye and microscopic examination of the liver.

W. S—, aged 60, a sailmaker, came as an out-patient to the London Hospital, complaining of pain and swelling over the hepatic region. He was spare almost to emaciation. I found distinct enlargement of the liver, which extended some distance below the costal margins. In the right hypochondrium a rounded nodule could be felt, which moved with the diaphragm, and appeared at that time to be unattached to the abdominal wall. The swelling was thought to be either a gumma or an abscess, projecting from the surface of the liver. Seven to fourteen days later, on May 11th, 1887, he was admitted under the care of Mr. McCarthy. The patient stated that three months before he began to suffer severe pain in the right side, just under the ribs. Fourteen days subsequently he noticed a swelling, at first painless, but which became painful as it grew larger. He admitted having a sore on the penis some years ago, while abroad as a sailor. There was a tender, softish swelling three inches in diameter in the right hypochondrium. The skin over it was discoloured and œdematous.

On May 12th an incision was made into the swelling, but only soft granulation tissue came away. A drainage-tube was inserted, and the wound dressed with iodoform.

May 17th. Very slight discharge. Skin around opening discoloured and dense. There was slight pyrexia, the temperature rising 1° to 1½° at night.

Iodide of potassium was prescribed, and he was discharged from hospital on May 27th. I readmitted him a week later, on finding that the skin around the incision was undermined, and that sinuses were forming. I laid open two sinuses, one on each side of the opening, and scraped the infiltrated tissues.

Digitized by Google

June 27th. The infiltration of the integuments had increased. Small subcutaneous abscesses continued to form which intercommunicated by sinuses. Pyrexia very slight, the temperature occasionally rising to 100°.

After leaving the hospital he continued to attend as an outpatient, and I ordered liq. hyd. perchlor. and potass. iodid., but without marked benefit. Fresh sinuses formed at intervals, until the right hypochondrium and epigastrium were marked by some six or more openings, from which a thin watery fluid, but no pus, exuded. He suffered no pain. The enlargement of the liver appeared to decrease rather than the reverse. Seeing that antisyphilitic remedies had no distinct effect, and taking into consideration the general aspects of the case, I began to suspect that the disease was actinomycosis, and on several occasions examined the discharge and scrapings from the sinuses for the ray-fungus, but without success. I continued liq. hyd. perchlor in 3j. doses, in the hope that it might retard the progress of the disease. He gradually got weaker and more emaciated, and finally, in March 1888, he became confined to his bed. On visiting him I found ascites, but no other change in the general condition. He died from exhaustion at the end of April.

The friends would not permit a necropsy, but I succeeded in persuading them to allow me to make an incision into the abdomen, through which I removed a piece of liver. This was studded with the characteristic nodules of actinomycosis. They had not undergone softening, and did not present the usual honeycombed structure. Scraping of the nodules showed, under the microscope, the well-known clubs, two or three clubs being often attached to a single filament. Sections made after embedding in celloidin were stained with Plaut's method, and also with fuchsin and methylblue. They were studded with numerous actinomycetes, the circles being large, and surrounded by the characteristic rays or club-shaped bodies (see Woodcut 1). I could not observe prolongation of filaments into the centre of the mass, as I have figured them in Woodcut 2. I did not detect any essential difference between these specimens and those I had examined from oxen (see Woodcut 2). The circles, however, appeared wider, the granular centres more extensive, and the separate centres of growth remained distinct, instead of forming irregular and mulberry-shaped masses.

Sections of the liver stained with Gram's method only showed

Digitized by Google

WOODCUT 7.

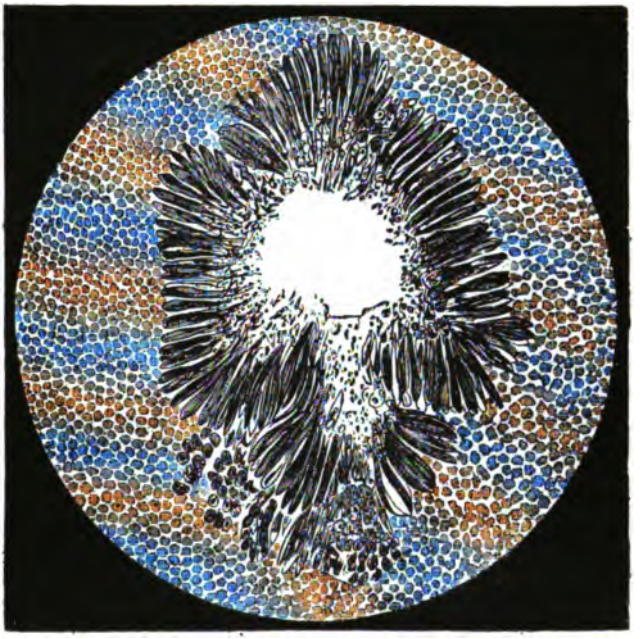

Actinomycosis from human liver. (It is drawn rather too large.)

WOODCUT 8.

Actinomycosis from tongue of an ox, for comparison.

Digitized by Google

beautifully that the centre of each actinomyces was composed of a tangle of delicate tortuous threads or filaments. These passed outwards between the rays (which were also stained), and beyond them into the surrounding granulation tissue, where they terminated in knobs.

These fibres were demonstrated in actinomycosis by Bostrom in 1885; and in 1886 Moosbrugger described and figured the threads and "clubs" together in human actinomycosis. In this country Acland stained threads without clubs in 1886; and quite recently Crookshank has confirmed the observations of the Germans above-mentioned in this particular.

Remarks.—This case appears quite typical of the usual course of actinomycosis, namely, in its slow progress—the duration of the disease being a year and three months; in the absence of acute symptoms, severe pain, or fever; in the appearance of a fluctuating point from which only granulation-tissue was evacuated by incision, and the subsequent formation of numerous sinuses, with undermining of the skin. This combination of symptoms, coupled with the exclusion of syphilis, abscess, and hydatid, convinced me that I had to deal with a case of actinomycosis, although I could not find the fungus during the life of the patient. The pain complained of at the early period of the disease was probably due to local peritonitis, and ceased when adhesions had formed between the liver and abdominal parietes. The organism probably gained access to the liver through the intestine. *May* 21*st*, 1889.

---

15. *A case of actinomycosis hominis.*

By Sheridan Delépine, M.B.

[With Plates XXVII, XXVIII, and XXIX.]

Preliminary remarks.—Dr. Gamgee had promised to give a complete account of the nervous phenomena observed by him during the time the case was under his care. Owing, however, to a sudden illness he has been unable to carry this intention out, and after waiting several months I find myself obliged to take the entire responsibility of a communication which I had hoped might have been a joint one. In order to compensate in some measure

Digitized by Google

for the absence of Dr. Gamgee's observations, I have asked the Registrar (Dr. Sisley) to give me a short abstract of his report on the case. This he has kindly done. By putting together the data which I had obtained from Dr. Gamgee's original communication and those provided by Dr. Sisley, I am able to give the following short clinical sketch. I must, however, repeat that Dr. Gamgee intended to give a much fuller account of the nervous symptoms than I am able here to do.

History.—The patient, a decorator, sixty-five years of age, was admitted to St. George's Hospital, under Dr. Gamgee's care, on the 15th of August, 1888.

In 1887 he suffered from a series of abscesses of the abdominal wall, and was treated during about four months by Dr. Roberts and Mr. Beck at the University College Hospital. After leaving the hospital, and being readmitted once more on account of the formation of a new abscess, he was sent convalescent to Eastbourne. On coming back to London (five or six weeks before his death) the patient had cough, dyspnœa, and pain in the left side of the chest.

Four weeks before his death he noticed for the first time loss of power in the right leg and arm.

On admission (seven days before his death), the man was spare, pale, and looked very ill. He had cough and dyspnœa. The physical signs of effusion into the left side of the chest were present. Several scars were observed on the chest and abdomen. There was loss of power in the right arm and leg. There was no ankle-clonus, no knee-jerk, no loss of sensation, no hyperæsthesia, no reaction of degeneration, no headache. Soon after admission Dr. Gamgee observed an attack of Jacksonian epilepsy affecting the right side of the patient, and lasting five minutes. The clonic convulsions began in the deltoideus and extended down the arm, there being ultimately flexions of the wrist. The leg was less affected than the arm.

Six days before death he had a similar attack lasting three minutes.

Five days before death he was seen by Dr. Ferrier, who confirmed entirely the previous observations, with the exception of those relating to the convulsions (the patient having had no attack in his presence).

Four days before death his chest was tapped, and 8½ oz. of thin, purulent, bloody fluid was drawn off.

Digitized by Google

Three days before death there was an unobserved attack of convulsions.

The day before death the lines under the right eye were more distinct than those under the left, and the right pupil was dilated.

On the 22nd of August the patient became delirious and died.

Post-mortem examination.—The autopsy was made on the 22nd of August, 1888, twenty-nine hours after death, by Mr. W. L. Dickinson. I was also present and am responsible for the following statements.

Note.—Permission had been obtained with some difficulty for the examination of the head and thorax. I was not allowed to remove any part of the skin.

General appearances.—Height of body five feet three inches. Body spare.

I. *External parts.*

1. *Skin.* Numerous scars were found in the skin covering the outer aspect of the right arm, the anterior aspect of the chest and belly, and the left forearm. These cicatrices were most abundant on the right side of the body, and more especially on the outer aspect of the upper part of the right forearm.

Of the several groups of scars found on the thorax and abdomen one deserves special mention. It was situated quite near to and on the right side of the umbilicus. The cicatrices were large, some measuring an inch and a half in diameter, and even more; they were generally rounded, but owing to their close proximity they had in many places coalesced. They were not unlike syphilitic scars; but no deformity of bone nor any genital syphilitic sore could be discovered, even after very careful search.

2. *Hands and feet.*—The hands and feet were distinctly swollen, and this swelling was much more marked on the right than on the left side. On the right side the thumb and big toe were more swollen than the rest of the hand and foot, the swelling being most marked about the small joints.

The right forearm was distinctly swollen. All the parts thus altered were very much smoother than the corresponding parts of the other side.

The *post-mortem* lividity was more marked on the right side than on the left. (Before taking note of these points I carefully ascertained, by examination of the body and by questioning the

Digitized by Google

attendants, whether the body had been lying on the right side, and I found it had not.)

II. *Thorax.*

1. The *left pleura* measured an eighth of an inch in thickness in several places. In the upper third of the chest its two layers were adherent; in the lower two thirds they were separated by sero-purulent fluid mixed with blood, of which about three pints were removed. This fluid on microscopical examination was found to contain a moderate amount of swollen and degenerated pus-corpuscles, a few red blood-corpuscles, and a large quantity of granular débris, chiefly fatty. The surface of the pleura was scraped and the scrapings examined, and were found to be composed of the same elements, *plus* fibrinous shreds. No micro-organism was discovered, with the exception of some which could not be distinguished from ordinary putrefactive organisms (*chiefly micrococci*). The right pleura was also thickened; its layers were united by dense adhesions all over the upper lobe of the lung.

2. The *lungs* weighed, together, 4 lbs. In the left lung the lower lobe was collapsed, the upper lobe congested, œdematous, and indurated. Sections made perpendicularly to its surface, and including the whole of the thickened pleura, showed microscopically the following things:—Serous layer very much thickened, composed of fibrous tissue, becoming very loose towards the surface; this layer contained a number of vessels of old formation. These vessels were distended with blood. The subserous or perilobular tissue was slightly increased in amount. The carbon pigmentation was not unusually great for a man of sixty-five. The interlobular septa were not generally thickened, but there was a small amount of small cell infiltration around a few small vessels. Several of the medium-sized vessels had their intima thickened.

Most of the vessels were distended with blood, and the vasa vasorum formed a very conspicuous network in the adventitia of some of the larger ones.

The alveolar walls were not distinctly thickened. The elastic fibres were very distinct (as they are usually in old age). The capillaries were intensely congested.

The lining epithelium was swollen. Here and there the cells had begun to desquamate and to accumulate within a few alveoli.

Sections through the root of the lung, examined macroscopically

Digitized by Google

and microscopically, did not reveal any trace of granulomatous growths or of abscesses. The lymphatic ganglia were indurated and intensely pigmented (carbon infiltration).

The bronchi were in a state of chronic congestion and bronchitis; their fibrous tissue was increased in amount, and the cartilages were eroded.

3. The *pericardium* was apparently healthy.

4. The *heart* weighed 12 oz. Its muscle was flabby. The mitral valve was slightly roughened and dilated.

III. *Abdomen.*

1. *Peritoneal cavity.*—The peritoneal cavity was apparently healthy. The ligamentum teres was thickened and much congested.

A section made transversely through it, near the anterior border of the liver, showed, under the microscope, intense congestion of the vessels, and great thickening of the serous layer covering it. No special parasite could be found in the folds of the suspensory ligament, except at the junction of its layers with the serous capsule of the liver, in the region which will be more specially described further on.

2. The *intestine* and the *stomach* were apparently healthy; at any rate they did not show any sign of any important lesion. They were entirely free from adhesions, and were only very moderately and uniformly congested.

3. The *spleen* weighed 4 oz., and looked healthy.

4. The *kidneys* weighed 10 oz. together. They were similar in size and general appearance; their surface was slightly granular, and both were congested.

The right kidney, on section, presented in the cortex two small yellow patches; one was situated immediately under the capsule, and projected slightly beyond the surface of the organ. The other was situated more deeply, *i. e.* about 3 mm. below the surface; it was not more than 18 mm. distant from the former. Both these patches measured about 5 mm. in their greatest diameter. The more superficial one was distinctly conical in shape, with its apex turned towards the medulla. The deeper one was irregularly oval.

They were both pale ochre yellow in colour, and looked somewhat granular; they were very sharply defined and firm, but were not surrounded by any distinct capsule. There was no softening of their central parts.

Digitized by Google

Scrapings examined microscopically showed nothing special; granular débris abundant; epithelial cells and spindle-shaped cells. No organisms comparable with those found in the liver or brain could be discovered.

Sections made perpendicularly to the surface of the organ in the region of these nodules were examined with the following results:—The capsule was thickened. Gradually expanding into the superficial nodule referred to above, in the neighbourhood of that swelling the capsule was more cellular than usual, the cells being mostly long and spindle shaped. The superficial nodule projecting over the surface was almost entirely composed of spindle-shaped cells arranged in bundles, crossing each other in various directions, presenting an appearance hardly distinguishable from that of a spindle-celled sarcoma.

The subcapsular layer of the cortex was infiltrated with small cells; this was chiefly noticeable in the regions corresponding to the apices of the medullary rays and, to a lesser extent, to the regions corresponding to the interlobular vessels.

The same small-celled infiltration and a certain amount of interstitial fibrosis were found disseminated through the cortex around some of the vessels and of the Malpighian bodies.

All the vessels, large and small, were intensely congested, and in a number of them leucocytes were more abundant than usual. These leucocytes were very unequal in size and stained more or less deeply. The small ones were more regularly round and stained deeper than the large ones.

In addition some of the vessels contained an unusually large amount of granular matter (some staining deeply with hæmatoxylin). The vessels which contained the greatest amount of that granular matter had generally their coats thickened (chiefly their intima).

A large number of endothelial cells had been shed in many of the arteries, some of which were almost or entirely obliterated by these cells.

The convoluted tubules just under the capsule and in the neighbourhood of the small tumour described above were dilated, a few of them formed cysts barely visible to the naked eye. The largest of these cysts were lined with flattened epithelium; in the smaller ones the epithelium was more transparent than usual, and the nuclei more distinct, but the cells were not much atrophied.

Digitized by Google

Some of the collecting tubules were distended with small proliferating cells.

In the Malpighian bodies the epithelium lining the capsule of Bowman was generally in a state of proliferation. A few Malpighian bodies were found in various degress of atrophy; some had undergone a kind of fibro-hyaline degeneration; these were found in the midst of those patches where interstitial changes could also be noticed. The deeper small yellow patch had a structure very different from that of the superficial one. The arrangement was mainly that of an adenoma. The tubules were much enlarged and irregularly convoluted, lined with very large cells having almost entirely lost the character of renal epithelium, some being like large liver-cells, distended with a large globule of fat, others being columnar. The walls of some of the enlarged tubules were folded so as to form projections into the enlarged lumen of the tube, and being lined with epithelium these convolutions gave to some parts of the nodule somewhat the appearance of a papilliferous cyst-adenoma in way of formation.

5. *The liver* weighed 2lbs. 14oz. On the upper surface, near the anterior margin and to the left of, but quite close to, the attachment of the suspensory ligament of the liver there was a slight antero-posterior furrow, extending as far as the anterior margin of the organ so as to produce a notch in it. The anterior border of the organ was thicker and more rounded than usual. Another shallow depression or groove of the same nature was also found in the middle of the upper surface of the right lobe. Little more than this could be seen before opening the organ; the capsule, however, was very thick and opaque in the region of the groove found on the left of the suspensory ligament, this thickened capsule being continuous with the thickened suspensory ligament already described. An antero-posterior section made just on the left of the falciform ligament, so as to divide the liver in the region of the groove, revealed a large yellow, semi-cheesy and semi-purulent looking lobulated mass. Its buff yellow colour contrasted strongly with the dark purplish, red, congested liver substance surrounding it. It was irregularly oval in shape; its antero-posterior diameter being the longest, and measuring 32 mm., the shorter axis measuring nearly 25 mm. The description of this abscess will be completed further on. A section made in the region of the depression found in the right lobe exposed a number of small, yellow, cheesy-looking,

Digitized by Google

rounded patches, separated by narrow zones of intensely congested liver tissue. The largest of these patches measured about 3 mm., the smallest were not so sharply defined and were hardly visible. On making more sections through the organ, it was found that near the right border there were some very deeply congested areas, presenting the appearance of advanced passive congestion, some looking almost cavernous. These areas were separated by paler strands, looking almost anæmic and feeling somewhat softer than the other parts. The liver generally presented an unequally congested appearance.

The large nodule, situated near the insertion of the falciform ligament, was composed of an anterior portion which was softer and from which pus escaped pretty freely, and a posterior part firmer, and looking more like a mass of large granulomata than like an abscess. After scraping the surface of the anterior portion of the abscess, a small amount of pus was removed and a honeycombed stroma of fibrous tissue was brought out very clearly. The abscess was thus shown to be alveolated, each of the small compartments measuring on an average about 3 mm. in diameter; there were, however, many smaller alveoli. Others were on the contrary larger and evidently produced by the coalescence of several small abscesses. In the posterior portion of the tumour the small cheesy-looking nodules were separated by a larger amount of fibrous tissue or of indurated liver substance, in favorable sections they could be seen to be continuous one with the other, the isolated abscesses being simply the extremities or sections of ramifying tracts, originating at the periphery of the older multilocular abscess described above. These tracts measured from 2 mm. to 3 mm. in diameter, and were therefore quite visible to the naked eye. The liver tissue, through which they advanced, was distinctly indurated and more or less replaced by translucent and congested fibrous tissue. Several nodules of the same kind could easily be recognised in the thickened serous coat of the organ, over the older parts of the abscess. The pus which escaped from the surface of the section, or which could be scraped off from the abscess, contained a number of yellowish white, nearly opaque bodies, very small and just visible to the naked eye; these were generally surrounded by a layer of pus-corpuscles.

Examined microscopically these small bodies were found, as expected, to be typical actinomycetes. The rest of the material was composed of well-formed, rather large pus-corpuscles, many of

Digitized by Google

them arranged in small clumps, in the midst of which fine radiating filaments could be made out even with a power magnifying only 300 times. Under a higher power these masses presented the appearance represented in fig. 1, Plate XXIX. Besides these two forms of actinomyces, and the pus-corpuscles, débris of spindle-shaped cells, of epithelial looking cells, as well as granule-cells, oil-globules, and granular débris were found abundantly. More details regarding the morphology of the fungus will be found further on. Sections of the liver, examined microscopically, yielded the following data:

Falciform ligament: At the place where this ligament joins the liver, and all along its length, this ligament was, as already said, thickened and congested.

The subserous layer was thickened and much congested. It contained a great number of small round-cells escaped from the vessels, and of spindle-cells resulting from the proliferation of connective-tissue corpuscles. The fat enclosed between the two layers was in the same state of congestion and infiltration. No abscess was found in the ligament itself, but at the place where it merged into the capsule of the organ, near the anterior border of the liver, the large abscess already described was found, and the oldest part of that abscess was found near the place where the layers of the ligament separated and became continuous with the capsule. In that region the serous coat was replaced by embryonic myxomatous-looking tissue, very vascular and very soft. In the same region the capsule of Glisson was very unequally thickened; some parts of it being replaced by connective tissue, almost entirely composed of spindle-cells, and not unlike sarcomatous tissue. At the place of insertion of the suspensory ligament this layer was twenty or thirty times its normal thickness, and had evidently invaded the subjacent hepatic tissue. This thickening of the capsule diminished gradually and rapidly, so that at a distance of about two centimetres from the suspensory ligament the capsule of Glisson, notwithstanding its being congested and infiltrated with small cells, was not very much thicker than normal. It was in the midst of that newly-formed connective tissue, continuous with that of the capsule, that the large mass of abscesses was found. A noticeable feature of this tissue was that at the upper and anterior part of the patch, viz. where the lesion was evidently oldest, the partitions which it formed between the various extensions of the abscess were very

Digitized by Google

much narrower than the diameter of the alveoli. These partitions were evidently in a state of infiltration and degeneration, being composed of small cells staining badly, and separated by very little intercellular substance. In the midst of that degenerated tissue a number of leucocyte-looking cells, staining very deeply, and very granular, were found in some places very abundantly. These cells were very much like those filling up the small central cavity of each subdivision of the abscess. Only a few distinct vessels or even bundles of fibrous tissue could be found in those trabeculæ, and the liver-cells seemed to have entirely disappeared. Small hæmorrhages were not uncommon in those regions.

In the younger parts of the tumour, *i. e.* at the advancing posterior margin, the partitions between the alveoli of the abscess were very much thicker than the alveoli themselves. The connective tissue of these trabeculæ was chiefly composed of a large number of large, embryonic-looking spindle-cells. In the midst of that young connective tissue a number of large vessels, many with more or less thickened intima (arteritis obliterans), were found, as well as numerous large and tortuous bile-ducts. These bile-ducts were lined with an unusually luxuriant columnar epithelium; and where these ducts were numerous the appearance recalled to mind the early stages of a columnar adenoma.

The lumen of many of the vessels was occluded by a thrombus or by accumulation of leucocytes or of large oval cells, staining less deeply than leucocytes, about one third larger than them, and evidently the result of proliferation and desquamation of the endothelium of vessels. (This desquamation of endothelium is a process common to a great many states, and I have had more than once occasion to allude to it. The subject has been much studied by Dr. Handfield-Jones. I have reason to believe that it also goes on constantly in health, and that it is an important mode of origin for some of the cellular elements of the blood.)

The vessels which were not occluded by endarteritis or thrombosis were distended with blood, causing congestion of the parts One of the obstructed veins contained a calcareous mass (phlebolith) just visible to the naked eye. No parasite could be found in the concretion. In the midst of this recent tissue the liver elements were not entirely destroyed, but remained between adjacent abscesses in the shape of rows of flattened cells. These cells were, however, in an advanced state of atrophy, produced partly by the

Digitized by Google

collateral pressure due to the growths of the abscesses, and partly to the gradual advance of the connective tissue along the capillary vessels, this part of the process resembling much what is observed in certain varieties of the so-called hypertrophic cirrhosis. (It is to be noted, however, that in this case, as in many of the cases which by their structure are allied to hypertrophic cirrhosis, there is neither apparent nor real hypertrophy of the organ, even in the parts which are most affected.)

The study of the abscess itself was not of less interest than that of the surrounding tissue; its most remarkable feature was its lobulated arrangement due to its being composed of a number of branches or purulent tracts ramifying in various directions from the point where the tumour originally started. It was impossible to discover any relation between that branching and the arrangement of the lobules or the distribution of the vessels or ducts of the organ.

(In the absence of the proofs which I have already recorded, this would almost be enough to support the theory that the abscess was formed in the midst of previously modified tissues.) In each sufficiently large alveolus of the abscess (some of the largest cavities are evidently produced by the disappearance of the septa between adjacent alveoli) one or several typical actinomycetes were found.

It is interesting to note that a large and probably mature actinomyces is multilobulated, and that its shape corresponds very much to that of the multiloculated abscess. One is often misled regarding the size of these actinomycetes by the fact that, owing to their large dimensions, the tips only of the diverging branches are found in certain sections, so that several small organisms may seem to be present in the same large cavity, or even in cavities which are apparently separated one from the other by partitions, and yet both the small abscesses and the typical organisms which they contain may be nothing more than the advancing branches of a large abscess and of the large actinomyces which it contains. It is an unfortunate feature of this parasite that when it has reached a large size the pus immediately round it is generally very soft or non-coherent, so that it is impossible to retain the parasite in microscopical sections without resorting to special technical means (embedding in celloidin).

The form of the organism, which is generally known, was found

Digitized by Google

only in the centre of abscesses of comparatively large size; at the margin of these abscesses and in the small patches of small round-cells preceding the well-defined abscess, no corresponding organism could be discovered.

There were in some of the abscesses small masses of radiating filaments, with few or no clubs connected with them. These were better seen in fresh specimens than in those kept for some time.

These tufts of branched filaments were, however, never found quite at the margin of the abscesses, but, on the contrary, were in the midst of the soft pus filling up some of the older abscess cavities.

In the neighbourhood of the large abscess just described the following changes could be observed:

Nodular patches of small-celled infiltrations of the capsule of Glisson; the adventitia of the bile-ducts was generally the part most affected. The bile-ducts, although never obliterated, showed some signs of dilatation from retention. Their columnar epithelium, as already remarked, was large and unusually distinct. The accumulation of small cells in the coats of the vessels seemed to have caused obliteration of some of them, this process being, of course, helped by thickening of the intima; others were, as already described, in connection with the walls of the abscess, partly or completely obliterated by arteritis obliterans, or endophlebitis (the endophlebitis was not general), by thrombosis, or by desquamation of the endothelium; in some vessels the serous layer of the intima had separated *en masse*, and the blood had passed between it and the elastic lamina, giving thus rise to a kind of laceration, which to my knowedge has not been described, but is apparently of little importance in this case.

The intralobular capillaries and vessels were in many places in a state of intense congestion, quite similar to what is observed in cases of pylephebitis obliterans around the obstructed area.

The liver-cells between the distended capillaries were in various degrees of atrophy and pigmentation. In some regions the capillaries, instead of being distended with ordinary blood-corpuscles, were filled up with degenerated, granular, small round-cells. Young connective tissue formed a sheath round some of these capillaries, and in some places each liver-cell had an investment of connective tissue, so that a distinct intralobular cirrhosis existed in such regions.

Besides the atrophy of a number of cells, inflammatory changes,

Digitized by Google

such as swelling, vacuolation, multiplication of nuclei, fatty degeneration were observed in large tracts of hepatic tissue.

These changes, which have been described in connection with the area surrounding the large abscess, were found also in the two other parts of the organ which have been described as showing distinct lesions. In the upper part of the right lobe the changes were chiefly due to congestion, infiltration, inflammation, and degeneration, and seemed to correspond to the stage immediately preceding the appearance of abscesses.

At the extreme right margin of the organ the changes were chiefly those of collateral passive congestion, such as is observed in the neighbourhood of obliterated vessels. This form of congestion is observed in the liver only when the obliteration of vessels is very extensive, or affects the terminal branches of the portal vein and hepatic artery.

IV. *The cranial cavity and spinal canal.*

1. The skull-cap having been removed the membranes covering it appeared at first sight to be normal. A more careful examination, however, revealed a slight adhesion and thickening of the pia mater in the region of the posterior end of the left upper frontal and adjacent part of the ascending frontal convolutions. There was little superficial congestion visible.

The upper parts of the left ascending frontal and parietal convolutions, as well as the posterior parts of the upper and middle frontal convolutions, were flattened and broader than usual, whilst, naturally, the intervening sulci were partly obliterated. The brain was also much softened in the same region, the softness amounting to fluctuation in the upper parts of the ascending frontal convolution. There the cortex felt as if it were merely a thin membrane covering a large cavity full of fluid,

All this was very much more distinct after the brain had been removed from the cranium than before, and then the flattening of the central parts of the left hemisphere, the softening, and the fluctuation became extremely evident, as well as a distinct enlargement of the same part of the organ.

On passing gently one finger along the inner surface of the left hemisphere one could feel distinctly that the inner aspect of the upper ends of the ascending frontal and parietal convolutions was softened. The marginal convolution was also slightly softened in

Digitized by Google

Digitized by Google

EXPLANATION OF PLATE XXVII.

To illustrate the report of a case of Actinomycosis Hominis by Dr. Delépine. (Page 408.)

This Plate shows the appearance of three frontal sections of the brain (anterior aspect), about two thirds natural size.

(*Note.*—Owing to some accident in the printing, the sulci and internal cavities of the brain are represented as being much larger than in the originals, with this exception, the drawings represent *accurately* what could be seen in the actual sections.)

FIG. 1.—Section through the middle of the frontal lobe. 1. Left anterior cornu of the left lateral ventricle. 2. Genu of corpus callosum.

a, *b*, *c*, *d*, *e*. Small abscesses (described in the text as Nos. 1, 2, 3, 4, 6).

FIG. 2.—Section through the ascending frontal and the ascending parietal convolutions. 1. Ascending frontal convolution. 2. Ascending parietal convolution. 3. Middle commissure. 4. Nucleus caudatus. 5. Nucleus lenticularis. 6. Thalamus opticus. 7. Claustrum.

f. Large abscess (No. 7 in the text). This abscess was exposed by removing a thin slice from the upper part of the left hemisphere. The portion represented above the line * is therefore on a plane posterior to that of the rest of the section.

FIG. 3.—Section through the same convolution as those represented in Fig. 2, but a little further back. 1. Ascending frontal convolution. 2. Ascending parietal convolution.

f. Large abscess (No. 7, text).

g. Abscess (No. 8, text).

Digitized by Google

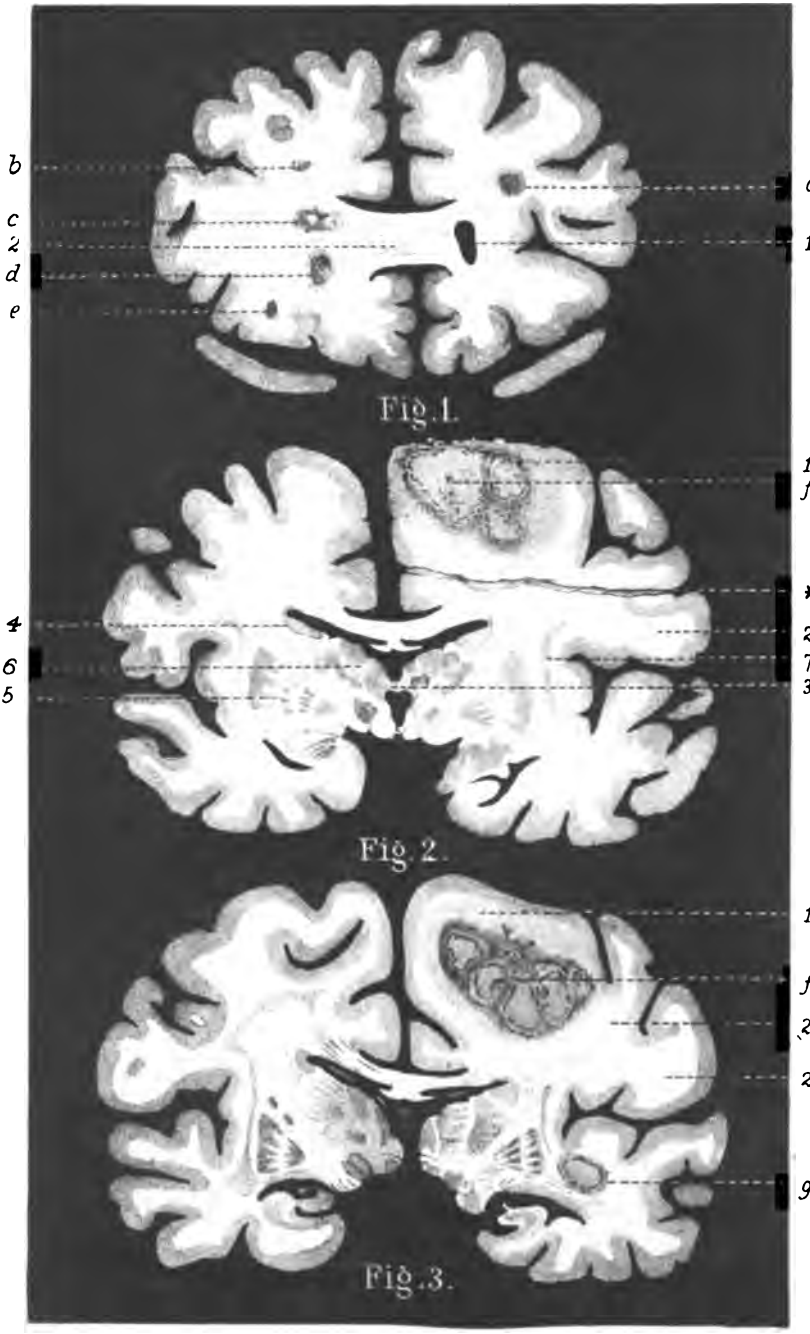

Sheridan Delépine del. (Aug 1888 - Apr 89).

Digitized by Google

Danielsson & Co. lith.

Digitized by Google

front of and behind that region, but the gyrus fornicatus felt quite firm.

The vessels examined, as far as it could be done without injuring the organ, did not show any trace of disease or excessive congestion.

2. *Vertical frontal sections* having been made after preparation of the organ a number of large and small abscesses, in various stages of development, were found in various parts of the brain. The most important of these abscesses was found, as was expected, in the white and grey matter of the upper part of the ascending frontal convolution and adjacent regions. In order to avoid a very lengthy description of these lesions they will first be enumerated, and their most salient features will afterwards be described.

A. *In the right frontal lobe* the following abscesses were found:

(1) At a distance of about 25 mm. from the anterior extremity of the brain, in the white matter underlying the anterior portion of the gyrus fornicatus, a group of small abscesses not softened yet, and measuring about 15 mm. × 18 mm. These abscesses were situated just in front of the genu corporis callosi, their border nearest to the surface being at a distance of 5 mm. from the bottom of the calloso-marginal sulcus.

2, 3, 4. At a distance of about 40 mm. from the anterior extremity of the hemisphere and at the level of the genu, several abscesses were found in different regions of the white matter. They all measured about 5 mm. in diameter. (Plate XXVII, fig. 1.)

(2) One of them was situated at the basis of the middle frontal convolution, its border nearest to the surface was at a distance of 10 mm. from the bottom of a secondary sulcus.

(3) Two small abscesses were found among the fibres of the corpus callosum at some distance from the middle line, their innermost border at about 10 mm. from the median surface of the hemisphere.

(4) Another one was found just under the grey matter of the orbital convolution formed by the reflected second frontal. The border of that abscess was at 4 mm. from the surface of the convolution.

B. *In the left frontal lobe* were found:

(5) One small abscess, 25 mm. from the anterior end of the lobe on the white matter of the upper frontal convolution. Its border nearest to the surface was 5 mm. from the side of the upper frontal sulcus.

Digitized by Google

(6) Another small abscess, 45 mm. from the anterior end of the lobe, situated near the posterior end of the inferior frontal sulcus, and just in front of Broca's convolution. Its border nearest to the surface was 6 mm. from the bottom of the inferior frontal sulcus. (Plate XXVII, fig. 1.)

c. *In the region of the motor areas*, i. e. *the frontal and parietal lobes about the fissure of Rolando*, were found:

(7) A large abscess implicating the upper part of the ascending frontal and ascending parietal convolutions, as well as the posterior part of the superior frontal convolution. Its anterior margin was 80 mm. from the anterior extremity of the brain; its posterior margin 60 mm. from the posterior end of the hemisphere. These measurements were taken after hardening of the brain in Müller's fluid, and in a projection of the lesions on an imaginary horizontal plane. The internal margin of the abscess was not more than 2 or 3 mm. from the surface of the paracentral lobule, its outer border about 35 mm. from the same surface. The abscess measured about 32 mm. from side to side, and 25 mm. from before backward.

Its antero-internal part was much nearer the surface than the postero-external part. In fact, near the anterior border of the upper part of the ascending frontal convolution, the lesion was so superficial that it was almost impossible to discover any trace of unaltered grey matter over an area measuring about one square centimetre. This was the region where the membranes were thickened and adherent. The grey matter of the ascending frontal convolution was either very nearly or entirely destroyed over an area bounded in front by the precentral sulcus, and behind by a line parallel to that sulcus, and 4 mm. further back; above by a line parallel to the median fissure, and distant about 3 mm. from it, and below by another line parallel to the first and about 25 mm. from the median fissure. The grey matter of the immediately adjoining portion of the superior frontal convolution was also destroyed or very nearly so.

This abscess was imperfectly subdivided by partitions of congested and half disintegrated brain tissue into a number of compartments, the largest of which measured about 15 mm. in diameter. This large mass was forming the most internal and anterior portion of the group. Smaller divisions extended backwards and downwards into the white substance underlying the

Digitized by Google

parietal convolutions. These smaller alveoli measured on an average 5 or 6 mm. in diameter. (Plate XXVII, fig. 2.)

D. *Temporo-sphenoidal lobe.*

(8). Another abscess was found at the junction of the temporo-sphenoidal lobe with the basal portions of the brain just behind the insula. (Plate XXVII, fig. 3.)

This abscess was in contact with the grey matter covering the inferior wall of the fissure of Sylvius, quite at the bottom of the fissure. It measured 10 mm. by 5 mm.

This abscess had apparently destroyed some of the fibres passing from the temporo-sphenoidal lobe into the adjacent basal white matter.

3. *Structure of the cerebral abscesses.*—These abscesses differed in many respects from those found in the liver; their walls were thinner and the quantity of pus which they contained was larger. In none was there any typical actinomyces found. All through the pus, however, except quite near the margin of the abscesses, a number of small clumps of pus-corpuscles, with branching filaments radiating from their centre, were found. On searching carefully for a long time a few small clubs were found connected with several of these filaments. These clubs were the result of an expansion of their sheath, just as the more advanced clubs found in the liver. These young clubs, and the complete resemblance between the mycelium forming the central portions an ordinary actinomyces and the mycelium found in the small clumps above described, as well as in similar clumps found in the liver by the side of the more typical organism, made it quite evident that the parasite present in the brain was an early form of the very same organism as that found in the liver. The fresh pus on being removed from the abscess presented the general appearance of moderately thick, creamy, laudable pus.

On spreading it on a glass plate minute clumps could be seen all through it, but they were barely visible to the naked eye, and certainly very much smaller than the ordinary grains found in the pus of actinomycotic abscesses. These clumps when examined with a high power, showed the appearance described above. When compressed carefully, a number of rather coarse branching filaments with a well-marked wavy appearance could be distinctly seen without any other preparation.

The appearance of these filaments was so remarkable that even

Digitized by Google

before the liver had been examined I felt nearly certain that the case was one of actinomycosis. This was confirmed by the examination of the other organs. Near the margin of the abscesses the pus was lumpy, owing to the presence in it of débris of nerve tissue; there were also many small hæmorrhagic foci in this marginal zone.

4. *The brain substance surrounding the abscesses* was much altered; generally speaking the lesions were those of encephalitis, followed at the margin of the abscesses by the production of connective tissue which gradually replaced the degenerated nervous elements. The changes seemed to have occurred in the following order: Intense congestion of the vessels and endarteritis in many of them; mall cell infiltration of the coats, chiefly the adventitia; thrombosis of some of the vessels.

The red blood-corpuscles found in many of the vessels, also those found in the hæmorrhagic patches so common at the periphery of the abscesses, retained the dyes used for staining bacteria very strongly, and often more so than the bacteria themselves.

Some of the small arteries contained also leucocytes full of small granules staining very deeply; some of these granules were elongated and projected beyond the surface of the corpuscle.

In a few vessels bacilli were also found, but it was not possible to ascertain whether they were adventitious products or not. They looked, however, not unlike segments of the more typical filaments found in the abscesses, and were probably early forms of the organism, and it is quite probable that the granules found in the leucocytes represent still earlier stages in the growth. Such observations can, however, hardly be taken as equivalent to satisfactory proofs, and must be received simply as indications of the probable course of things.

The nerve-cells were swollen, their nucleus enlarged, and in some of them had divided.

The grey and white matter were infiltrated with leucocytes, and patches of the nervous tissue had undergone necrosis. It is in the midst of that necrosed tissue that the abscesses seemed to have formed; the walls of many of the smaller vessels had given way, and hæmorrhages had taken place, so that the pus was mixed with blood at places. The connective tissue was increased at the margin of the abscesses.

The growth of the abscesses does not seem to go much faster than the infiltrations and necrosis of the surrounding tissues, so that

Digitized by Google

the abscesses must take gradually the place of equivalent portions of brain tissue. There were, however, indications in a few places of compression of the tissues surrounding the abscesses. This was specially well seen in the scanty remnants of cortex covering some of the parts of the largest abscess. There was also distinct swelling of the affected parts of the organ. As the pus continues to accumulate, distinct mycelial masses begin to be visible and soon acquire the appearance already described.

Thus it is evident that marked inflammatory and degenerative changes occur in the brain before the abscesses appear, and that the abscesses have to reach a certain size before a distinct mycelium of actinomyces can be found in them.

5. *No trace of secondary degeneration could be discovered* in the crura cerebri, medulla oblongata, or spinal cord, although a large number of sections of these various parts had been examined after appropriate staining. There seemed, however, to be some swelling of the axis-cylinders in the crossed pyramidal tract; but at the most this change was very slight and very difficult to prove.

Discussion of the case.

This case presents so many points of interest, even from a purely pathological point of view, that it will be necessary to consider it under various aspects, for

(1) It gives an opportunity to follow the life-history of the fungus known under the name of *Actinomyces hominis*, and to study some of the forms under which it may present itself.

(2) It shows how the various parts of the body may become infected, and what are the various lesions which can be produced by that infection.

(3) The brain lesions are so definite, and have affected such important regions, that the case may be considered as if it were a physiological experiment by which the functions of certain parts of the brain can be determined.

(4) In the study of the case certain technical points have been made out which it may prove useful to discuss.

This multiplicity of aspects is, of course, not special to this case, and it would be easy to find a great many more points of interest in it as well as in other cases, but there are limits within which it is wise to remain, and I must be satisfied with exposing those points which have more specially attracted my attention.

Digitized by Google

A. *Etiological and morphological remarks.*

1. It seems evident that the organism which we know under the name of actinomyces does not penetrate into the body under the form with which we are acquainted. This is not only due to difference of size, but evidently to morphological changes. This is proved by the fact that no actinomyces (I of course use the word actinomyces with reference to the known form only), even of the smallest size, could be discovered at the advancing margin of large abscesses, in the midst of smallest abscesses or patches of infiltration, or in those blood-vessels which showed evident signs of the presence of some irritating material in the blood. A careful study of the pus contained in the large abscesses, and of the contents of the vessels in the parts where lesions are evidently of recent origin, leads me to the conclusion that—

2. Small micrococcus-like spores are produced by the filaments composing the mycelium and the core of young clubs. These spores can easily be seen within and between the filaments, and similar bodies can occasionally be found within the clubs after proper treatment (see technical remarks), and small granules of the same size may also be seen among the cells surrounding the parasite.

3. These spores do not seem to be able to pass easily through the layer of leucocytes which accumulate round the mother organism, and they are apparently nearly all absorbed by leucocytes and the greater number of them destroyed. This statement is not based on any perfectly conclusive direct observation of the facts implied by it, for owing to the constant process of degeneration taking place in the cells and of the walls of the abscesses, the boundary layers of these lesions are full of granules of different kinds, some fatty, some albuminous, and I have been unable to come to any positive conclusion regarding the presence or absence of the spores in these regions. But I have noticed that among the leucocytes surrounding the parasite many were very granular, and stained much deeper than the others. Then I have found a few leucocytes presenting the same appearances in the degenerated walls or partitions of the abscesses, and also in some of the vessels of regions in which changes were beginning to appear. Finally, in young abscesses I have found occasionally a leucocyte in the centre of a young colony, with filaments apparently radiating from it. The difficulty there is in staining these spores differentially has, however, not allowed me to trace them so satisfactorily as I

Digitized by Google

would have wished. There are, however, two forms of collateral evidence in favour of the view which I support here.

(A) It has been extremely difficult to discover any free organisms in more than a few of the vessels, even in those parts where changes were quite manifest (and even when found these organisms were of doubtful import). From this it would appear that the parasite must be carried from place to place by something else than the plasma, and must pass from the vessels into the tissues without having necessarily escaped into the plasma; hence it seems almost necessary to admit that the spores are carried by the leucocytes. (I put aside for the present transmission of the parasite by the lymphatics, because the lesions in the brain clearly indicate that the blood-vessels may ultimately become the channels of invasion, and it is on the brain lesions that much of what I advance is based.)

(B) The evident passage of the virus through several organs without the formation of colonies seems to indicate that the organism is not freely disseminated through the blood, and yet that it is under a form which can be easily circulated.

4. Besides spores, some potent poisonous material must be produced by the ray fungus, otherwise it would be difficult to account for the extensive changes which may be observed in several organs where no colony can be discovered, and also for the very marked irritative and necrotic changes which precede the appearance of the fully formed actinomyces, or are observed at the margin of the abscesses.

5. The spores having overcome the leucocyte containing them, and finding tissues of vitality lowered by the poison referred to above, begin to elongate and protrude beyond the dead body of their host. These filaments, all growing from a centre, are necessarily bound to radiate from that centre owing to collateral resistance. They soon branch, and in some cases begin to branch dichotomously. The ramifications of Cladothrix filaments are said to be false ramifications, but in actinomyces the branching is most clear and like that which is observed in moulds. At this stage the protoplasmic contents of the filaments can be distinguished from a thin sheath, and it is often possible to see that the protoplasma has subdivided into a number of small spheroidal segments.

6. During the development of these filaments an active fight seems to take place with the surrounding leucocytes. The pus of young abscesses is full of small clumps, composed of a central

Digitized by Google

small radiating mycelium, with, sometimes, a degenerated leucocyte quite in the centre, and a peripheral zone of leucocytes, rendered more or less pyriform by mutual pressure, and staining much more deeply than the surrounding ones. It is perhaps at that stage that the greatest number of spores becomes absorbed by the leucocytes. Some of the leucocytes surround entirely the filaments which they have attacked. The filament seems in some cases to have perforated them.

7. Soon the growth of the organisms becomes more marked in some directions than in others, so that from spherical it becomes more or less elongated, lobulated or stellate. This is probably owing to the unequal resistance offered by the various leucocytes and the débris of degenerated tissues.

8. Meanwhile, the sheath of the filaments becomes more distinct, and around the swollen extremity of some of the filaments it becomes very much thicker indeed, so that a certain number of lateral and terminal filaments assume the well-known club-shape. It must be remembered, however, that this change does not take place in all filaments, and that many of them retain their original form, extending beyond the filaments which have become claviform. The filaments which do not become claviform are evidently the growing ones.

9. The thickened sheath of the clubs soon becomes separated from the central filament through the accumulation of some material apparently fluid or semi-fluid. Owing to this the size of the clubs may become considerable.

10. Ultimately the central filament breaks up into segments and disappears, and the empty sheath remains.

11. Before this stage has been reached it often happens that, in the central portions of a large actinomyces, some calcareous salt becomes deposited. This material is soluble without effervescence in various acids, and is probably of phosphatic nature. As it disappears under the action of the acid the greenish yellow colouration, which the large masses of actinomyces have acquired, disappears, so that the pigment seems to be chiefly connected with the infiltrating salt. The calcareous deposit seems to take place indistinctly within and between the filaments, and is evidently not a structural element, but the result of a precipitation of salts contained in the fluids of the invaded organism.

12. This may account for the differences there are between the

Digitized by Google

Digitized by Google

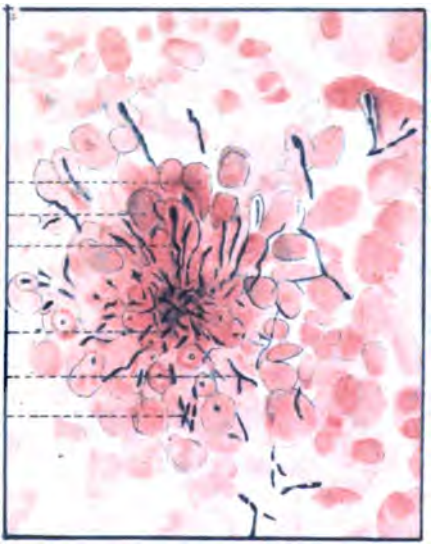

Fig 1

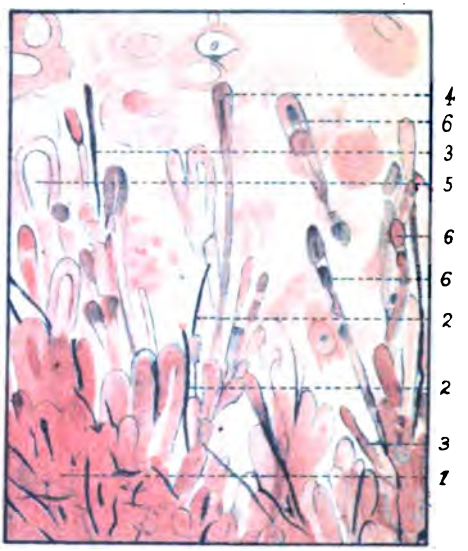

Fig 2



Fig 3

Sheridan Delepine del (March April 1889)

Danielsson & Co chromo-lith.

Digitized by Google

EXPLANATION OF PLATE XXVIII.

To illustrate the report of a case of Actinomycosis Hominis by Dr. Delépine. (Page 408.)

FIG. 1.—A young actinomyces found in the pus from one of the large cerebral abscesses (No. 7). (Stained by the rapid Gram's method described in the text.) × 1100. 1. Pus-corpuscles deformed by pressure, and staining deeper than the others. 2. Filament distinctly clubbed, and covered with a thick sheath (young club). 3. Bacillary form of the organism. 4. Branched filament. (Cladothrix form in its early stages.)

FIG. 2.—Portion of the margin of a medium-sized actinomyces from one of the large hepatic abscesses. (Stained with carbolised fuchsin, and double stained with methylene blue after decolouration by acetic acid.) × 1100. 1. Large clubs, forming the apparent border of the organism. 2. Mycelial filaments, extending beyond the clubs. 3. Mycelial filament slightly thickened at its peripheral end (young club). 4. Mycelial filament, with a thickened differentiated sheath (young club). 5. Large empty club (old club). 6. Clubs broken up into segments, owing to accidental stretching (this appearance has misled several observers).

FIG. 3.—Portion of the periphery of a pretty large actinomyces from one of the large hepatic abscesses. This shows two lobate projections, in one of which (9) the radiating arrangement of the mycelium is well shown. (Stained in weak watery solution of dahlia violet for three days, then treated with Gram's iodine solution and double-stained with eosin.) × 1100. 1. A fasciculus of simple filaments staining badly. 2. A young club with thick protoplasmic core and thin sheath. 3. A young club with thicker protoplasmic core. 4. Older clubs seen from above. 5. Older clubs seen obliquely. 6. Clubs with protoplasmic core segmented and assuming a streptococcus form (note the sheath is neither torn nor deformed). 7. Old clubs with thick sheath and no protoplasmic contents. 8. Free micrococcus-like bodies, varying in size, possibly spores. 9. Portion of the organism where the plan of section passes through the axis of one of the lobate projections, so that the radiating arrangement of the mycelial filaments is better shown than elsewhere.

Digitized by Google

Digitized by Google

bovine and the human actinomycosis. Owing, probably, to the nature of their food the fluids of the body of herbivorous animals contains more calcareous salts than those of the tissues of carnivorous or omnivorous animals, or else their salts are more readily deposited owing to the reactions of the fluids. This is shown by the composition of their urine. Calcareous deposits would consequently take place more readily in the tissues of herbivorous than in those of other animals, and this would account for the greater tendency which the organism has to assume in them the claviform appearance which seems, from what precedes, to be the result of an arrest of growth. This would certainly not account for all the differences, for thick claviform filaments, staining readily by Gram's method, have been found in the midst of giant-cells in the bovine disease, whilst such an appearance is not common in man This, however, might be explained by a difference in the vital activity of the cells. This difference certainly exists, and is well shown by the feeble resistance which some species of animals (chiefly herbivorous) offer to the growth of micro-organisms.

13. It is certainly diffcult to demonstrate the existence of a mycelium in the midst of the calcareous material infiltrating the central portions of the fungus, as found in cattle, but it is often easy to recognise, chiefly in specimens mounted in glycerine, a large number of small spherical granules of about the same size as that of the tapering ends of the clubs.

14. I must allude here to the connection between the *filiform* and the *claviform* varieties of the organism. It has long been known to German observers that both forms may occur in the same case. They have also very early described the way in which the filaments expand to form the clubs. (All these facts had been established more than six years ago.) It was rather unfortunate for English observers that in the first case observed the demonstration of the clubs was a matter of difficulty. Dr. Acland, however, notwithstanding this difficulty, did not hesitate in describing his first case as one of actinomycosis. Dr. Crookshank, in his communication to the Royal Medical and Chirurgical Society, impressed by the discussions which had arisen in connection with this absence of clubs in the cases of actinonomycosis described in England, devoted much time to the demonstration of the existence of clubs in human cases, and was led to affirm that they were present in all cases, thinking probably that in this way

Digitized by Google

the similarity between the human and the bovine actinonomycosis was best established. He confirmed the observations made several years before by Israel, Böllinger, Ponfick, Johne, and others, touching the relation of the filaments and of the clubs. He suggested also that the clubs might be Basidia, from which it might be inferred that the actinomyces belonged to the higher fungi (Basidiomycetes). Now, the importance attached to the clubs on this occasion by Dr. Crookshank is, I believe, not quite justified, and the present case shows well how possible it may be for the filamentous (or mycelial) form to be the only one present in some abscesses.

15. The case also goes very far in proving that in lesions which have not existed for more than five or six weeks clubs are not likely to be found, but that at the end of that time the ends of the filaments are certainly getting club-shaped. (The patient did not show any sign of paralytic trouble till four weeks before his death, and as he was suddenly taken with chest troubles five or six weeks before his death it is reasonable to date from that period the penetration of the parasites into the vessels and its dissemination through the system.) Judging by the size of the large actinomycetes, they would at that rate take several months to reach the size which they had attained in the liver, a supposition supported by the history of the case.

16. As I have alluded to the opinion of Dr. Crookshank regarding the place which the actinomyces should occupy among the fungi, I may as well mention that, although I do not feel competent to discuss a botanical question of such difficulty, I have been struck with the strong resemblance which the organism has to some of the mould fungi generally classified among the *Ascomycetes*. Although from the description I have just given it is evident that I do not believe that the clubs are homologous with gonidiophores, I cannot help referring to the remarkable analogy of arrangement there is between the parts of an actinomyces and those of the sphacelium of a Claviceps (one of the *Pyrenomycetes*). This analogy is better marked when the specimens are examined *au naturel* than after they have been altered and disfigured by the use of numerous reagents. It is difficult to say for certain that the clubs are Asci; some of them contain small bodies which might be spores, and these bodies disappear after a time. Before the mycelial filaments have been stained they look much larger, and their

Digitized by Google

Digitized by Google

EXPLANATION OF PLATE XXIX.

To illustrate the report of a case of Actinomycosis Hominis by Dr. Delépine. (Page 408.)

(*Note.* — All the specimens represented in this plate are magnified 1100 times in diameter.)

FIG. 1.—A *small actinomyces* from one of the liver abscesses (× 1100). (Examined in *Müller's fluid*, unstained.) *a. Young filaments* growing rapidly, after passing through a barrier of cells. *b.* Filaments becoming club-shaped. *b'.* Clubbing of one of the filaments evidently due to arrest of growth in one direction, produced by *mechanical obstacle*. *c.* Large cells probably resulting from the proliferation of *fixed connective-tissue corpuscles*.

d. Pus-corpuscles.

(Note the strong analogy of structure with a mould.)

FIGS. 2, 3, 4, 5.—Portions of a *medium-sized actinomyces* from one of the hepatic abscesses (× 1100). (The specimen had been treated with *fuming hydrochloric acid*, and slightly compressed.)

Fig. 2. Portion of the margin where the clubs are small and distinctly branching. *a. Young clubs, moniliform* in shape owing to teasing. *b.* Much thickened filament forming the base of a number of clubs.

Fig. 3. *Older clubs*, all *distinctly branching* from one filament. *a.* Transverse *segmentation* produced by pressure.

Fig. 4. Part of the *mycelium* composed of branching filaments. *a.* Thickening corresponding to the base of one or several clubs.

Fig. 5. Small clubs, apparently containing small *spores*.

FIGS. 6, 7, 8, 9, 10.—Portions of a *large actinomyces* from one of the abscesses of the liver. (Treated with *liquor potassæ*, and examined in *saline solution*.)

Fig. 6. *Very young club*, formed by thickening of the end of a mycelial filament.

Fig. 7. *Young club*, showing a *sheath* and a *protoplasmic core*.

Fig. 8. *Older club*, with a distinct *space* between the sheath and the central filament.

Fig. 8'. Clubs in the same stage seen obliquely.

Fig. 8''. Branching clubs altered by pressure.

Fig. 9. *Large club* flattened by pressure. *a.* Protoplasmic core, soft and flattened. *b.* Harder sheath, split at several places. *d.* One of these slits. *c.* Space between the core and the sheath.

Fig. 10. *Empty old club*, rendered moniliform by pressure (appearance often mistaken for segmentation and production of conidia).

FIGS. 11, 12, 13.—Actinomyces obtained from pus removed from the *pleural cavity*. (The preparation from which this drawing has been made had been prepared from pus, which Dr. Taylor of the Brompton Hospital had kindly given me; as there was no difference between these specimens and those obtained from the hepatic abscesses, I have not thought it necessary to make two drawings.) Specimen treated by *boiling liquor potassæ*.

Fig. 11. A flattened clump of branched filaments (*mycelium*), with *spore-like bodies between them*.

Fig. 12. Some of the filaments with *spore-like granules* in them.

Fig. 13. *Branching wavy filaments* (Cladothrix), isolated by teasing.

Digitized by Google

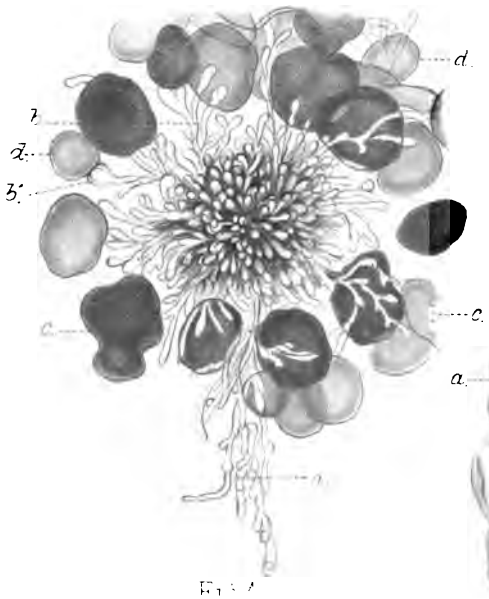

Fig. 1.



Fig. 2.

Fig. 3.

Fig. 5.

Fig. 4.

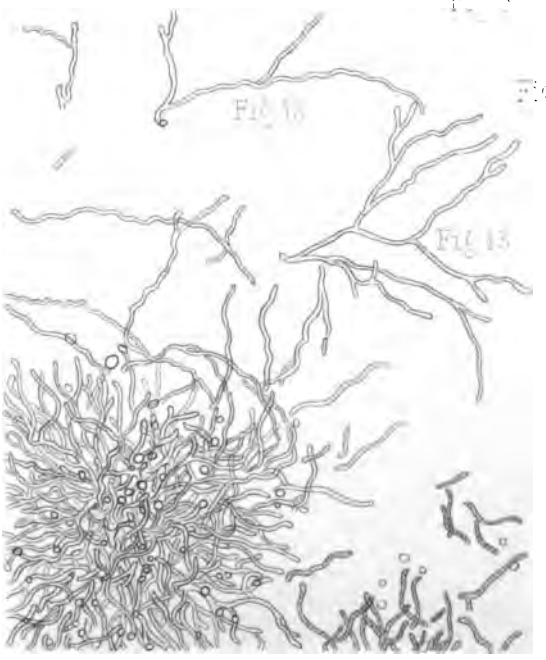

Fig. 11.

Fig. 12.

Fig. 7.

Fig. 6.

Fig. 8.

Fig. 9.

Digitized by Google

Digitized by Google

branching is much more easily observed than after. After staining, their sheath generally becomes invisible, so that the slender protoplasmic core only remains visible. For this reason it is difficult to get an accurate idea of the real appearance of the organism unless it is examined unstained and fresh. Notwithstanding the analogies just mentioned it must be owned that if the actinomyces be a mould, as I believe it to be, it is one the hyphæ of which are of very small diameter. It must be kept in mind, however, that the question of size is of little importance in this case, for it would be difficult to find an organism more polymorphous than the actinomyces. Cocci, filaments (Streptothrix or Cladothrix filaments or hyphæ), and clubs are all exceedingly variable in size and shape. My conclusions on this point are therefore analogous to those of the earliest observers and discoverers of the disease, with that exception, that I believe with Boström and Paltauf that the clubs are the result of an arrest of growth. However it is not certain that they are the result of a degeneration process, and might be considered simply as more differentiated parts, and possibly as equivalent to Asci.

17. I have several times found an organism in the tartar encrusting the teeth and in the crypts of the tonsils, which closely simulates the actinomyces. Lately one of my friends brought me a specimen of that organism removed from his own mouth, a thing which naturally filled him with anything but pleasant feelings, for he knew all about the parasite and the way in which it is supposed to invade the organism. I was, however, able to comfort him very rapidly. The pseudo-actinomyces is composed of filaments radiating from a centre, and a number of club-like bodies are found at the periphery of the mass. When these are treated by hydrochloric acid they are seen to be composed of filaments held together by calcareous salts, and on further addition of iodine they can be proved to belong to nothing else than the simple *Leptothrix buccalis*.

B. *Technical remarks.*

It may be well to follow the description of the parasite by some remarks on the best ways to display its structure:

1. As already remarked by most observers, the clubs show much better in fresh specimens than in stained ones; but it is generally admitted that this is not true of the mycelium.

I found during my investigations that:

Digitized by Google

(*a*) Specimens preserved in *Müller's fluid* showed the filaments and clubs extremely well without further preparations; they lost, however, their sharpness of outline after they had been mounted in glycerine or Farrant's solution. (Plate XXIX, fig. 1.)

(*b*) *Strong acids* are very useful for the demonstration of the structure; fuming hydrochloric acid is by far the best reagent for the study of the morphology of actinomycetes when one wants to demonstrate rapidly the arrangement of the filaments and of the clubs and their connection. One has only to pick out a small clump of pus containing either the young or the fully formed parasite, to add a drop of strong hydrochloric acid to it, and press gently the cover until the specimen becomes sufficiently thin to be examined with the highest powers. The preparation is then sealed to prevent the fumes of hydrochloric acid corroding the brass-work of the microscope. A preparation can thus be obtained very rapidly, and in which more can be seen than when much more elaborate methods are used. (Plate XXIX, figs. 2, 3, 4, 5.)

In preparations of this kind it is not uncommon to find the clubs segmented, or even moniliform. This is the result of pressure, and can be produced at will. Glacial acetic acid renders the clubs very transparent and soft, and they seem at times to be dissolved, but this is generally due to excessive pressure being used.

(*c*) *A* 10 *per cent. solution of caustic potash* is very good also for the demonstration of the mycelium. The clubs at first become so transparent that they are difficult to see, but after a time they become visible again. By using boiling potash the mode of branching of the filaments can be demonstrated with great ease. By all these methods the spores can be brought out, but more specially by the last.

All these rapidly prepared specimens are most useful for the study of the morphology of the actinomyces, and by comparing specimens quite fresh with some acted upon by the powerful reagents just mentioned one is struck by the little alteration which is produced in those parts which can be well seen without preparation. (Plate XXIX, figs. 6, 7, 8, 9, 10, 11, 12, 13.)

2. When permanent specimens are wanted, and one wants only to demonstrate the presence of the organism, nothing can be better than the ordinary histological methods, thus:

(*a*) *Picrocarmine* stains the clubs very well, and filaments may even be seen, though not clearly, after mounting either in glycerine, Farrant's solution, or Canada balsam. Specimens can be

Digitized by Google

obtained thus which are quite as clear and demonstrative as those prepared according to the various complicated methods which have been recommended at various times.

(*b*) *Hæmatoxylin* is also very good, and according to the variety of stain used, or the time taken in staining the specimen, it is possible to leave the clubs unstained or to stain them slightly. Hæmatoxylin sometimes stains the spores; sometimes it stains the mycelium diffusely; sometimes it does not stain it at all.

When the specimens are double stained with eosin, acid magenta, or rubin S., or picric acid, the clubs are almost instantaneously stained red, pink, or yellow, and the contrast thus obtained is very good.

Young filamentous colonies have some affinity for eosin, so that if after a specimen has been stained with logwood it is stained with eosin, all the small colonies will appear in the midst of the blue pus like so many pale yellowish-pink spots, and as the leucocytes surrounding them immediately stain deeper than the rest of the pus, the young organisms are easily discovered, even in a specimen which has been prepared simply for the purpose of displaying ordinary structures.

I insist upon the fact that by ordinary histological methods it is very easy to recognise actinomycetes when they are present in an organ, because it has been said that the parasite had escaped the notice of observers simply because proper methods had not been used to demonstrate its existence. It has even been said on that basis that the disease would probably prove to be pretty common. That it is not quite so rare as was supposed at first is perfectly evident, but it does not seem to me possible that a parasite which is so easy to demonstrate should have escaped the notice of the large number of competent observers constantly at work if it were as common as some would believe. It might be said that the case on which I base this statement was an unusually clear one, but I may say in answer, that in order not to be deceived by such an accident, I have applied to other specimens the various tests which I have referred to with exactly the same result as in the present case. I have even been fortunate enough to obtain through the kindness of Dr. Taylor some of the pus got from the Brompton case, on which he and Dr. Crookshank gave such an interesting demonstration, and I have found that in that case the actinomyces and the details of structure I have referred to

Digitized by Google

could be demonstrated by simple methods with greater ease still than in my own specimens.

3. When brilliantly and deeply stained specimens are required for the purpose of demonstration, almost any of the bacteriological methods known can be used, but Gram's method is undoubtedly the best for bringing out the mycelium, if nothing more than the demonstration of its existence be required. Simple watery solutions of the usual anilin dyes answer quite well, the addition of anilin or carbolic acid being unnecessary. The chief cause of the difficulty one experiences in staining the ray fungus in sections so as to exhibit fully its structure, comes from the fact that it stains very much like surrounding tissues, so that when these are decolourised by the usual methods the fungus is decolourised at the same time; however, by taking care of not pushing the decolourisation too far, it is easy to keep the filaments stained with fuchsin, gentian violet, methyl-violet, methylene blue, &c. (Plate XXVIII, fig. 2.)

The filaments can be stained with methylene blue after the preparation has been stained with fuchsin and decolourised by sulphuric acid, as in staining for *Bacillus tuberculosis*; in such a case, if clubs happen to be present, they may retain a dark red colour; if instead of sulphuric acid acetic acid be used the clubs are more easily demonstrated. Clubs stain well with eosin, aurantia, acid magenta, rubin S., picric acid, &c. They can also be stained very rapidly with sloelin. All this indicates that their sheath is composed of differentiated matter (when the central filaments is present it stains, like the rest of the mycelium, with ordinary basic anilin dyes). The sheath of the filaments also takes these stains, but owing to its thinness this reaction is generally difficult to see. (This contrast between the affinities of the sheath and of the protoplasmic contents is well seen in some bacteria. In 1883 I had already attracted attention to the fact that the differential staining properties of the *Bacillus tuberculosis* were due to the presence of a sheath, and that within that sheath it was often possible to stain the active protoplasma or spores with methylene blue. In 1881, in an unpublished investigation on lochial discharges, which I was carrying out jointly with the late Dr. Angus Macdonald and Dr. P. Wells in the Edinburgh Maternity, I had also noticed that around streptococci filaments there was commonly a thin sheath which stained quite differently from the cocci.)

Digitized by Google

I have lately studied the reaction of the various parts of the hyphæ of moulds with analogous results, and in some moulds the hyphæ terminate in club-shaped extremities with a central core of protoplasma, and present very much the same appearances as the clubs of actinomyces, either before or after staining. My friend Dr. Slater has made numerous observations confirming entirely this statement.

4. The method which I feel inclined to recommend for the purpose of preparing permanent specimens showing the relations of filaments and clubs is the following one, which is a modification of Gram's method. (The ordinary Gram's method did not yield in my hands very satisfactory results when large sections of brain and also of liver had to be stained; that is the only reason why I felt obliged to alter it.)

(1) Specimens are either hardened in spirit or in Müller's fluid; they stain equally well whether the one or the other method is used.

(2) Sections of almost any size can be left in a weak, watery solution (without anilin) of gentian violet or methyl-violet (preferably the extra-dahlia variety) for from one to forty-eight hours or even longer; or else they may be spread on a slide and saturated alcoholic solution of methyl-violet poured on them. (This answers best for the brain.)

(3) After staying a few minutes in the alcoholic solution, or several hours in the watery, the preparations are rapidly passed through distilled water.

(4) They are then left for half a minute or a minute in Gram's iodine solution. (This step is not absolutely necessary if the following ones are carried out sufficiently rapidly, but the mycelium comes generally out very much better when iodine has been used than when it has not.)

(5) The preparations are then partly decolourised on the slide in a semi-saturated solution of eosin, fuchsin S., rubin S. or aurantia (eosin is the best) in absolute alcohol. This should be done rapidly; half a minute is enough generally, and the dehydration is rapidly completed by adding absolute alcohol.

(6) The decolourisation of the specimen is completed on the slide by means of oil of cloves, a thing which takes a very short time when the specimens have been rapidly stained with methyl-violet.

(7) Immediately the specimen has acquired the proper colour

Digitized by Google

the action of oil of cloves is stopped by removing it as far as possible by means of filter paper, and by flooding the preparation with xylol. (This method gives the best results when properly carried out, but when the oil of cloves is deeply coloured by the violet, the xylol is liable to cause a precipitation of the pigment in the specimen, so that it is well to use oil of cloves pretty freely.)[1]

(8) The specimen is then mounted in xylol Canada balsam. Very good results can be obtained by this method in an exceedingly short time. Some section of brain stained thus in five minutes showed the mycelium much better than preparations over which a great amount of time had been wasted. (I think one is often misled by the idea that slow staining gives generally better results than quick staining, but, when owing to slow staining the tissues surrounding bacteria become very deeply stained, it is often impossible to decolourise them without decolourising the bacteria at the same time. Slow staining, however, gives generally more permanent results.) (Plate XXVIII, figs. 1 and 3.)

5. One can obtain good preparations of the clubs by staining the specimens with eosin, fuchsin S. or sloelin, and decolourising them afterwards with a weak alcoholic solution of potash. In this way elegant preparations can be obtained in a few minutes, and although perhaps not quite so gorgeous in appearance as those prepared by Plaut's method they show very often a great deal more.

6. To demonstrate the meaning of the constrictions often observed in the clubs, and to which the idea that they might be gonidiophores was in part due, two methods can be used:

(1) The specimens can be macerated in potash or hydrochloric acid and a cover glass pressed upon them gradually, when, by watching a few clubs, it will be possible to see them becoming irregularly constricted or even taking a regular moniliform appearance; the same effect can be obtained by simple teasing.

(2) A thin section of an actinomyces is placed on a slide, and after staining or not it is allowed to dry; if then it is mounted most of the clubs will be found to be subdivided into small segments, and in the young clubs a central filament can be seen to unite these various transverse segments. (Plate XXVIII, fig. 2.)

[1] I have used this method of washing the oil of cloves out of clarified specimens, by means of benzol, chloroform, turpentine and xylol, for several years now, and have generally found it useful when properly carried out. For bacterial preparations I, of course, use only turpentine or xylol.

Digitized by Google

c. *Pathogenetic remarks.*

The general description of the case having been given chiefly with the view of demonstrating the changes observed in various organs, there remains only to connect the facts recorded by a few remarks.

1. It seems evident that in this case the point of entrance of the parasite was the skin, and not any part of the alimentary mucous membrane, as is generally found in similar cases.

2. The skin of the arms and then of the abdomen was first affected, and, from the chronic nature of the abscesses there formed, and their mode of extension, it seems evident that these abscesses were the result of an inoculation, and not simply the lesions through which parasites accidentally entered into the system.

3. For several months it is evident that the germs must have been carried from one place to another by means of the cutaneous lymphatics. There is, however, a strange feature of the case which is difficult to explain on that hypothesis, namely, the diffusion of the organism over a large area, and the existence of large tracts of skin entirely unaffected between regions where abscesses were numerous.

4. One of the last of these groups of abscesses occurred in the region of the umbilicus, and had apparently cicatrized two or three months before the death of the patient. There the superficial spread of the disease seemed to have ended, and internal troubles must have begun soon after.

5. Judging by the history, the appearance, and the size of the abscess of the liver, it must have been at least two months old when the patient died. Its situation at the point of attachment of the falciform ligament and in the neighbourhood of the ligamentum teres, as well as its independence from the distributions of ordinary vessels, may be taken as almost indisputable proofs of the transmission of the germs through the small veins or lymphatics which accompany the ligamentum teres, as it passes from the umbilicus to the liver.

6. At this stage the mode of invasion must have altered. Five or six weeks before death some of the germs must have passed into the blood and been distributed all through the body.

7. Their passage through the lungs seems to have started inflammatory processes of an ill-defined nature.

Digitized by Google

8. A few of the germs arrested in the kidney and causing obstruction of very small vessels may have given rise to the peculiar growths described in that organ, and resembling so much in their structure the tissues found about the abscess in the liver.

9. But, through some reason or other, a larger number of these particles must have reached the brain and rapidly started mischief in that organ. Allowing a few days for the congestive, necrotic, and inflammatory lesions to take place and to give rise to nervous symptoms, it is evident that the infection of the brain must have taken place very nearly at the same time as that of the lungs. We can therefore consider the large abscesses found in the brain as having grown in the space of about six weeks at most. It was only four weeks before death that the paralytic symptoms were noticed, and these were slight at first, so that the abscess causing them must have been very small at first. Six days before the death of the patient there was no complete paralysis and no indication of degenerative changes in the cord. An absence of degeneration which was confirmed *post mortem*, and proves that the lesions of the motor areas could not have existed long. The main abscess must have therefore grown very rapidly to reach the large size which it had acquired at the time of death.

10. A short time before death another shower of spores must have been disseminated all through the frontal lobes by the anterior cerebral artery.

11. The situation of all these abscesses at some distance under the cortex indicates that the parasite must have been able to pass readily through small vessels, and became really arrested in the smallest arterioles or even in the capillaries supplying the grey matter and the subjacent white matter.

D. *Physiological remarks (neurological).*

1. In order to understand fully the relations of the lesions found after death with the symptoms observed during life it is important to keep in mind—

(1) That out of all the abscesses described above only one group was situated in the motor areas, and that therefore all the others, although probably causing certain disturbances of function, probably did not give rise to any of the phenomena recorded in this case, with the exception perhaps of the final delirium.

(2) That a small portion only of the cortex was entirely destroyed,

Digitized by Google

in a region corresponding to the boundary layers between several motor centres (forearm, wrist, and hip).

(3) That a greater portion of the cortex was undermined by the abscess, and that probably its direct connections with the motor tracts were severed. The portions thus partly isolated corresponded to parts of the centres for various movements of shoulder, arm, wrist, fingers, and legs.

(4) That around the region thus undermined there was a peripheral zone where the cortical layers and subjacent white matter were congested and irritated, and this zone implicated chiefly the centres for muscles of the head and face, shoulder, arm, wrist and fingers; hip, leg and foot; and trunk.

The centres above referred to are, of course, Ferrier's centres or areas, advantage being also taken of the confirmatory and additional experiments and observations of Horsley, Schäfer, Beevor, and others.

2. From what has just been said we should therefore surmise that during life there had been—

(1) Paralysis or paresis of the leg and arm.

(2) Convulsions (Jacksonian epilepsy) of the shoulder, arm, wrist, and fingers, of the leg, and perhaps also of some of the head-muscles and trunk-muscles.

3. Moreover, from the situation of the most superficial and older parts of the lesion, we should expect that the muscles most affected by convulsions would be the shoulder-muscles (deltoideus among others), the elbow- and wrist-muscles (biceps, supinator longus, and flexors of fingers, and also, and perhaps to a greater extent, the pronator and extensor muscles), the hip- and knee-muscles (chiefly the flexors), and the trunk-muscles. Other muscles might also have been affected to a lesser degree, viz. muscles of the neck, of the eyes, and the muscles of the foot.

4. As the gyrus fornicatus seems to have entirely escaped there should have been, if Ferrier, Horsley, and Schäfer be right, no loss of tactile sensibility. If, on the contrary, Schiff and Munk be right, there should have been distinct loss of sensibility.

By looking more minutely into the lesions, further points might be made out, but the difficulty of finding the areas which in the human brain correspond perfectly to those discovered in the monkey would render a more minute study probably fruitless, for the present at least.

Digitized by Google

5. If we now pass to the phenomena observed by Dr. Gamgee during life, and confirmed by Dr. Ferrier, who, at the invitation of Dr. Gamgee examined also the case a few days before death, we will find the following among the most prominent:

Four weeks before death patient noticed loss of power in right leg and arm.

Seven days before death (1) paralysis (or paresis) of right arm and leg. (2) No anæsthesia or hyperæsthesia of parts affected. (3) No reaction of degeneration. (4) Attack of Jacksonian epilepsy lasting five minutes; right side affected; right leg less affected than right arm, convulsions beginning in deltoideus and extending downwards; wrist bent up. (5) No knee-jerk; no ankle-clonus.

Six days before death another attack of convulsions, lasting three minutes.

Five days before death was the day on which Dr. Ferrier saw the patient. Copy of Dr. Ferrier's notes: (1) "Jacksonian epilepsy. (2) Arm and leg absolutely paralysed. (3) No affection of face. (4) Perfect retention of sensibility, tactile and muscular, feels and localises the slightest touch, and indicates with perfect precision the movements of any joint = cortical paralysis without loss of sensibility."

Three days before death an attack of convulsions.

The day before death right pupil dilated.

Last day delirium.

Thus Dr. Gamgee's case affords a complete confirmation of Dr. Ferrier's statements regarding the function of the portions of the cortex affected in this case.

This case also confirms entirely the later observations of Professors Schäfer and Horsley on the trunk-centres, and gives a full confirmation of the views advanced by Ferrier and supported by Horsley and Schäfer regarding the localisation of tactile sensibility, whilst, of course, it infirms to the same extent Schiff and Munk's views.

6. There are some points of great interest in the phenomena recorded, when they are considered in the light of the lesions observed after death.

(1) A very small part of the arm and of the leg areas was entirely destroyed, and even if the whole of the parts undermined by the abscesses be taken into account, not more than one half of

Digitized by Google

the arm area and one sixth of the leg area were destroyed or disconnected, and yet the paralysis of arm and leg was nearly complete. It is interesting, however, to note that the paralysis of the arm was more complete than that of the leg, although, for obvious reasons, the patient noticed loss of power in the leg before he was aware of loss of power in the arm.

(2) The most superficial cortical lesion was near the shoulder centre; in that region the membranes were slightly thickened and adherent. The other portions of the brain, which surrounded the superficial portion of the abscess, were undermined by the deeper parts of the same abscess, so that any irritation starting from the points of adhesion could have produced motion only by extension to parts of the cortex, situated near the margin of the deeper lesion. It is perhaps one of the most interesting features of this case that Dr. Gamgee was able to witness one of the attacks of convulsions, during which he noticed that the shoulder-muscles were first affected, then those of the arm and forearm, finally the wrist was flexed. The leg was convulsed less than the arm. The trunk was also affected, but to what an extent is not recorded. If we suppose a wave of irritation starting from the place where the membranes were adherent, that wave would have affected (1) the shoulder and arm areas. (2) The elbow and forearm areas. (3) The wrist and fingers areas. (4) The trunk and leg would also have been affected early, but to a much lesser extent than the arm. (5) Some of the head-muscles should also have contracted; according to Horsley and Schäfer's experiments the ears should have been strongly retracted; this was not observed, but retraction of the ear is a movement seldom observed in man, chiefly owing to the small size of the ear-muscles. The absence of rotation of the head and of deviation of the eyes is of great interest in showing that these areas do not correspond to the posterior part of the middle frontal convolution, which was the portion of the head area nearest to the abscess.

(3) The dilatation of the right pupil is of interest in showing a unilateral dilatation of the pupil when, probably, only the posterior portion of the head area was stimulated. This would, of course, complete the remark which we have already made regarding the probable absence of any area corresponding to the muscles of the head and neck in the same posterior part of the head area.

7. The marked œdema which I noticed *post mortem* (I was careful to eliminate the possibility of *post-mortem* gravitation of fluids) in

Digitized by Google

he right arm and leg, and more especially in the foot and hand, suggest the existence of vaso-motor disturbances previous to death, due to the irritation of the hand and foot cortical areas. Whatever be the cause, this is certainly an interesting instance of well-localised nervous œdema (Laycock).

General conclusions.

The following points seem to have been gained by the study of this case:

(1) Actinomycosis may begin in the skin, extend through the lymphatics, and penetrate into some internal organ.

(2) The parasite may after a time be disseminated through the system by means of the blood-vessels.

(3) It may pass through organs without apparently producing typical lesions, but nevertheless it may cause serious inflammation, which has apparently nothing specific.

(4) It is disseminated under the shape of small spores, and afterwards grows into branched filaments which, when unstained, have the appearance of a mould mycelium (when stained by Gram's method they look like Steptothrix or Cladothrix filaments).

(5) After five or six weeks, clubs begin to appear, and are the result of the thickening of the sheath of some of the filaments; after a time the protoplasmic core breaks up into small rounded masses which may be spores, and finally the sheath of the clubs remains empty.

(6) The fungus has all the characters of a mould fungus (although septa have not been seen in the filaments). The clubs have strong analogies with *Asci*, and the fungus belongs probably to the *Ascomycetes* and possibly to the family of the *Pyrenomycetes*.

(7) Considerable irritation of the tissues, and vascular disturbances, often rapidly followed by necrosis, result from the infection of a part, and this is manifest several days before the organism can be demonstrated. This seems to indicate the elaboration of some virulent poison in the early stages of growth.

(8) In the brain a large abscess can be formed in a few weeks under the influence of this parasite. Owing to the small size of the spores, or the way in which they are carried by leucocytes, areas supplied by several small vessels may be affected at the same time, so that the lesions must generally be multiple.

Digitized by Google

(9) In this case the symptoms observed during life corresponded to those which Ferrier has described as resulting from affections of the parts of the brain implicated in this case. The absence of tactile anæsthesia supports also the views of this observer on the localisation of tactile sensibility, and disproves the views that the motor areas are also tactile areas as supported by Schiff and Munk.

Note.—I have not attempted to give the literature of the subject because I am aware that several papers of great importance have been written in London, or are being written on the subject of actinomycosis. I present the case as one of great interest *per se*, and one which has been studied independently of any preconceived idea.

The chief facts of the case were communicated to Dr. Acland and several friends during the months of February and March, but many facts concerning the morphology of the actinomyces I had ascertained previously. From what I heard at the Royal Medical and Chirurgical Society I feel inclined to differ from Dr. Crookshank regarding the morphology of the actinomyces; however, as I have not yet seen his full report, I simply give my facts and they will speak for themselves.

On the day on which this paper was communicated Mr. Eve showed a specimen of *Actinomyces hominis* in which clubs were easily demonstrated, as well as the mycelium, supporting thus one of my contentions regarding the ease with which clubs can be demonstrated. About three weeks later Dr. McFadyean communicated observations on a case of *Actinomycosis bovis*, in which nearly all the points which I had advanced concerning the human parasite are recorded as being present in the bovine disease. It must be said that most of these points have been familiar to German observers for more than six or seven years. I need only refer here by name to the work of Israel, Bollinger, Johne, Ponfick, Pflug, Hink, Harz, De Bary, Acland, Eve, Shattock, Taylor, and Crookshank. The most complete history of the subject will, I am informed, be found in Crookshank's reports in the 'Annual Report of the Agricultural Department of the Privy Council Office on the Contagious Diseases, &c., for the year 1888,' which will soon appear, and a most condensed and lucid account of the subject by Dr. Acland will be found in the new edition of 'Quain's Dictionary.' I need only add that Bollinger has recorded lately a case of primary actinomycosis of the brain which differs considerably from the present one.

May 21*st*, 1889.

Digitized by Google

16. *Psorospermial cysts of both ureters.*

By Frederic S. Eve.

[With Plate XII.]

The following case occurred in the practice of Mr. J. Arnall Jones, of Aberavon, who sent the specimens to Mr. E. Hurry Fenwick, by whom they were kindly forwarded to me for examination. The following are Mr. Jones's notes of the case:

"Mrs. Jane G—, Aberavon, aged 51 years; robust, energetic woman. Family history good, with no hereditary disease. On the 13th of March, 1887, she expressed herself to her husband as 'feeling unwell' and out of sorts, and she remained in that condition, but continued performing the whole household duties till the 17th, when she was obliged to give up work, and complained of severe hypogastric pain, which towards evening became extremely acute. On the morning of the 18th frequency of micturition with hæmaturia appeared.

"The urine was examined, was found to be acid, and contained blood intimately admixed with it, but no casts or other deposits could be discovered under the microscope. Micturition was intolerably painful and frequent, the patient having to void urine every quarter of an hour, and she expressed the pain as being much more severe than that attending parturition. On the 19th several clots were passed, the pain and frequency of micturition increased, and the urine became fœtid and alkaline. The bladder was sounded and examined *per vaginam* with negative results; neither stone nor adventitious growth could be detected. March 21st. The patient is very anæmic from the continuous hæmaturia, and naturally greatly exhausted from loss of sleep, for the same frequency of micturition has persisted night and day. On the 27th the temperature rose to 101° Fah., while the urine was voided half hourly, and the pain had much abated. The rise of temperature was maintained and the other symptoms remained as last noted, while the exhaustion increased and the anæmia became more profound until the time of her death, which occurred on the 30th of March. The patient remained sensible to the last.

"*Treatment.*—In the absence of any symptoms pointing definitely to the locality of the disease, the treatment employed was purely

Digitized by Google

palliative; perfect rest was maintained, Ergot, gallic acid, and digitalis were employed to try and arrest the hæmorrhage. Morphia and opium were administered to allay pain, and antiseptic injections to correct the fœtor. The food was bland, and consisted of milk, beef-tea, and puddings, with linseed-tea and barley-water for drinking, and whisky given as a stimulant when faintness came on."

I have described the specimens as follows in the catalogue of the Royal College of Surgeons' Museum, Nos. 3644 C and D.

"Section of a kidney with the ureter, which is the seat of psorospermial cysts. Its inner surface is thickly studded with closely grouped rounded cysts the size of millet-seeds, and of a yellowish colour. They project prominently from the mucous membrane and cease at a point an inch and a half below the pelvis. With the exception of changes the result of decomposition, the kidney appears healthy."

A portion of the opposite kidney, from the same case. There are two ureters, both of which are affected in the same manner as that in the preceding specimen; but in these some of the cysts appear to have ruptured, and have left minute rounded apertures in the mucous membrane. The mucous membrane of the bladder was healthy.

Microscopic sections made at right angles to the surface of the ureter, after embedding in celloidin, showed the following appearances: There were several cysts about the size of millet-seeds, which contained a colloid material. In this lay many ovoid bodies corresponding in size and appearance to pseudo-navicellæ. Some of them were rounded at one end and pointed at the other. A few only were perfect, the majority apparently breaking up (see Plate XII, fig. 2).

The kidneys had evidently undergone *post-mortem* decomposition, and little was learnt by examination of microscopic sections; but no psorospermial cysts could be found. The source of the hæmaturia must therefore remain doubtful. It seems unlikely, from the condition of these parts, that such profuse hæmorrhage took place, from either the ureters or bladder; and thus negative evidence points to the kidneys. The condition of the other viscera is not noted in the report.

It is a familiar fact that psorospermial cysts (gregarinidæ) are exceedingly common in the liver of rabbits, and not uncommon in pigs and other domestic animals. The great rarity of this disease

Digitized by Google

in man is therefore surprising. In Dr. Cobbold's well-known work on 'Parasitic Diseases,' allusion is made to cases in which psorospermial cysts were found beneath the capsule of the kidney. And a case is recorded in the 'Transactions' of this Society, vol. xxxiv, p. 239, by Dr. Hadden, in which small cysts with calcareous walls were scattered beneath the capsule of the kidney. The organs were submitted for examination to Dr. Cobbold, who stated that he thought they were psorospermial. *May 21st*, 1889.

---

17. *Further specimens illustrating the Neoplastic Process in trees.*

By W. Roger Williams.

[With Plate XXX.]

On a former occasion[1] I exhibited specimens illustrating neoplastic processes in trees. I now have some additional ones to show.

Tumours in trees may be divided into three chief groups.

The *first* group comprises those circumscribed woody nodules so commonly found beneath the bark of the beech, oak, holly, cedar, and other trees, to which the term of "knaurs" may be applied.

Here is an example, on a small scale, from an elm tree.

It presents as an ovoid swelling, about the size of a Tangerine orange, which projects beneath the bark of one of the branches. Its surface is devoid of buds and shoots. On section it is seen to be composed of dense wood covered with rather thickened bark. In the section two centres of development can easily be made out, each surrounded by its own system of concentric woody laminæ. These concentric systems are embedded in other woody laminæ, derived from the investing cambium layer, and consequently disposed parallel with the bark.

A narrow ligneous pedicle connected the tumour with the wood of the branch whence it grew. Such a connection is unusual with growths of this size.

[1] 'Trans. Path. Soc.,' vol. xxxviii, p. 460 *et seq.*

Digitized by Google

At the free extremity of the tumour it is interesting to observe a separate woody nodule the size of a small pea, completely isolated in the bark. It may be taken as illustrating an early stage in the development of such growths, whose origin may be ascribed to the disorderly evolution of adventitious buds. It accords with this view, that these tumours first appear as very small globular bodies in the cellular tissue of the cambium layer whence they originate.

Such growths are highly organised and possessed of distinct individuality; they may be compared with the fibromas, lipomas, and other similar tumours of animal pathology.

The *second* group comprises the continuous tumours or exostoses. I have here a specimen of this kind from a Scotch fir tree.

The disease presents as a woody outgrowth from one of the smaller branches, which it completely surrounds for nearly three inches. The overlying bark is irregularly thickened and fissured, but no buds or shoots arise from it.

On section the morbid growth is seen to be composed of very dense, irregularly formed wood, which is separated from that of the branch by a thin but well-marked line, representing the cambium layer. Hence it may be inferred that this growth originated from that part of the cambium devoted to the development of the cortical structures.

Such tumours may be fairly compared with the exostoses and allied continuous tumours of animal pathology, and, like them, they are highly organised.

In the *third* group I include all those new formations called by the French *broussins*, whose distinguishing peculiarity is the very free and continuous development of buds, shoots, and stunted branches. Of these I have to show two very fine specimens.

The first is from near the terminal extremity of a branch of a large elm tree. It consists of a dense mass of abnormally developed buds, shoots, and stunted branches. The latter are much more numerous and better developed than in the specimen next to be shown, which indicates that a comparatively higher grade of organisation has here been attained. On looking at these stunted branches, with the fluted thickenings of their bark, no one would recognise them as elm twigs, so widely have they departed from the normal type. There is here evidence of bud variation as well as abnormal gemmation.

The last specimen I have to show is the most interesting of

Digitized by Google

all, because it represents malignant disease in its simplest form (see Plate XXX).

It is from one of the chief branches of a hornbeam tree, otherwise healthy looking.

The growth is composed of innumerable densely massed buds, a few of which have developed into shoots and twigs. Almost the whole circumference of the branch, for a distance of fifteen inches, is surrounded by this growth. On section the subjacent woody tissue of the branch corresponding to the seat of the disease is seen to be double its normal thickness. The wood is very dense and of irregular formation, except in the central part, and between the two there is no line of separation. Interspersed in this dense wood are detached fragments of bark; and in several places long processes of bark penetrate deeply into the wood. This great thickening and irregular formation of the wood are due to the exuberant and irregular flow of sap caused by the abnormal gemmation, which is the essential element of the disease.

Such growths depend upon the continuous development of immense numbers of adventitious buds in the cambium layer, which either remain dormant or forthwith develop into shoots or stunted branches. This indefinite production of large quantities of lowly organised cellular tissue, which subsequently undergoes imperfect evolution, constitutes the nearest approach in vegetable pathology to the sarcomas and carcinomas of animal pathology. For, as I have elsewhere pointed out,[1] the essential feature of malignancy is *not* infectiveness, but the indefinitely sustained activity of certain lowly organised cells which grow and multiply independently, without ever reaching the highest grade of organisation.

We may, then, ascribe the absence of infectiveness in these tumours to the want of a specialised lymph-vascular system, easy of access to the proliferous cells, and capable of transporting them to distant parts, and not to any essential difference in the nature of the morbid process.

With regard to the causation of such growths I have been unable to find any evidence of their being due to parasites. In the present imperfect state of our knowledge we must be content to regard them as so-called spontaneous variations.

January 29th, 1889.

[1] The 'Principles of Cancer and Tumour Formation.' J. Bale and Sons, London, p. 140.

Digitized by Google

XII. DISEASES, ETC., OF THE LOWER ANIMALS.

1. *A disease of the bones of goats, having points of resemblance to mollities ossium, osteitis deformans, and multiple sarcoma of bone.*[1]

By W. G. Spencer, M.B.

[With Plate XXXI.]

I draw the attention of the Pathological Society to this disease, not only for the interest attaching to the disease itself, but also because that it appears to be a condition, intermediate between some of the diseases of bones, met with in man.

Dr. George Harley, in the eleventh volume of the Society's 'Transactions,' has described the same disease in the horse, with figures, the specimens having been sent by Mr. Varnell for his report. Mr. Varnell's paper, with Dr. Harley's report, forms the classical account in veterinary works. Goats have been brought to the Brown Institution for some time affected in this way, and I have to thank Mr. Thomas Busbie for collecting specimens for me, he being able to recognise the disease at an early stage. The owner first notices that the animal is getting thinner, and then that there is some difficulty with food. When brought in an early stage there is a symmetrical swelling of the lower jaw, between the angle and the molar teeth, the jaw feeling softer, and being capable of indentation; with this there is some swelling about the ends of the long bones and the joints. At a more advanced stage the angle of the lower jaw, and the horizontal ramus on either side, forms a symmetrical swelling several times the ordinary thickness of the ramus, and as the vertical ramus becomes involved the jaw cannot be closed, for the swelling comes in contact with the zygoma. In the most advanced stage the mouth is partly open, and the exactly symmetrical swelling takes the places of the horizontal and vertical ramus on each side, and tapering towards the incisor teeth. The animal is unable to eat anything but pultaceous food; finally it

[1] From the Laboratory of the Brown Institution.

Digitized by Google

ceases to ruminate, and then soon dies. I think that it is the arrest of rumination, in consequence of the immobility of the jaw, which determines the death of the animal from starvation. A goat, four months old (female), is shown alive with a swelling of each lower and upper jaw, and three others are attending at the Brown Institution as out-patients. In none of them are there perceptible changes in the other bones, except the jaws, nor in the joints.

On examination, after death, the pathological conditions form three groups:—(1) The lower jaw, and with this the upper jaws, and the flat bones; (2) the ends of the long bones; (3) the joints. Beyond these the rest of the structures appear healthy.

(1) Specimens from nine goats show lower jaws in different stages of the disease. The earliest one, from a goat of about two months, shows a swelling of the bone extending from the front of the angle to the anterior end of the molar teeth, the enlargement is symmetrical, and is about double the normal thickness behind the molar teeth. One half has been kept in alcohol, the periosteum being somewhat œdematous in the recent condition, the other half was decalcified in order to cut the teeth through with the microtome. A vertical section through the horizontal ramus shows that where the bone is most enlarged its cavity is filled by a firm pinkish-white substance, which has encroached upon and thinned the bony walls, surrounds the unaltered teeth in their alveoli, and also the inferior dental nerve and artery as it runs in the bone. Towards the front of the molar teeth the disease is less advanced, the whitish substance surrounds the root of the tooth only, the dental alveolus being replaced by it. Another lower jaw from a goat about two months, in the same stage of the disease has been macerated, and shows enlargement from the angle to the molar teeth. Two other specimens are in a more advanced condition; one from a goat about five months, and the other from an adult. The jaws are nearly three times the normal thickness, the enlargement extends as far as the incisor teeth, and to the lower part of the vertical ramus. The jaws are soft enough to cut across easily with a knife, the periosteum was œdematous when fresh, and it was difficult to clean off the tendinous insertion of the muscles without tearing off some spiculæ of bone. The bones have been expanded until only a thin shell has been left of soft spongy bone in the outer part of the firm pinkish-white tumour-like substance, which has replaced the bone.

Digitized by Google

Digitized by Google

EXPLANATION OF PLATE XXXI.

To illustrate Mr. Spencer's paper on Disease of the Bones in Goats. (Page 449.)

FIG. 1.—Half of the lower jaw of an adult goat, macerated. The bone has become expanded to a thickness of 1½ inches at the angle. The outer and inner surfaces are very thin and porous, and the removal of a portion of the latter shows the cavity filled by sponge-like spiculæ of bone.

FIG. 2.—Half of the lower jaw of an adult goat, which has enlarged to be two inches thick at the angle. Each side of the lower jaw formed a tumour weighing 5 oz.

Digitized by Google

Digitized by Google

Digitized by Google

The most advanced disease is represented by two specimens, both from adult goats; one specimen has been macerated. The bone has been expanded from the molar teeth backwards, and includes the vertical ramus up to the base of the coronoid and condyloid processes. In the dried state it measures one and a half inches at its widest part, and the bone is most like a sponge of the finest kind, the interior containing soft spiculæ from which the growth has been macerated. The other specimen has been preserved in spirit, each jaw forms a tumour, roughly, "leg of mutton shaped," about two inches in thickness, and both together weighing three-fifths of a pound. The teeth are perfectly natural, buried in the growth, and they may fall out on maceration. The tumour cut across is solid throughout, of a pinkish-white colour, and spiculæ of bone can be felt to grate under the point of a knife.

The upper jaws exhibit the same changes as the lower, but to a less extent, the cancellous tissue of the flat bones is altered, and this is most marked in the frontal bone, but also in the other short bones. The skull of a goat two months old has been preserved in alcohol, and a notch made into the upper jaw shows the pinkish-white growth surrounding the tooth and taking the place of the bony alveolus, and the frontal bone when fresh was softer and more vascular than normal. A skull which has been macerated shows that the superior maxillary bones have become thinned and expanded. In the more advanced condition the skull of a goat of about five months shows an enlargement and softening of the upper jaw, the frontal bone and the parietal bones are very soft and easily to be cut; they appeared vascular when fresh. A skull of an adult goat was macerated with the greatest difficulty, for the bones were so soft and the tendinous attachments so tough that the whole nearly fell to pieces. It shows the expanded and spongy condition of the upper jaws, the worm-eaten character of the frontal, parietal, and the rest of the skull bones, and the whole skull is exceedingly light. The skull most advanced shows that the bones of the upper jaw have been replaced by a pinkish-white new growth containing bony spiculæ, as in the lower jaw. The frontal bone could be cut with the microtome in some parts without decalcification—it and the other bones of the skull not being so vascular as in the early stage, but infiltrated more with the growth.

A head of an adult goat, two years of age, has been cut off through the neck, having been killed about eight hours previously. It was

Digitized by Google

intended to be shown alive, but the breathing had become bad and it could take nothing but milk poured down its throat. The specimen shows the marked swelling of the lower jaw so that the mouth cannot be closed, the enlargement of the upper jaw giving it a peculiar rounded facial expression, and the hard palate is depressed. By passing the finger from behind up the nasopharynx and also into the mouth it can be seen how the swelling tends to obstruct breathing and swallowing.

(2) *The ends of the long bones.*—At a stage in the disease when the jaws have become enlarged changes are found at the ends of the long bones; on the surface the bone is softer than normal and the ligaments easily tear away with some spicules of bone attached to them. Whilst the ends of the long bones can be cut by a knife, the shafts retain hardness. In a specimen preserved in alcohol the bone at the extremity of the diaphysis, especially the upper end of the tibia, is replaced by the same kind of tissue as in the jaws. The cancellous bone of the diaphysis is replaced at the centre by the new growth, and the compact outer layers change into soft cancellous bone. In an early specimen from a goat of two months a vertical section through the end of a bone shows that the epiphysial line is normal, below this the cancellous bone of the diaphysis is being replaced by the new growth, and the compact bone beneath the periosteum is being transformed into cancellous bone of a soft character, the spaces of which contain the same tissue as in the jaw. The same is seen in a transverse section of the bone, some short distance below the epiphysial line. The humeri, femora, tibiæ, and radio-ulnæ from an adult goat have been macerated, and the ends of the diaphysis, especially the upper end of the tibia, shows on the surface a worm-eaten character as in the frontal bone, and the cancellous bone inside has been changed into the spongy spicules seen in the macerated lower jaws. Although the shafts of the long bones towards the centre remain hard, the medullary cavity has increased, at the expense of the compact walls. The marrow is normal towards the middle of the shafts.

I regret that I have not been able to bring the long bones corresponding to the most advanced stage of the disease, but the owner of the goat from whom I obtained the tumour-like lower jaws and skull would not let me have more. They become enlarged as has been described for the lower jaw, being easily cut with a knife, the bone having been replaced by the pinkish-white growth; when

Digitized by Google

macerated the bone is extremely light and of the texture of fine sponge, or it may fall to pieces during the process.

But, on the other hand, the jaws may reach an advanced state of disease without the other bones being affected very much. This is the case in the living specimen shown, and in the one killed shortly before bringing its head. In this case although the jaws are far advanced, there was found no change in the long bones except a little softening just about the lower end of the diaphysis of the femur.

(3) *The joints.*—Changes are to be found in these at an early stage, not affecting necessarily all the joints. I show specimens preserved in glycerin of the knee, ankle, elbow, and occipito-atlantal joint of a goat aged five months. On cutting into the joint darkly-stained synovial fluid escaped; the synovial membrane was swollen and gelatinous in appearance, with dark hæmorrhages into it; the articular cartilage had a uniformly dark blue or slate-coloured appearance. In certain spots the cartilage had disappeared by erosion, exposing bone. The condition of the joints resembles somewhat the condition of the joints in Dr. Legg's specimens of hæmophilia in St. Bartholomew's Hospital Museum, except that in the goat's the colour is much darker.

This affection of the joints appears to belong to an early stage in the disease, and either it is so slight that the owners do not notice it, or perhaps it may not occur in all cases. In those in which there is swelling of the joints at first the swelling may pass off, leaving only slight appearances behind.

In the animal killed to-day the joints appeared normal, except that in some few places bone was exposed by erosion of the cartilage; but, the goat being an adult, I was not sure that the changes were not rheumatic.

Microscopic appearances.—Section 1 shows round and oval cells taking the place of the alveolar bone around an unaltered tooth.

2. Compact bone of lower jaw replaced by round and oval cells; giant-cells surround the trabeculæ of bone, which are in course of being removed.

3. Groups of giant-cells amongst round and oval cells, all the bone having disappeared except a few spicules; in the depth of the section some myxomatous changes.

4. Compact bone of upper end of diaphysis of tibia replaced by round and oval cells.

Digitized by Google

5. Upper end of diaphysis of tibia beneath the periosteum; the bone has been replaced by round and oval cells, except a few scattered trabeculæ surrounded by giant-cells.

Round and oval cells take the place of the bone. The earliest changes are about the tooth sockets and in the bone beneath the periosteum of the lower jaw. The compact bone changes into cancellous bone, and the cancellous bone into isolated spiculæ surrounded by cells of new formation. The periosteum appears œdematous. Around the trabeculæ of bone are placed multinuclear giant-cells; sometimes these lie in a small excavation in the trabeculæ. When a bone trabecula which has been surrounded by giant-cells has disappeared the multinuclear giant-cells are left in a group amongst the round and oval cells. The cells in the depth of the growth show changes of myxomatous degeneration, but none towards connective-tissue formation, nor are there hæmorrhages. The fibrous layers of the periosteum remain unaltered, covering the growth everywhere.

The disease is apparently very prevalent amongst the goats in Vauxhall and Wandsworth, considering that the number kept is not great, and chiefly during the spring and early summer. Although I began last year to collect specimens, I did not get one from the end of July until the middle of March. Since then I have had two, and I expect that several animals now under observation will afford me some more material. The disease runs a rapid course, and the animals die in from one to two months after the swelling of the jaws has become evident. Naturally the young animals go off earlier, soon after the time that rumination stops. The adult animals live longer, either because they can continue rumination under greater difficulties, or because the nutrition can be maintained without it. The goats are kept by the people chiefly for their milk, which is frequently sold; consequently females largely predominate. All the specimens which I have examined have been females. They are either bred or brought from Wales, Ireland, or the Continent.

On its natural food, viz. coarse upland grass and hay, the goat appears thin with a staring coat. In London they are given hay and corn, or they live on the remains of cooked vegetables, or wander about the streets and pick up garbage. Before being attacked by the disease they have been fat with smooth coats.

I show from the museum of the Royal Veterinary College the

Digitized by Google

skull of a horse affected with the same disease. The whole skull is extraordinarily light, the lower and upper jaws are much enlarged, the bone of a light, fine, spongy character. From Varnell's[1] paper and later description the first signs in the horse are rheumatic symptoms with swelling and heat about the joints; lameness may result from the tearing away from the bone of ligaments or tendinous attachments, but the bones do not fracture. The lower jaws enlarge so that pultaceous food only can be eaten; the upper jaws enlarge and cause a rounded prominence of the face; hence the popular American term "Bighead." The difficulty in feeding increases, until the animal dies. The *post-mortem* appearances are as I have described for the goats, as respects the jaws, the long bones, and the joints. Varnell found the disease only in males, geldings and entire; but it has since been found in mares. The ages have been from two to six years; I find one account in an aged pony, at least twelve years, but apparently not in colts. All breeds in all situations have been attacked; Varnell found it in millers' horses, fed highly with bran and pollard, occurring on one farm near Reading, and not on another, belonging to the same owner, some two miles distant, where the food was exactly the same. But Robinson[2] has noticed it in a horse who came to London for the season, and went from London with it. It has been found in thoroughbreds, in Scotland, in Shetland ponies, in ponies[3] employed in mines, and it has occurred very extensively in the Mississippi Valley, where it was at one time attributed to maize. The last account by James[4] speaks of eighteen to twenty cases occurring in one stable with a floor of earth. He believes it to be diminishing on account of increased cultivation and drainage, although in former times it had caused great losses. Dellagana[5] has found the disease prevalent in Ceylon, and apparently indigenous. It occurs among the native animals; he quotes a case of it in a rough pony belonging to a native grass-cutter. It also occurs in horses recently imported from Australia; these horses are taken up from grass and put straight on board, where they are fed on corn and suffer from the voyage, and arrive in low condi-

[1] Varnell, 'Veterinarian,' 1860, vol. xxxiii, pp. 493, 573, 645.
[2] Williams, 'Veterinary Surgery,' 1886, sixth edition, p. 184.
[3] Wood, 'Veterinary Journal,' 1879, vol. ix, p. 82.
[4] James, 'Journ. Comp. Med. and Surg.,' 1886, vol. vii, p. 193.
[5] Dellagana, 'Veterinary Record,' 1888, No. 4, p. 37, Aug. 4th.

Digitized by Google

tion. Another case is recorded by Asheton Smith of Calcutta;[1] it has also been noticed in Switzerland. From the foregoing description it will be seen that this disease in goats differs from rickets, although many young animals as well as adults are attacked; and I cannot find any changes from the normal in the epiphysial cartilages, neither is it actinomycosis; the growth is solid, no tendency to break down; it is exactly symmetrical in the lower jaws, however far advanced the growth is still covered by the periosteum. No other organs besides the bones are affected.

Is it connected with osteomalacia? In veterinary books the disease in the horse, osteomalacia, and other diseases of bones of various kinds are called "Osteoporosis." Fortunately, I am able to show a specimen of osteomalacia in a goat, which was obtained about a week ago; it was brought with a spontaneous fracture of both femora. As in man, the changes are most marked in the femora, the pelvis, and the humeri. The shaft of the bone has been reduced to a thin shell, and is filled with the peculiar gelatinous material and hæmorrhages; but the shell of bone was hard enough to require a saw to cut it through. The joints were normal, the cartilages white; the skull including the lower jaws were apparently normal. The goat was a female, between nine months and a year old, not pregnant, apparently under the same conditions as before mentioned for the others. Osteomalacia in animals appears to cause first rheumatic symptoms, then spontaneous fracture. The so-called causes are very discordant; in some cases the same conditions have been found as are mentioned for man. But, for instance, a most valuable yearling thoroughbred,[2] kept with all care, died with fracture of both femora and humeri, and two ribs. The medullary canal was enlarged and full of reddish-coloured substance of the consistence of cheese, the compact tissue of the shaft of the bones being barely one eighth of an inch in thickness. Sheep[3] have suffered on poor moorland, and in other cases only when the moorland was recently reclaimed, well cultivated, and limed, and the sheep folded upon it.

But the disease in goats differs importantly from osteomalacia; it is in one sense a rarefactive osteitis, an "Osteoporosis," to adopt the name given by the veterinary surgeons; but it is

[1] Editorial, 'Veterinarian,' 1874, vol. xlvii, p. 438.

[2] Cartwright, 'Veterinary Journal,' 1880, vol. x, p. 231.

[3] Williams, 'Veterinary Surgery,' 1886, sixth edition, p. 184.

Digitized by Google

Digitized by Google

Digitized by Google

EXPLANATION OF PLATE XXXII.

To illustrate Mr. Spencer's paper on Symmetrical Tumours of Bone in Dogs. (Page 457.)

FIG. 1.—The foot with the new growth on its dorsal surface. The notch shows the depth at which hard bone is reached.

FIG. 2.—The radius and ulna, the former being surrounded by a new growth in its distal half.

FIG. 3.—The radius of the opposite side macerated. The formation of new bone in the deeper parts of the growth are shown, also the grooves in the new bone for the tendons.

Digitized by Google

Digitized by Google

something much more, in that the bone is not only removed, but that its place is taken by a new growth, which extends beyond the limits of the bone, stretching the periosteum in front of it, and in which growth there are no signs of connective tissue changes.

In osteitis deformans the bone substance is partly removed, but new bone is again formed. Osteitis deformans is also connected in some way with new growth; in five of the eight cases, which Sir James Paget has followed to the end, death has happened from malignant disease.

To sarcoma of bone, the new growth in this disease of goats has a resemblance because it consists of round and spindled cells, amongst which are myeloid cells. But multiple sarcomas of bone begin as distinct tumours, and rapidly extend to neighbouring soft parts.

Mr. Horsley and I intend to try and find out more by using experimental methods. My communication is merely a preliminary one as regards the full knowledge of the disease. Nevertheless, if it forms in any way a link between the general affections of the bones in man alluded to, it may throw some light on the causation of diseases which are at present involved in obscurity.

April 2nd, 1889.

---

2. *Multiple symmetrical tumours of bone from a dog.*

By W. G. Spencer, M.B.

[With Plate XXXII.]

The specimens consist of the bones of the fore and hind limbs, with the tumours on them, and show the following points, viz.:

(1) Symmetry both on the fore and hind limbs.

(2) That the tumours have advanced from the extremities as far up the fore limbs as the hind limbs.

(3) That the progress has consisted in the growth of separate tumours from the bone, which have fused with one another as they extended beyond the bone into the soft parts.

(4) That the tumours commenced on the dorsum of the fore and hind feet, and extended upwards; tumours in the early stage are

Digitized by Google

seen on the lower part of the femur and humerus, apparently commencing in the bone below the outermost layer, *i. e.* being parosteal rather than periosteal in origin.

The dog was a fine valuable collie, aged 4 years, having been well cared for, with no history of an injury. The disease had been noticed twelve months before as small tumours on the dorsum of the feet, which had grown much during the last six months.

The tumours felt extremely hard; they caused no pain except towards the last, when slight tenderness was manifested on handling. The dog became very fat in confinement. It was killed, and no further pathological lesions were found except a scar in one lung, apparently from a parenchymatous rupture.

On the limbs the skin and subcutaneous tissue, including the under surface of the feet, were normal. On the dorsum of each foot is a mass of the growth; others surround the radio-ulna and the tibio-fibula. The femora and humeri show slight protuberances of the bone, but there were no changes in the soft parts covering them. The tumours are not circumscribed; they have involved the muscles, and the tendons run through and into them. Fibrous extension of the growths surround the tendons beyond the limits of the tumours. The tumours are fibrous on section, and a little below the surface the knife arrives at extremely dense, hard bone.

WOODCUT 9.

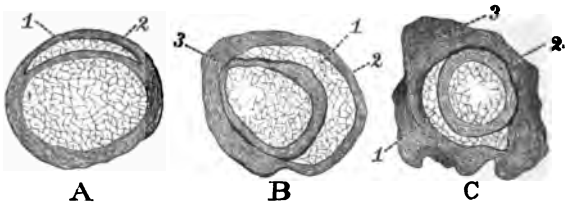

A. Section through the lower third of the femur, showing the commencement of a tumour in the bone.

B. Section through the lower third of the humerus, showing the same,

C. Section through the middle of the tibia, showing it surrounded by extremely dense new bone.

1. Normal compact bone. 2. New cancellous bone. 3. New compact bone.

Microscopically the structure is that of a fibroma with myxomatous changes.

Photograph I. A hind foot; the fore feet are similar; the

Digitized by Google

plantar surface is normal; a notch has been cut down to the bone.

II. A forearm; the lower part overhung the wrist, but it was distinct from the foot.

III. The radio-ulna of the opposite forearm macerated, showing extremely hard bone forming the base of the tumour, with grooves for the tendons, and osteophytic processes of bone branching out into the soft parts of the tumour. The tibio-fibula, when macerated, had a similar appearance. *May* 21*st*, 1889.

Report of the Morbid Growths Committee on Mr. Spencer's specimen of disease in a dog.—We have examined both the macroscopic and the microscopic specimens of Mr. Spencer's, as well as others made by ourselves, and including the osseous outgrowths with the superjacent swelling; and we agree with him in thinking that the morbid process commences in the bone, and subsequently involves the surrounding tissues.

The symmetry of the lesions and their generalisation in the long bones are highly interesting facts. We think with Mr. Spencer that the question of rickets may be altogether excluded.

We would also exclude the condition known as myositis ossificans. The osseous outgrowths show no indication of selecting the muscles attached to the bones.

The lesions are so unlike any known to be due to tubercle that there can be no hesitation in eliminating that disease; the internal organs, moreover, were healthy. Nor would we ally the outgrowths to osteomata, notwithstanding that the latter are at times remarkably symmetrical and generalised. In the formations in Mr. Spencer's specimen we have seen no trace of cartilage, though, as told by microscopic examination, the osseous outgrowths are still extending; this, amongst other reasons, we think, marks off the condition from that of multiple osteomata, as seen on the long bones.

We incline to regard the disease as of an inflammatory nature, and, since traumatic and thermal causes may be excluded, hardly more can be said than that the cause may provisionally be assumed to be some chemical irritant, either organised or not, the nature of which remains to be discovered.

We may draw attention to the fact that in animals symmetrical lesions of the bones of an inflammatory nature, and altogether

Digitized by Google

different from any occurring in rickets, have been long known. Such are those referred to by Sir James Paget,[1] but of these, which anatomically are closely, like the osseous lesions in the human subject, probably too exclusively taken as syphilitic, no cause has yet been satisfactorily assigned.

ROBERT WILLIAM PARKER,
SAMUEL G. SHATTOCK.

---

3. *Camel with tuberculosis.* (*Card specimen.*)

By WALTER K. SIBLEY, M.B.

A portion of spleen and lower lobe of a lung from a camel (*Camelus dromedarius*), female, showing advanced tubercular deposit (Perlsucht).

The animal died in the Zoological Gardens after a residence of about four years. The mother appears to have died of a similar disease.

Post-mortem.—The general nutritive condition of the body fairly good, a considerable quantity of subcutaneous and subperitoneal adipose tissue present.

Lungs, especially the lower lobes, densely studded with nodules in size from a pea to a pigeon's egg; much serous fluid in the pleuræ, the surfaces of which, especially at the lower regions, are densely beset with small round tubercles forming dense fringes, the several nodules being attached to one another by bands of fibrous tissue like pearls on a string. These are adherent to both pleural surfaces, and extend on to the surface of the diaphram.

Spleen is also densely studded with nodules of a similar character. A few isolated, rather smaller, deposits especially in the superficial regions of the liver, and these often tending to become separated from the surrounding liver tissue. There were slight peritoneal adhesions and a small quantity of clear fluid in the abdominal cavity. There was no joint lesion. The deposits were all very firm on section, the smaller ones a mass of dry dense caseous material; the larger were very gritty and contain a large amount of calcareous material in their centre.

[1] 'Surgical Pathology,' Lect. 1. There are similar specimens in University College and other museums.

Digitized by Google

Microscopically the deposits consist almost entirely of caseous material, a few tubercle bacilli are seen in the more peripheral regions, the outline of the deposits is not sharply defined, and there is but little fibrous tissue surrounding them. *May 7th*, 1889.

---

4. *Supernumerary limbs in frogs and toads.* (*Card specimen.*)

By J. Bland Sutton.

Recently, whilst engaged in studying dichotomy in the various divisions of the animal kingdom, I came to the conclusion on theoretical grounds that supernumerary limbs should frequently occur among Amphibians. This induced me to search zoological literature for records of such malformations. The search was far from satisfactory, but an inquiry for actual specimens has led to better results.

My first specimen was obtained from the Zoological Gardens; it is

Woodcut 10.

A Frog, *Rana temporaria*, with a supernumerary fore limb.

a fairly grown example of the common frog, *Rana temporaria*, with an accessory fore limb (Woodcut 10) furnished with three digits. The

Digitized by Google

limb was firmly attached to the left half of the shoulder-girdle by means of a piece of bone resembling a supernumerary coracoid. The museum of University College, London, has a specimen of a young toad, *Bufo vulgaris*, with a supernumerary hind limb pro-

Woodcut 11.

A young Toad, *Bufo vulgaris*, with a supernumerary hind limb.

jecting from the right side of its pelvis; this leg has the usual segments, femur, crus, and pes, and the extremity is furnished with seven digits. The femur articulates with the pelvis by a socket on the dorsal aspect of the normal acetabulum (Woodcut 11). The relation of the leg, in that its axis is at right angles to the toad's trunk, is unusual; in other cases it projects between the normal limbs. Among recorded examples of this malformation may be mentioned a frog, *Rana palustris*, with a supernumerary hind limb furnished with three digits; two were well formed, the third rudimentary, described by Tuckerman.[1]

The Teratological collection of the Museum of the Royal College of Surgeons contains an adult frog with a small accessory fore limb springing from the lateral and posterior part of the sternum. It is a *Hunterian* specimen. Mr. Boulanger informs me that he has observed many specimens of supernumerary legs in frogs, and Mr. W. K. Sibley tells me that whilst studying in Professor Recklinghausen's museum at Strasburg he came across a store bottle containing several such frogs.

One of the earliest descriptions of supernumerary limbs in frogs is contained in an interesting and elaborate pamphlet published in

[1] 'Journal of Anat. and Physiology,' vol. xx, p. 516.

Digitized by Google

Leyden, 1837, by Dr. J. van Deen. As the pamphlet is a rare one the drawing of the frog is reproduced below (Woodcut 12). The limbs

WOODCUT 12.

A Frog, *Rana esculenta*, with two supernumerary hind legs. (After van Deen.)

were connected with the frog by means of two fused ilia; the latter were attached to the ventral aspect of the normal pelvis.

November 20th, 1888.

---

5. *Cyst of undescended testis of an imperfectly developed male sheep.*

By FREDERIC S. EVE.

[With Plate XXXIII.]

A SPHERICAL CYST four and a half inches in diameter, which occupied the pelvis of a sheep. It is connected with the urinary bladder by a membrane, along which the vas deferens

Digitized by Google

courses. This duct, except at its termination, is thin, membranous, and impervious, and is lost on the wall of the cyst, which was filled with a greenish-grey material of putty-like consistence, and chiefly composed of fat. Part of the cyst wall is covered with outspread bands of striped muscle.

The cyst wall was composed of an inner layer of embryonic round-celled tissue, a middle layer of spindle-cells, and an outer layer of fibrous tissue; these layers probably represent different stages of development in the formation of fibrous tissue. No epithelial lining existed.

The person who brought the specimen to the Royal College of Surgeons' Museum stated that it was taken from a female sheep, but this is clearly erroneous, since the parts are evidently those of a male, the vasa deferentia opening upon the floor of the urethra. The cyst either represents an undifferentiated genital gland, or was developed in connection with the Wolffian body. Since the butcher mistook the sex of the animal it is probable that it was an androgynous male (hermaphrodite), and the condition observed supports this view.

In this case the arrest of development shown in the external genitals appears to have involved also the testis, which remained in the abdomen, and became distended with fatty matter, forming a cyst. The mode of formation of the fatty contents is enigmatical, for neither an epi- nor endo-thelial lining existed.

The microscopic structure of the cyst wall suggests that these resulted from a continuous formation and fatty degeneration of a layer of granulation tissue on its inner surface. The specimen in this respect points to a new mode of formation of congenital fat-cysts. The condition of the testis could, from the circumstances of the case, not be determined.

The specimen is preserved in the Royal College of Surgeons' Museum, No. 4217A. *March 5th*, 1889.

Digitized by Google



Digitized by Google

EXPLANATION OF PLATE XXXIII.

To illustrate Mr. Eve's paper on Cyst of Retained Testicle of Sheep (Page 463).

a. Cyst.
b. Vas deferens.
c. Vesicula seminalis.
d. Bladder.

Digitized by Google

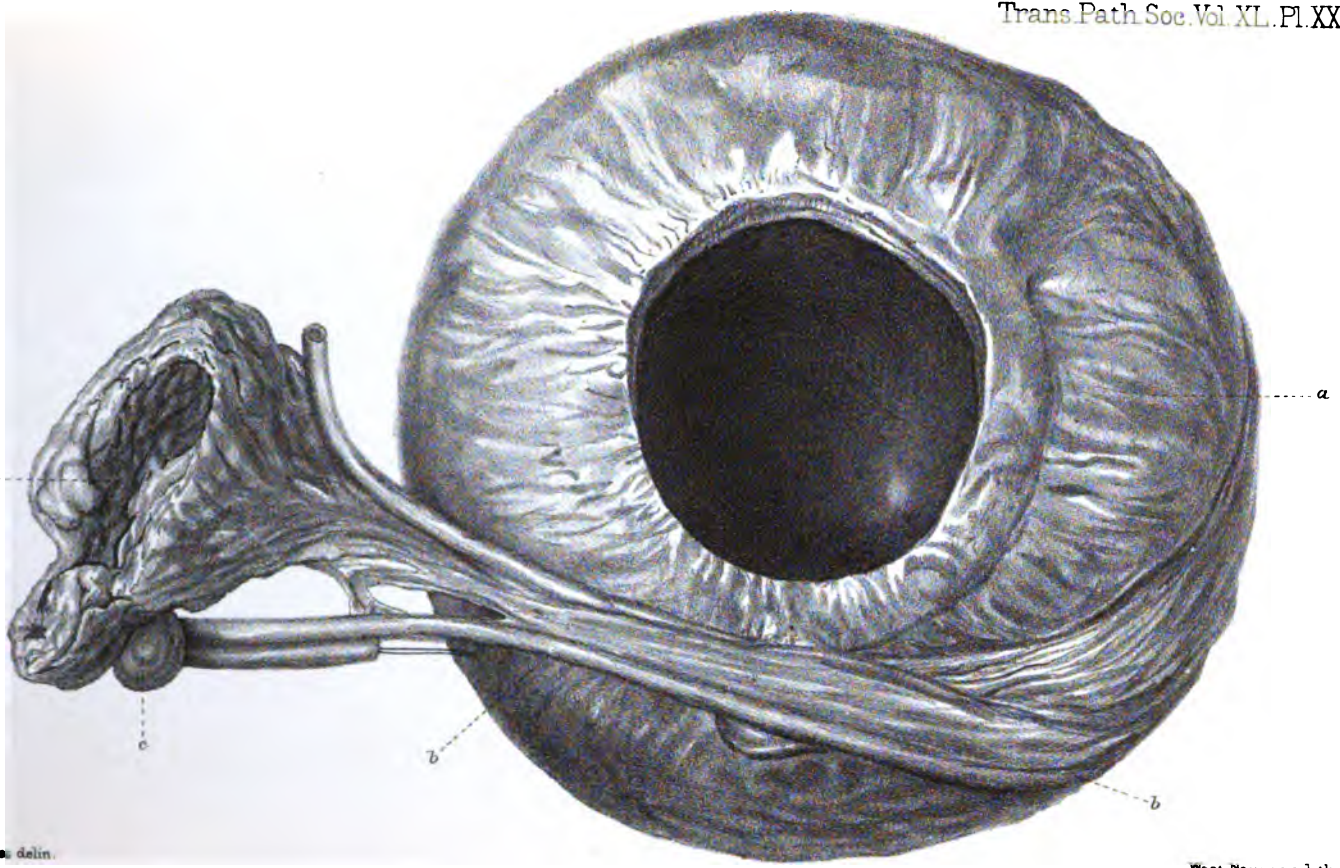

C.D. Burges, delin.

West, Newman lith.

Digitized by Google

Digitized by Google

INDEX.

PAGE

ABNORMALITIES, congenital, of the lower ileum (L. Hudson) . . 98

ABSCESS of epididymis (A. M. Sheild) 182
„ tubercular, of the breast (S. G. Shattock) . . . 391

ACTINOMYCOSIS of the liver, case of (F. S. Eve) 405
„ hominis (S. Delépine) 408
„ of the lower jaw of a heifer (S. G. Shattock) . . . 404

ADAMS (WILLIAM), the late Dr. Carnochan's specimen of the so-called congenital dislocation of both hip-joints: sent from New York . 237

ADDISON'S DISEASE, symmetrical tubercular disease of the suprarenal capsules in which tubercle bacilli were found, from a case of (V. Harris) 300

ALBUMINURIA, kidney from a case in which was hereditary (W. H. Dickinson) 144

ALCOHOLIC NEURITIS, cast of the right leg from a case of (D'A. Power) 403

ALCOHOLISM, chronic, discussion on the morbid anatomy and pathology of (introduced by J. F. Payne) 310
„ — — (Lionel Beale) 337
„ — — (Thomas Buzzard) 344
„ — — (W. H. Dickinson) 341, 384
„ — — (D. W. Finlay) 354
„ — — (W. B. Hadden) 365
„ — — (George Harley) 333
„ — — (Stephen Mackenzie) 339
„ — — (F. W. Mott) 340
„ — — (Bernard O'Connor) 374
„ — — (J. A. Ormerod) 368
„ — — (Isambard Owen) 370
„ — — (D. R. Pearson) 375
„ — — (G. N. Pitt) 347
„ — — (G. H. Savage) 261
„ — — (Seymour J. Sharkey) 356

ALLINGHAM'S inguinal colotomy (G. R. Turner) . . . 114

ANÆMIA, pernicious, iron in the liver in (F. W. Mott) . . 127

ANATOMY, morbid, discussion on the, of chronic alcoholism . . 310

ANEURYSM, aortic, which burst into the œsophagus (F. Penrose) . 62
„ at the junction of the transverse and descending portion of the arch of the aorta, which ruptured into the pericardium (S. Herbert Habershon) 62
„ of the right brachial and ulnar arteries, resulting from embolism (F. W. Mott) 71

Digitized by Google

ANEURYSM (*continued*)— PAGE
„ of the splenic vessels, arterio-venous, with thrombosis of mesenteric veins and localised acute colitis (James F. Goodhart) . . 67
„ of the thoracic aorta bursting into the œsophagus just above the diaphragm, causing fatal hæmatemesis (John R. Lucas) . . 66
ANIMALS, lower, diseases, &c., of the . . . 449–464
AORTA, aneurysm at the junction of the transverse and descending portion of the arch of the, which ruptured into the pericardium (S. Herbert Habershon) 62
„ atheromatous disease of, and arteries of lower limbs (Christopher Heath) 61
„ thrombosis of (G. Newton Pitt) 74
APPENDIX CÆCI, retro-cæcal hernia of the (L. A. Dunn) . . 114
ARTERIES, brachial and ulnar, aneurysm of (F. W. Mott) . . 71
„ of lower limbs, atheromatous disease of aorta and (C. Heath) . 61
ARTERITIS (A. Money) 13
ARTERY, pulmonary, embolism of (M. Berkeley Hill) . . . 45
AURICLE, enlarged, compressing left bronchus (H. H. Taylor) . . 58

BATTLE (WILLIAM HENRY), ectopion of the cæcum with other malformations, and prolapse of the intestine through the ileo-cæcal valve . 120
BEALE (LIONEL), discussion on alcohol 337
BILE-DUCT, carcinoma of gall-bladder and (J. Griffiths) . . 140
BLADDER, vesiculation of the mucous membrane of the (Quarry Silcock) . 175
BONE, metacarpal, osteoma of the (J. Hutchinson) . . . 263
„ tumours of, from a dog (W. G. Spencer) 457
BONES of goats, disease of the (W. G. Spencer) . . . 449
BOWLBY (ANTHONY), cystine calculus 182
BRACHIAL and ulnar arteries, aneurysm of (F. W. Mott) . . 71
BRAIN, hæmorrhage into the pons of child aged six . . . 21
„ — into pons varolii 21
„ hydatid cyst (Hermann Weber) 17
„ infantile paralysis 22
„ meningeal tuberculosis 9
„ pseudo-hypertrophic paralysis, degeneration and atrophy of the nerve-trunks 24
„ sarcoma, symmetrical 19
„ syphilitic meningitis, &c. (A. Money) 13
„ tumours (tubercular) 20
BREAST, duct, cancer of (H. B. Robinson) 285
„ tubercular abscess of (S. G. Shattock) 391
BRIGHT'S DISEASE, ulcers of intestine and stomach from a case of (R. G. Hebb) 92
BRISCOE (JOHN FREDERICK), osteo-porosis of the calvarium, shown in the fragments of a skull found on the island of Lamoo, Zanzibar, June 8th, 1888 252
BRONCHI, complete rupture of (A. Marmaduke Sheild) . . 39
BRONCHIAL GLAND, caseous, perforating and obstructing the trachea (G. Gulliver) 38
BRONCHUS, enlarged auricle compressing left mitral stenosis (H. H. Taylor) 58
„ primary carcinoma of the left (H. Handford) . . . 40
BROWNE (LENNOX), congenital growths in the larynx . . . 34
BUZZARD (THOMAS), discussion on alcohol 344

Digitized by Google

PAGE

CÆCAL VALVE, ulceration of the cæcum, followed by almost complete occlusion of the (F. W. Mott) 107
CÆCUM, ectopion of the, with other malformations (W. H. Battle) . 120
„ perforated, from a case of volvulus of sigmoid flexure (F. W. Mott) . 106
„ ulceration of the (F. W. Mott) 107
CALCIFICATION, diffuse, of the liver (J. H. Targett) . . . 123
CALCULI, encysted prostatic (W. B. Clarke) . . . 179
CALCULUS, cystine (A. Bowlby) 182
„ in ureter: disorganisation of kidney (F. D. Drewitt) . . 172
„ nasal (S. Jones) 401
CALVARIUM, osteo-porosis of the (J. F. Briscoe) . . . 252
CANCER, duct, of breast (H. B. Robinson) 285
„ epithelial (J. Hutchinson, F.R.S.) 275
„ of prostate (B. Hill) 181
„ of the large intestine (R. Johnson) 110
„ of the pancreas, causing biliary obstruction (W. Henry Kesteven) . 140
„ of the stomach (James F. Goodhart) 78
„ sequel to the case of primary, of the Fallopian tube (Alban Doran) . 221
CARCINOMA, columnar-celled, of the ovary (S. G. Shattock) . . 208
„ of gall-bladder and bile-duct (J. Griffiths) . . . 140
„ of liver (L. Hudson) 137
„ primary, of the left bronchus (H. Handford) . . . 40
CARCINOMATODES cylindroma (R. G. Hebb) . . . 284
CARNOCHAN'S (Dr.), specimen of the so-called congenital dislocation of both hip-joints (W. Adams) 237
CEREBRAL ATROPHY (A. Money) 13
„ Disease, see *Brain*.
CERVICAL VERTEBRÆ, synostosis of upper (L. A. Dunn) . . 264
CHARCOT'S joint, disease of shoulder (J. R. Lunn) . . . 251
CHONDROMA, pedunculated, from knee-joint (S. G. Shattock) . . 282
„ pedunculated, removed from the knee-joint (S. G. Shattock) . . 256
CHYLOUS FLUID removed from tunica vaginalis (S. Jones) . . 183
CIRCULATION, diseases, &c., of the organs of . . 57–75
CIRRHOSIS of liver in a child (J. H. Targett) . . . 136
„ of the liver (James F. Goodhart) 134
„ — see *Pathology of Chronic Alcoholism* . . . 310
„ pericellular, of liver (J. A. Ormerod) 137
CLARKE (W. **BRUCE**), encysted prostatic calculi . . . 179
COLITIS, ulcerative, with extensive perforation (J. A. Ormerod) . 109
COLLIER (**WILLIAM**), hæmorrhage in the pons of child aged six . . 21
COLOTOMY, Allingham's inguinal (G. R. Turner) . . . 114
CONCRETION, phosphatic, from a recto-vaginal fistula (A. H. Robinson) . 402
CRETINISM, fœtal (J. H. Targett) 385
CRICOID CARTILAGES, fracture of thyroid and (H. Montague Murray) . 36
CROCKER (H. **RADCLIFFE**), Paget's disease, affecting the scrotum and penis 187
CROOKE (**GEORGE** F.), two cases of unilateral nephritis, with atrophy of the kidney induced by pressure; (1) on the ureter, and (2) on the renal blood-vessels 153
CYLINDROMA CARCINOMATODES (R. G. Hebb) . . . 284
CYST, congenital, of the tongue (H. A. Lediard) . . . 281
„ dermoid, near knee (J. H. Targett) 388

Digitized by Google

PAGE

CYST, dermoid (*continued*)—
„ — of lumbro-sacral region 386
„ hydatid, on the left cerebral hemisphere (Hermann Weber) . . 17
„ rupture of, extra-uterine fœtation (F. W. Mott) . . . 197
CYSTERCUS CELLULOSÆ from human muscle (H. B. Robinson) . 388
CYSTIC dilatation in a cirrhotic granular kidney (S. G. Shattock) . 159
CYSTINE CALCULUS (A. Bowlby) 182
CYSTS, mucous, in the mouth (W. G. Spencer) . . . 400
„ psorospermial, of both ureters (F. S. Eve) . . . 444

DALTON (NORMAN), tumours, tubercular, in the brain of a child . . 20
DAVIES (ARTHUR), lymphosarcoma of left lung . . . 46
„ — of right suprarenal body: the right kidney . . . 300
DELÉPINE (SHERIDAN), actinomycosis hominis . . . 408
DICKINSON (W. H.), kidney from a case in which albuminuria was hereditary 144
„ discussion on alcohol 341, 384
DIGESTION, diseases, &c., of the organs of . . . 76–143
DIPHTHERITIC MEMBRANE expelled from a tracheal wound (F. E. Nichol) 37
DISCUSSION on the morbid anatomy and pathology of chronic alcoholism, introductory address (Joseph Frank Payne) . . 310
DISEASES and injuries of the osseous system . . 229–274
„ — &c., of the organs of circulation . . . 57–75
„ — of the organs of digestion 76–143
„ — of the ductless glands 299–302
„ — of the lower animals 449–464
„ — of the nervous system 9–33
„ — of the organs of respiration . . . 34–56
„ — of the skin 303–309
„ — of the genito-urinary organs . . . 144–228
DISLOCATION, notes on a case of, of shoulder (D'Arcy Power) . . 235
„ of both hip-joints, congenital, the late Dr. Carnochan's specimen of the so-called (W. Adams) 237
DOG, multiple symmetrical tumours of bone from a (W. G. Spencer) . 457
DORAN (ALBAN), large ovarian tumours in a seven months' child . 200
„ sequel to the case of primary cancer of the Fallopian tube reported in the Thirty-ninth volume of the Society's 'Transactions' . . 221
DREWITT (F. D.), calculus in ureter, disorganisation of kidney . . 172
DUCTLESS GLANDS, diseases, &c., of the . . . 299–302
DUNN (L. A.), defective development of right fibula . . . 272
„ epiphysitis of the upper extremity of the humerus . . . 265
„ retro-cæcal hernia of the appendix cæci 114
„ synostosis of upper cervical vertebræ 264
DWARF, Norwich, an account of the skeleton of the (J. Hutchinson) . 229

ECTOPION of the cæcum with other malformations (W. H. Battle) . 120
EDMUNDS (WALTER), tubercular disease of ovary . . . 210
ELBOW, sarcoma of forearm growing into a large vein at the bend of . 297
ENTERIC FEVER, hepatitis in (H. Handford) . . . 129
EPIDIDYMIS, abscess of (A. M. Sheild) 182
EPHIPYSITIS of the upper extremity of the humerus (L. A. Dunn) . 265

Digitized by Google

PAGE

EPITHELIAL CANCER (J. Hutchinson, F.R.S.) . . . 275

EPITHELIOMA, columnar, of the ileo-cæcal valve, complicated by a post-cæcal abscess, and with secondary growths in the mesocolic glands, liver, and lungs (A. Money) 103

„ of floor of mouth, tongue, and lower jaw (C. Heath) . . 283

„ of the male urethra (J. Griffiths) 177

EVE (FREDERICK S.), case of actinomycosis of the liver . . 405

„ cyst of undescended testis of an imperfectly-developed male sheep . 463

„ extra-vaginal hæmatocele of scrotum 183

„ psorospermial cysts of both ureters 444

„ and TARGETT, J. H., sarcoma of forearm growing into a large vein at the bend of elbow 297

FALLOPIAN tube, sequel to the case of primary cancer of the (Alban Doran) 221

FEET, cast of a child's (W. G. Spencer) 251

FIBULA, defective development of right (L. A. Dunn) . . . 272

FINLAY (D. W.), discussion on alcohol 354

FISTULA, phosphatic concretion from a recto-vaginal (A. H. Robinson) . 402

FŒTATION, extra-uterine, rupture of cyst (F. W. Mott) . . 197

FOOT, perforating ulcer of (A. M. Sheild) 390

FOREARM, sarcoma of (F. S. Eve and J. H. Targett) . . . 297

FRACTURE of thyroid and cricoid cartilages (H. Montague Murray) . 86

FROGS, supernumerary, in frogs and toads (J. B. Sutton) . . 461

GALL-BLADDER, carcinoma of, and bile-ducts (J. Griffiths) . . 140

GENITO-URINARY organs, diseases, &c., of the . . 144–228

GLANDS, ductless, diseases, &c., of the . . . 299–302

GOATS, bones of, disease of the (W. G. Spencer) . . . 449

GOITRE, congenital (H. A. Lediard) 299

GOLDING-BIRD (C. H.), a case of tubercular teno-synovitis . . 244

GONORRHŒA, surgical kidney after (F. Penrose) . . . 161

GOODHART (JAMES F.), arterio-venous, aneurysm of splenic vessels, with thrombosis of mesenteric veins and localised acute colitis . . 67

„ a case of cirrhosis of the liver, probably originating in phlebitis of the portal vein 134

„ cancer of the stomach, originating in a chronic ulcer . . 78

"**GRANULAR SHAGREEN**" appearance of the ependyma (A. Money) . 13

GRIFFITH (W. S. A.), tubercle of the ovaries . . . 212

„ tubercle of the ovary 219

GRIFFITHS (J.), carcinoma of gall-bladder and bile-duct . . 140

„ epithelioma of the male urethra 177

„ the histological changes in the kidney in hydronephrosis . . 161

GULLIVER (G.), caseous bronchial gland perforating and obstructing the trachea 38

„ syphilitic ulceration of trachea and larger bronchi . . . 39

HABERSHON (S. Herbert), aneurysm at the junction of the transverse and descending portion of the arch of the aorta, which ruptured into the pericardium 62

HADDEN (W. B.), discussion on alcohol 365

HÆMATOCELE, extra-vaginal, of scrotum (F. S. Eve) . . . 183

Digitized by Google

PAGE

HÆMORRHAGE into the pons of child aged six (W. Collier) . . 21
„ into pons Varolii (J. A. Ormerod) 21
HANDFORD (H.), diffuse sarcoma of the stomach . . . 89
„ hepatitis in enteric fever 129
„ myxo-sarcoma, six recurrences in twenty-three years . . 291
„ primary carcinoma of the left bronchus 40
„ pseudo-hypertrophic paralysis, degeneration and atrophy of the nerve-trunks 24
HARLEY (GEORGE), discussion on alcohol 333
HARRIS (Vincent), symmetrical tubercular disease of the suprarenal capsules, in which tubercle bacilli were found, from a case of Addison's disease 300
HEART, aneurysm at the junction of the transverse and descending portion of the arch of the aorta 62
„ fatty, from a case of chronic alcoholism (F. W. Mott) . . 57
„ mitral stenosis, enlarged auricle compressing left bronchus . . 58
„ rupture of the, unusual form of (W. H. White) . . . 58
„ stenosis of mitral and tricuspid valves 60
HEATH (CHRISTOPHER), atheromatous disease of aorta and arteries of lower limbs 61
„ epithelioma of floor of mouth, tongue, and lower jaw . . 283
„ retro-peritoneal sarcoma 295
HEBB (R. G.), granuloma tumour of skin (? lupus) . . . 298
„ infantile paralysis 22
„ lympho-sarcoma of kidney 296
„ stenosis of mitral and tricuspid valves 60
„ "tumour" of skin (cylindroma carcinomatodes) . . . 284
„ ulcers of intestine and stomach from a case of chronic Bright's disease 92
HEIFER, actinomycosis of the lower jaw of a (S. G. Shattock) . . 404
HEPATITIS in enteric fever (H. Handford) . . . 129
HEREDITARY, kidney from a case in which albuminuria was (W. H. Dickinson) 144
HERNIA, lumbar (J. Hutchinson) 117
„ retro-cæcal, of the appendix cæci (L. A. Dunn) . . . 114
HERNIAL sacs and their contents (C. B. Lockwood) . . . 115
HILL (BERKELEY) cancer of prostate 181
„ embolism of pulmonary artery 45
HIP-JOINTS, dislocation of both (W. Adams) . . . 237
HISTOLOGICAL changes in the kidney in hydronephrosis (J. Griffiths) . 161
HUDSON (LEOPOLD), on congenital abnormalities of the lower ileum . 98
„ primary carcinoma of liver 137
HUMERUS, epiphysitis of the upper extremity of the (L. A. Dunn) . 265
HUTCHINSON (JONATHAN, F.R.S.), an account of the skeleton of the Norwich dwarf 229
„ large fatty tumour in the scrotum surrounding the testis, but not adherent to it 191
„ sarcoma of the testicle, following on removal of the other for hypertrophy of a doubtful nature, which the microscope had declared not sarcomatous 193
„ "the crateriform ulcer of the face," a form of acute epithelial cancer . 275
HUTCHINSON (JONATHAN, jun.), lumbar hernia . . . 117
„ osteoma of the metacarpal bone 263
„ syphilitic disease of the knee-joint and kidneys . . . 266

Digitized by Google

PAGE

HYDATID CYST on the left cerebral hemisphere (Hermann Weber) . 17
HYDROCEPHALUS (A. Money) 13
HYDRONEPHROSIS, histological changes in the kidney in (J. Griffiths) . 161
HYPERTROPHY, sarcoma of the testicle, following on removal of the other for (J. Hutchinson) 193

ILEO-CÆCAL VALVE, columnar epithelioma of the, complicated by a post-cæcal abscess (A. Money) 103
„ — ulceration of the cæcum followed by almost complete occlusion of the (F. W. Mott) 106
ILEUM, on congenital abnormalities of the (L. Hudson) . . 98
INFANTILE PARALYSIS (R. G. Hebb) 22
INGUINAL COLOTOMY, Allingham's (G. R. Turner) . . . 114
INTESTINE, cancer of the large (R. Johnson) . . . 110
„ obstruction of small, by a ring formed by adhesion between contiguous appendices epiploicæ (E. C. Perry) 93
„ prolapse of the, through the ileo-cæcal valve (W. H. Battle) . . 120
„ ulcers of (R. G. Hebb) 92
INTESTINES, lymphadenoma of the stomach and (G. Newton Pitt) . 80
IRON in the liver in pernicious anæmia (F. W. Mott) . . . 127

JACKSON (A. M.), cystic degeneration of kidneys, with two ureters on right side 160
JAW OF A HEIFER, actinomycosis of the lower (S. G. Shattock) . 404
„ lower, epithelioma of (C. Heath) 283
JOHNSON (RAYMOND), two cases of cancer of the large intestine . 110
JOINT, Charcot's disease of shoulder (J. R. Lunn) . . . 251
JONES (SYDNEY), chylous fluid removed from tunica vaginalis . . 183
„ nasal calculus 401
„ tumour removed from Scarpa's triangle 286

KESTEVEN (W. HENRY), a case of primary cancer of the pancreas causing biliary obstruction 140
KIDNEY, absence of upper two thirds of left ureter, with very small cystic (F. Penrose) 161
„ cirrhotic granular, cystic dilatation in a (S. G. Shattock) . . 159
„ cystic degeneration of, with two ureters on right side (A. M. Jackson) 160
„ disorganisation of, calculus in ureter (F. D. Drewitt) . . 172
„ from a case in which albuminuria was hereditary (W. H. Dickinson) . 144
„ histological changes in the, in hydronephrosis (J. Griffiths) . 161
„ lympho-sarcoma of (R. G. Hebb) 296
„ lympho-sarcoma of right suprarenal body: the right (A. Davies) . 300
„ malposition of (A. Primrose) 172
KIDNEYS, syphilitic disease of (J. Hutchinson, jun.) . . . 266
KNEE, dermoid cyst near (J. H. Targett) 388
KNEE-JOINT, pedunculated chondroma from (S. G. Shattock) . . 282
„ pedunculated chondroma removed from the (S. G. Shattock) . . 256
„ syphilitic disease of (J. Hutchinson, jun.) . . . 266

LARYNX, congenital growths in the (Lennox Browne) . . 84
LEDIARD (H. A.), congenital cyst of the tongue . . . 281
„ — goitre 299

Digitized by Google

PAGE

LEG, cast of the right (D'Arcy Power) 403
LEPROSY, a case of (J. W. Washbourn) 307
LIMBS, supernumerary, in frogs and toads (J. B. Sutton) . . 461
LIVER, actinomycosis of the (F. S. Eve) 405
„ calcification of the (J. H. Targett) 123
„ cirrhosis of, in a child (J. H. Targett) 136
„ — see *Pathology of Chronic Alcoholism.*
„ columnar epithelioma of the ileo-cæcal valve, complicated by a post-cæcal abscess, and with secondary growths in the mesocolic glands and in the (A. Money) 103
„ hepatitis in enteric fever 129
„ internal rupture of (J. H. Targett) 133
„ iron in the, in the pernicious anæmia (F. W. Mott) . . 127
„ melanotic sarcoma of (N. Moore) 138
„ pericellular cirrhosis of (J. A. Ormerod) 137
„ primary carcinoma of (L. Hudson) 137
„ syphilitic (F. Penrose) 133
„ tubercular excavation of (F. Wethered) 139
LOCKWOOD (C. B.), some hernial sacs and their contents . . 115
LUCAS (JOHN R.), aneurysm of the thoracic aorta bursting into the œsophagus just above the diaphragm, causing fatal hæmatemesis . 66
LUMBO-SACRAL region, dermoid cyst of (Leonard Wylde) . . 386
LUNG, lymphosarcoma of left (Arthur Davies) . . . 46
LUNGS, columnar epithelioma of the ileo-cæcal valve complicated by a post-cæcal abscess, and with secondary growths in the mesocolic glands, liver, and (A. Money) 103
LUNN (JOHN R.), disease of shoulder (Charcot's joint) . . 251
LUPUS GRANULOMA, tumour of skin (R. G. Hebb) . . . 298
LYMPHADENOMA of the stomach and intestines (G. Newton Pitt) . 80
LYMPHOSARCOMA of left lung (Arthur Davies) . . . 46

MACKENZIE (H. W. G.), blood concretions in the ovaries . . 198
„ simple ulcers of œsophagus 76
MACKENZIE (STEPHEN), localised symmetrical œdema . . . 403
„ discussion on alcohol 339
MAGUIRE (ROBERT), lymphosarcoma of the mediastinum, involving the large blood-vessels 47
MEDIASTINAL growth involving the pericardium and heart (F. W. Mott) 47
MEDIASTINUM, lymphosarcoma of the, involving the large blood-vessels (Robert Maguire) 47
MELANOTIC SARCOMA of liver (Norman Moore) . . . 138
MENINGEAL TUBERCULOSIS (H. Sainsbury) . . . 9
MESOCOLIC GLANDS, columnar epithelioma of the ileo-cæcal valve, complicated by a post-cæcal abscess and with secondary growths in the (A. Money) 103
METACARPAL BONE, osteoma of the (J. Hutchinson) . . 263
MISCELLANEOUS specimens 385–448
MITRAL STENOSIS, enlarged auricle compressing left bronchus (H. H. Taylor) 58
MONEY (ANGEL), a case of columnar epithelioma of the ileo-cæcal valve, complicated by a post-cæcal abscess and with secondary growths in the mesocolic glands, liver, and lungs 103

Digitized by Google

MONEY (ANGEL) (*continued*)— PAGE
„ chronic syphilitic meningitis, arteritis, and cerebral atrophy, sclerosis in boy of four, with histological notes 13
„ mediastinal sarcoma in an infant aged fifteen months . . 54
MOORE (NORMAN), melanotic sarcoma of liver . . . 138
MORBID ANATOMY of chronic alcoholism, discussion on the . . 310
„ growths and tumours 275–298
MOTT (F. W.), aneurysm of the right brachial and ulnar arteries resulting from embolism 71
„ discussion on alcohol 341
„ extra-uterine fœtation; rupture of cyst; abdominal section; peritonitis; death 197
„ fatty heart from a case of chronic alcoholism . . . 57
„ free iron in the liver in pernicious anæmia . . . 127
„ perforated cæcum from a case of volvulus of sigmoid flexure, vermiform appendix measuring seven inches 106
„ two anomalous vermiform appendices 105
„ two cases of mediastinal growth involving the pericardium and heart . 47
„ ulceration of the cæcum followed by almost complete occlusion of the ileo-cæcal valve 106, 107
MOUTH, epithelioma of floor of (C. Heath) 283
MUCOUS CYSTS in the mouth (W. G. Spencer) . . . 400
MURRAY (H. MONTAGUE), fatty tumour in wall of stomach . . 78
„ fracture of thyroid and cricoid cartilages . . . 36
MUSCLE, cysticercus cellulosæ from human (H. B. Robinson) . . 388
MYXO-LIPOMA of the spermatic cord (J. H. Targett) . . . 282
MYXO-SARCOMA (H. Handford) 291

NEOPLASTIC PROCESS IN TREES, specimens illustrating the (W. R. Williams) 446
NEPHRITIS, unilateral, with atrophy of the kidney (G. F. Crooke) . 153
NERVE-TRUNKS, degeneration and atrophy of the (H. Handford) . 24
NERVOUS SYSTEM, diseases of 9–33
NEURITIS, alcoholic (D'A. Power) 403
NICHOL (F. E.), diphtheritic membrane expelled from a tracheal wound . 37
NORWICH DWARF, an account of the skeleton of the (J. Hutchinson) . 229

OBSTRUCTION, biliary, cancer of the pancreas causing (W. H. Kesteven) . 140
„ of small intestine by a ring formed by adhesion between contiguous appendices epiploicæ (E. C. Perry) 93
O'CONNOR (BERNARD), discussion on alcohol 374
ŒDEMA, localised symmetrical (S. Mackenzie) . . . 403
ŒSOPHAGUS, aortic aneurysm which burst into (F. Penrose) . . 62
„ sarcoma of (J. H. Targett) 76
„ simple ulcers of (H. W. G. Mackenzie) . . . 76
ORMEROD (J. A.), hæmorrhage into pons Varolii . . . 21
„ hæmorrhagic sarcoma 290
„ pericellular cirrhosis of liver 137
„ sarcoma, symmetrical, of both cerebral hemispheres . . 19
„ thrombosis of veins of neck 75
„ ulcerative colitis with extensive perforation . . . 109
„ discussion on alcohol 368

Digitized by Google

PAGE

OSSEOUS SYSTEM, diseases and injuries of . . . 229–274
OSSIFYING SARCOMA, a complete case of (D'A. Power) . . 293
OSTEITIS, syphilitic, of tibiæ (G. N. Pitt) 270
OSTEO-ARTHRITIS, structure of the eburnated substance in two specimens of advanced (S. G. Shattock) 254
OSTEO-POROSIS of the calvarium, shown in the fragments of a skull (J. F. Briscoe) 252
OVARIAN, large, tumours in a seven months' child (A. Doran) . . 200
OVARIES, blood concretions in the (H. W. G. Mackenzie) . . 198
„ tubercle of the (W. S. A. Griffith) 213
OVARY, columnar-celled carcinoma of the (S. G. Shattock) . . 208
„ tubercle of the (W. S. A. Griffith) 219
„ tubercular disease of (W. Edmunds) 210
OWEN (ISAMBARD), discussion on alcohol 370

PAGET'S DISEASE, affecting the scrotum and penis (H. R. Crocker) . 187
PANCREAS, cancer of the (W. H. Kesteven) . . . 140
PARALYSIS, infantile (R. G. Hebb) 22
PATHOLOGY of chronic alcoholism, discussion on the morbid anatomy and 310
PAYNE (JOSEPH FRANK), introductory address, discussion on the morbid anatomy and pathology of chronic alcoholism . . . 310
„ reply 377
PEARSON (D. R.), discussion on alcohol 375
PEDUNCULATED CHONDROMA removed from the knee-joint (S. G. Shattock) 256
PEMPHIGUS MALIGNUS (G. N. Pitt) 303
PENIS, Paget's disease affecting the (H. R. Crocker) . . . 187
PENROSE (FRANK), absence of upper two thirds of left ureter with very small cystic kidney, surgical right kidney after gonorrhœa . . 161
„ aortic aneurysm which burst into the œsophagus . . . 62
„ stricture of urethra, death caused by a false passage made by the patient 174
„ syphilitic liver, in which the left lobe is much larger than the right . 133
„ ulcer of the stomach close to the pylorus 78
PERICARDIUM and heart, mediastinal growth involving the (F. W. Mott) 47
PERRY (E. C.), two cases of obstruction of small intestine by a ring formed by adhesion between contiguous appendices epiploicæ . . 98
PITT (G. NEWTON), lymphadenoma of the stomach and intestines . 80
„ pemphigus malignus 303
„ syphilitic osteitis of tibiæ 270
„ thrombosis of aorta 74
„ discussion on alcohol 347
PORTAL VEIN, cirrhosis of the liver, probably originating in phlebitis of the (James F. Goodhart) 134
POWER (D'ARCY), a complete case of ossifying sarcoma . . 293
„ cases of talipes 247
„ cast of the right leg from a case of alcoholic neuritis . . 403
„ notes on a case of dislocation of shoulder, without rupture of capsule . 235
PRIMROSE (A.), malposition of left kidney 172
PROSTATE, cancer of (B. Hill) 181
PROSTATIC, encysted, calculi (W. B. Clarke) . . . 179

Digitized by Google

PAGE

PSEUDO-HYPERTROPHIC PARALYSIS, affection of the heart and diaphragm; area of softening in the cord; degeneration and atrophy of the nerve-trunks (H. Handford) 24
PULMONARY ARTERY, embolism of (M. Berkeley Hill) . . 45

RAM, cyst of undescended testis of an imperfectly developed (F. S. Eve) . 463
RESPIRATION, diseases, &c., of the organs of . . 34–56
RICKETS causing changes in skull of Zanzibari child (J. F. Briscoe) . 252
ROBINSON (A. H.), phosphatic concretion from a recto-vaginal fistula . 402
ROBINSON (H. BETHAM), cysticercus cellulosæ from human muscle . 388
„ duct cancer of breast 285
RUPTURE of the heart, unusual form of (W. H. White) . . 58
„ of the liver, internal (J. H. Targett) . . . 133
SAINSBURY (HARRINGTON), meningeal tuberculosis . . . 9
SARCOMA, diffuse, of the stomach (H. Handford) . . . 89
„ hæmorrhagic (J. A. Ormerod) 290
„ lympho-, of kidney (R. G. Hebb) 296
„ — of right suprarenal body, the right kidney (A. Davies) . . 300
„ mediastinal, in an infant aged fifteen months . . . 54
„ melanotic, of liver (N. Moore) 138
„ myxo- (H. Handford) 291
„ of œsophagus (J. H. Targett) 76
„ ossifying (D'A. Power) 293
„ retro-peritoneal (C. Heath) 295
„ sarcoma of the testicle (J. Hutchinson) 193
„ (symmetrical) of both cerebral hemispheres (J. A. Ormerod) . 19
SAVAGE (G. H.), discussion on alcohol 261
SCARPA'S TRIANGLE, tumour removed from (S. Jones) . . 286
SCLEROSIS (A. Money) 13
SCROTUM, extra-vaginal hæmatocele of (F. S. Eve) . . . 183
„ large fatty tumour in the (J. Hutchinson) . . . 191
„ Paget's disease affecting the (H. R. Crocker) . . . 187
SHARKEY (SEYMOUR J.), discussion on alcohol . . . 356
SHATTOCK (S. G.), actinomycosis of the lower jaw of a heifer . . 404
„ columnar-celled carcinoma of the ovary 208
„ cystic dilatation in a cirrhotic granular kidney . . . 159
„ pedunculated chondroma from knee-joint . . . 282
„ — — removed from the knee-joint 256
„ the structure of the eburnated substance in two specimens of advanced osteo-arthritis 254
„ tubercular abscess of breast 391
SHEEP, cyst of undescended testis of an imperfectly developed male (F. S. Eve) 463
SHEILD (A. MARMADUKE), abscess of epididymis . . . 182
„ complete rupture of bronchi 39
„ perforating ulcer of foot 390
SHOULDER, disease of, Charcot's joint (J. R. Lunn) . . . 251
„ notes on a case of dislocation of (D'Arcy Power) . . . 235
SIBLEY (WALTER K.), camel with tuberculosis . . . 460
SILCOCK (QUARRY), case of vesiculation of the mucous membrane of the bladder 175
SKIN, diseases, &c., of the 303–309
„ granuloma tumour of (R. G. Hebb) 298
„ "tumour" of, cylindroma carcinomatodes (R. G. Hebb) . . 284

Digitized by Google

PAGE

SKULL, osteo-porosis of the calvarium shown in the fragments of a (J. F. Briscoe) 252
SPECIAL COMMUNICATIONS 310
SPENCER (W. G.), a disease of the bones of goats having points of resemblance to mollities ossium, osteitis deformans, and multiple sarcoma of bone 449
„ cast of a child's feet, taken shortly after birth, in a position of talipes varus and valgus 251
„ multiple symmetrical tumours of bone from a dog . . . 457
„ the formation of mucous cysts in the mouth . . . 400
„ varicocele, a spontaneous variation in the spermatic veins . . 185
SPERMATIC CORD, myxo-lipoma of the (J. H. Targett) . . 282
SPINA BIFIDA (J. B. Sutton) 273
STENOSIS of mitral and tricuspid valves (R. G. Hebb) . . 60
STOMACH, cancer of the (James F. Goodhart) . . . 78
„ diffuse sarcoma of the (H. Handford) 89
„ fatty tumour in wall of (H. Montague Murray) . . 78
„ lymphadenoma of the, and intestines (G. Newton Pitt) . . 80
„ ulcer of the, close to the pylorus (Frank Penrose) . . 78
„ ulcers of (R. G. Hebb) 92
SUPRARENAL BODY, lymphosarcoma of right (A. Davies) . . 300
„ capsules, symmetrical tubercular disease of the (V. Harris) . . 300
SUPRARENALS, disease of (H. H. Taylor) 299
SUTTON (J. BLAND), spina bifida 273
„ supernumerary limbs in frogs and toads 461
SYNOSTOSIS of upper cervical vertebræ (L. A. Dunn) . . 264
SYPHILITIC DISEASE of the knee-joint and kidneys (J. Hutchinson, jun.) 266
„ liver, in which the left lobe is much larger than the right (F. Penrose) 133
„ meningitis (A. Money) 13

TALIPES, cases of (D'Arcy Power) 247
„ varus and valgus, cast of a child's feet taken shortly after birth in a position of (W. G. Spencer) 251
TARGETT (J. H.), cirrhosis of liver in a child . . . 136
„ dermoid cyst near knee 388
„ diffuse calcification of the liver 123
„ fœtal cretinism 385
„ internal rupture of liver 133
„ myxo-lipoma of the spermatic cord 282
„ sarcoma of œsophagus 76
„ also see *Eve* (*Frederick S.*).
TAYLOR (H. H.), disease of suprarenals (? nature) . . . 299
„ mitral stenosis. Enlarged auricle compressing left bronchus . 58
TENO-SYNOVITIS, tubercular (C. H. Golding-Bird) . . . 244
TESTICLE, sarcoma of the (J. Hutchinson) 193
TESTIS, cyst of undescended, of an imperfectly developed male sheep (F. S. Eve) 463
„ large fatty tumour in the scrotum, surrounding the (J. Hutchinson) . 191
THIGH, tumour removed from Scarpa's triangle . . . 286
THORACIC AORTA, aneurysm of (John R. Lucas) . . . 66
THROMBOSIS of aorta (G. Newton Pitt) 74
„ of veins of neck (J. A. Ormerod) 75
THYROID and cricoid cartilages, fracture of (H. Montague Murray) . 36

Digitized by Google

PAGE

TIBIÆ, syphilitic osteitis of (G. N. Pitt) 270
TOADS, supernumerary limbs in frogs and (J. B. Sutton) . . 461
TONGUE, congenital cyst of the (H. A. Lediard) . . . 281
„ epithelioma of (C. Heath) 283
TRACHEA and larger bronchi, syphilitic ulceration of (G. Gulliver) . 39
„ caseous bronchial gland perforating and obstructing the (G. Gulliver) . 38
TRACHEAL WOUND, diphtheritic membrane expelled from a (F. E. Nichol) 37
TREES, specimens illustrating the neoplastic process in (W. R. Williams) . 446
TUBERCLE of the ovaries (W. S. A. Griffith) 212
„ of the ovary (W. S. A. Griffith) 219
TUBERCULAR DISEASE of ovary (W. Edmunds) . . . 210
„ excavation of liver (F. Wethered) 139
„ symmetrical, disease of the suprarenal capsules (V. Harris) . . 300
„ teno-synovitis (C. H. Golding-Bird) 244
„ tumours in the brain of a child (N. Dalton) . . . 20
TUBERCULOSIS, camel with (W. K. Sibley) . . . 460
„ meningeal (H. Sainsbury) 9
„ microscopic specimens of (F. J. Wethered) . . . 399
TUMOUR, fatty, in wall of stomach (H. Montague Murray) . . 78
„ granuloma of skin (? lupus) (R. G. Hebb) . . . 298
„ large fatty, in the scrotum (J. Hutchinson) . . . 191
TUMOURS, large ovarian, in a seven months' child (A. Doran) . . 200
„ morbid growths and 275–298
„ multiple symmetrical, of bone from a dog (W. G. Spencer) . . 457
„ (tubercular) in the brain of a child (N. Dalton) . . . 20
TUNICA VAGINALIS, chylous fluid removed from (S. Jones) . . 183
TURNER (G. R.), parts after Allingham's inguinal colotomy . . 114

"**ULCER**, crateriform, of the face" (Jonathan Hutchinson, F.R.S.) . 275
„ of the stomach, close to the pylorus (Frank Penrose) . . 78
„ perforating, of foot (A. M. Sheild) 390
ULCERATION of the cæcum, followed by almost complete occlusion of the ileo-cæcal valve (F. W. Mott) . . . 106, 107
ULCERS, simple, of œsophagus (H. W. G. Mackenzie) . . 76
URETER, absence of upper two thirds of left, with very small cystic kidney (F. Penrose) 161
„ calculus in, disorganisation of kidney (F. D. Drewitt) . . 172
URETERS, psorospermial cysts of both (F. S. Eve) . . . 444
URETHRA, epithelioma of the male (J. Griffiths) . . . 177
„ stricture of (F. Penrose) 174

VARICOCELE, a spontaneous variation in the spermatic veins (W. G. Spencer) 185
VEIN, sarcoma of forearm, growing into a large (F. S. Eve and J. H. Targett) 297
VEINS of neck, thrombosis of (J. A. Ormerod) . . . 75
„ spermatic, varicocele, a spontaneous variation in the (W. G. Spencer) . 185
VERMIFORM APPENDICES, anomalous (F. W. Mott) . . 105
„ appendix, measuring 7 inches (F. W. Mott) . . . 106
VERTEBRÆ, cervical (L. A. Dunn) 264
VESICULATION of the mucous membrane of the bladder (Q. Silcock) . 175
VOLVULUS of sigmoid flexure, perforated cæcum from a case of (F. W. Mott) 106

Digitized by Google

PAGE

WASHBOURN (J. W.), a case of leprosy 307
WEBER (HERMANN), hydatid cyst on the left cerebral hemisphere . 17
WETHERED (F.), tubercular excavation of liver . . . 139
WETHERED (F. J.), microscopic specimens of tuberculosis . . 399
WHITE (W. H.), unusual form of rupture of the heart . . . 58
WILDE (LEONARD), dermoid cyst of lumbo-sacral region . . 386
WILLIAMS (W. ROGER), specimens illustrating the neoplastic process in trees 446

PRINTED BY ADLARD AND SON, BARTHOLOMEW CLOSE.

Digitized by Google

Digitized by Google

Digitized by Google

UNIVERSITY OF MICHIGAN
3 9015 03966 7038

Digitized by Google